

Dedifferentiated liposarcoma of the hypolarynx

Krishna Kumar, BA; Sarah Kurian, MD; and Brian Chin, MD

CASE SUMMARY

A 41-year-old male with 20-pack-year smoking history presented to the ED with 3 weeks of worsening shortness of breath, dysphagia, and coughing, and sudden onset of throat pain after eating and vomiting. On examination, he appeared in distress, with a muffled/hoarse voice and posterior pharyngeal erythema. Initially his symptoms were attributed to a food bolus, but he was unable to tolerate water or his secretions.

Otolaryngology was consulted, and the patient was given dexamethasone and racemic epinephrine. A contrast-enhanced CT of the soft tissue of the neck revealed a well-defined, oblong soft tissue $1.7 \times 2.7 \times 3.9$ cm mass arising from the right aryepiglottic region and narrowing the hypopharynx, (Figures 1-3). The patient underwent an awake tracheostomy placement and direct laryngoscopy with biopsy. Initial pathology was low-grade sarcoma or myxosarcoma. Immunohistochemical (IHC) stains on paraffin sections were reactive to vimentin, focally reactive to desmin, but negative for S100, indicating the

mass was mesenchymal and connective tissue in origin, most consistent with a sarcoma.

Given the rarity of sarcoma in this location, the patient underwent excisional biopsy of the mass.

IMAGING FINDINGS

Axial CT image (Figure 1) shows a low-attenuation soft tissue mass posterior to the epiglottis that significantly narrows the airway. Sagittal CT (Figure 2) image shows a low-attenuation mass anterior to the cervical vertebrae, causing significant narrowing of the airway. Figure 3 shows a high power (400x) view showing lipoblasts, pleomorphic lipoblasts, and mature adipocytes.

DIAGNOSIS

Dedifferentiated liposarcoma arising in the background of well-differentiated liposarcoma, with MDM2 gene amplification detected on fluorescent in-situ hybridization (FISH) testing.

DISCUSSION

Liposarcoma is a malignant neoplasm of fat cells, most commonly

occurring in male adults 40-60 years of age. Even though most commonly found in the retroperitoneum,¹ up to 6% of liposarcomas occur in the head/neck region.² The most common head and neck sites are the cheek, anterior neck, larynx, posterior cervical region and pyriform sinus³. While lipomas primarily are found in the subcutaneous fat, liposarcomas usually arise in the deep soft tissues and involve intermuscular fascial planes.⁴ The incidence of liposarcoma in the hypopharynx is not well-reported in the literature, with less than 40 cases reported, almost all of which are well-differentiated liposarcoma.^{5,6}

As described above, liposarcomas are classified into intermediate graded tumors (well-differentiated) and malignant graded tumors (dedifferentiated, myxoid, pleomorphic, and not otherwise specified).⁷ About 90 percent of dedifferentiated liposarcomas arise *de novo* and 10 percent occur as recurrence of a prior well-differentiated liposarcoma.⁸

Liposarcoma subtype is based on histologic and genetic findings, although computed tomography (CT)

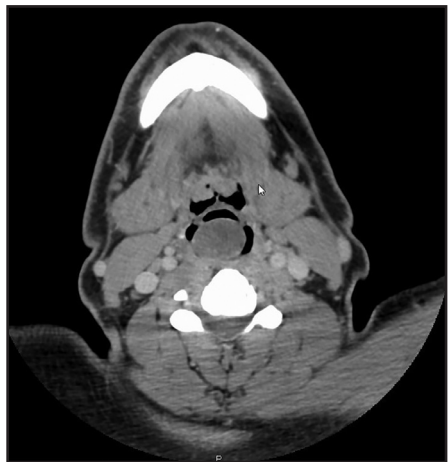


FIGURE 1. Axial CT image shows a low-attenuation soft-tissue mass posterior to the epiglottis that significantly narrows the airway.

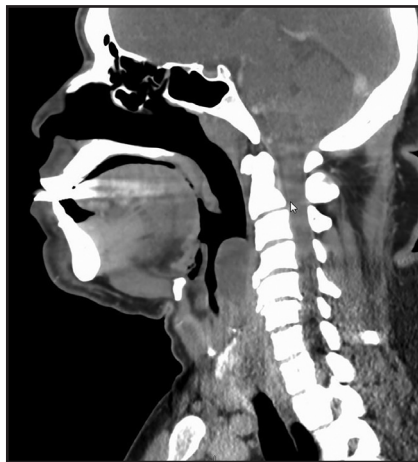

FIGURE 2. Sagittal CT image shows a low-attenuation mass anterior to the cervical vertebrae, causing significant narrowing of the airway.

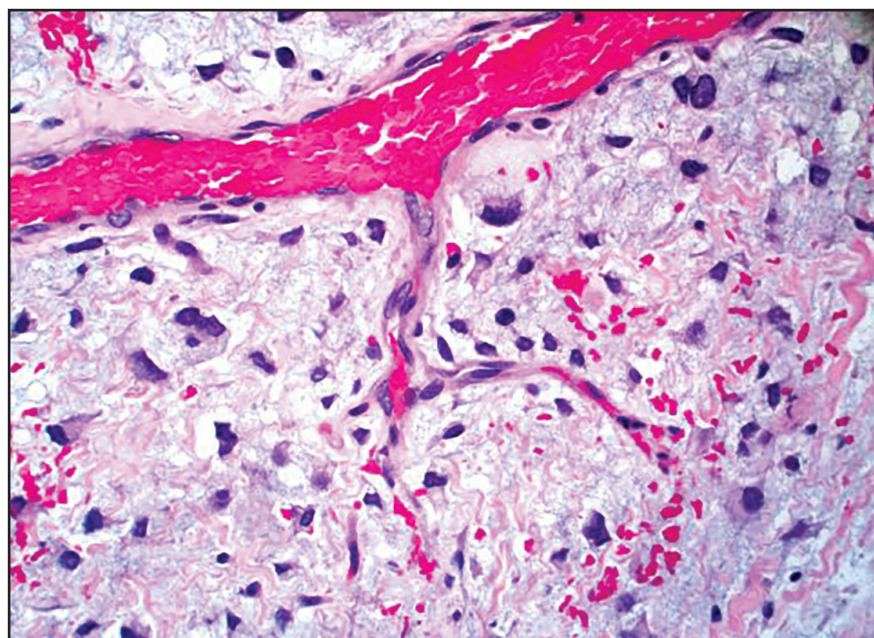


FIGURE 3. A high-power (400x) view showing lipoblasts, pleomorphic lipoblasts, and mature adipocytes.

and magnetic resonance imaging (MRI) are important for characterizing and determining tumor extent. The size of the tumor is important to note, as masses greater than 5 centimeters upstage the tumor. Certain CT/MRI features may support a specific grade and/or subtype.

Well-differentiated liposarcomas are often circumscribed and lobulated; dedifferentiated liposarcomas, infiltrating and amorphous. A dedifferentiated liposarcoma has signal characteristics similar to muscle and enhances avidly.^{9,10} On MRI, the presence of juxtaposed focal mass-like

nonlipomatous tissue with prolonged T1 and T2 relaxation times and a tissue attenuation similar to skeletal muscle on CT supports a dedifferentiated liposarcoma. Often in a well-differentiated liposarcoma, the nonlipomatous tissue appeared as thickened irregular septa, rather than a focal masslike area.¹⁰

Myxoid liposarcomas have an inhomogeneous appearance on CT and MRI, especially under contrast, and may even appear cystic on MRI. Myxoid and pleomorphic liposarcomas have a moderate to very inhomogeneous appearance on CT and MRI, containing areas of necrosis, and enhancement is irregular. Fat is difficult to detect in these tumors, as it often accounts for <25% of the volume.²

Surgical excision is the mainstay in treatment of liposarcoma, with the objective of wide resection with negative margins. In a study done by McCulloch et al,¹¹ there was an 80% recurrence after incomplete surgical resection of head and neck liposarcomas, but around 20% after complete surgical resection. However, given the amount of vital neurovascular structures located in this area, complete resection can often be difficult. Induction chemotherapy is often used in these areas in order to shrink the lesion prior to resection. Additionally, adjuvant intensity-modulated conformal radiotherapy (IMRT) or systemic therapy is increasingly used in areas where wide resection of the tumor margins cannot be performed. A study done by Eeles et al observed that adjuvant therapy decreased the rate of local recurrence of head and neck sarcomas.¹² Palbociclib, a potent CDK4/CDK6 inhibitor, has shown activity in well-differentiated and dedifferentiated liposarcoma by targeting these regulatory enzymes to halt disease progression. Another targeted therapy in dedifferentiated liposarcoma subtype

is the significant presence of the MDM2 gene. MDM2 is a negative regulator of the p53 tumor suppressor gene and was found to be implicated in liposarcomas, as in this case report. RG7112 is an MDM2 antagonist that may be a future treatment option, but the drug is undergoing further study.¹³

Prognosis depends on many factors, including grade, subtype and extent at presentation. Well-differentiated and myxoid tumors rarely develop distant metastases, and five-year survival rates for these tumors are 83-100%.⁸ Dedifferentiated and pleomorphic tumors are considered more malignant with greater potential for metastases. In a study done by Tirumani et al the lung was the most common site of metastases of dedifferentiated liposarcoma, with high tumor grade and local recurrence the greatest predictors of metastasis.¹⁴ Dedifferentiated tumors have a five-year survival rate around 20 percent, and pleomorphic tumors around 56 percent.⁸ Studies by Golledge et al and Gerry et al found that the overall prognosis for head and neck liposarcomas are better than other locations, especially when compared to the retroperitoneum. They reported a five-year survival rate at 67 percent for head and neck liposarcomas¹⁵ and a higher disease-specific survival and overall survival rate.¹⁶

CONCLUSION

As evidenced by the literature and our case, when presented with a soft-tissue mass in the head/neck, it

is important to consider liposarcoma, although it is rare. Imaging with MRI and/or CT is important in localizing the mass and determining its size and potential involvement of adjacent neurovascular structures prior to resection. Subtle findings in these modalities can even help to differentiate between subtypes of liposarcoma; however, pathology is required for a final diagnosis. Surgery continues to be a mainstay of treatment. Newer adjuvant therapies are being investigated, which is important, as complete resection of cancer in this area can be difficult when trying to preserve satisfactory postoperative function.

REFERENCES

1. Gaillard F, and Di Muzio B. "Liposarcoma I Radiology Reference Article." *Radiopaedia.org*. Radiopaedia, 2017. 10 Mar. 2017.
2. Munk, PL, Lee MJ, Janzen DL, et al. "Lipoma and Liposarcoma: Evaluation Using CT and MR Imaging." *American Journal of Roentgenology* 169.2 1997; 589-594.
3. Yueh B, Bassewitz HL, and Eisele DW. "Retropharyngeal Liposarcoma." *American Journal of Otolaryngology*. 1995; 16(5): 331-340.
4. Nouri H, Hassani R, Aderdour L, and Raji A. "The Well-differentiated Liposarcoma of the Hypopharynx." *European Annals of Otorhinolaryngology, Head and Neck Diseases*. 2011;128(3): 143-145.
5. Zhu H, Sun J, Wei S, et al. "Well-Differentiated Laryngeal/Hypopharyngeal Liposarcoma in the MDM2 Era Report of Three Cases and Literature Review." *Head and Neck Pathology* (2016): n. pag. *SpringerLink*.
6. Riva G, Sensini M, Corvino, Garzaro AM, and Pecorari G. "Liposarcoma of Hypopharynx and Esophagus: A Unique Entity?" *Journal of Gastrointestinal Cancer* 47.2 (2016): 135-42.
7. Doyle, Leona A. "Sarcoma Classification: An Update Based on the 2013 World Health Organization Classification of Tumors of Soft Tissue and Bone." *Cancer* 120.12 (2014): 1763-774.
8. Kikuchi, N., T. Nakashima, J. Fukushima, K. Nariyama, and S. Komune. "Well-differentiated Liposarcoma Arising in the Parapharyngeal Space: A Case Report and Review of the Literature." *The Journal of Laryngology & Otology* 129. S2, S86-S90.3 (2015).
9. Vella, O., A. Bequignon, F. Comoz, and E. Babin. "Retropharyngeal Liposarcoma: A Rare Cause of Dysphagia." *European Annals of Otorhinolaryngology, Head and Neck Diseases* 133.6 (2016): 429-430.
10. Kransdorf, M. J., J. M. Meis, and J. S. Jelinek. "Dedifferentiated Liposarcoma of the Extremities: Imaging Findings in Four Patients." *American Journal of Roentgenology* 161.1 (1993): 127-130.
11. McCulloch, T. M., K. H. Makielski, and M. A. McNutt. "Head and Neck Liposarcoma: A Histopathologic Reevaluation of Reported Cases." *Archives of Otolaryngology - Head and Neck Surgery* 118.10 (1992): 1045-1049.
12. Eeles, R. A. et al. "Head and Neck Sarcomas: Prognostic Factors and Implications for Treatment." *British Journal of Cancer* 68.1 (1993): 201-207.
13. Nassif NA, Tseng W, Borges C et al. Recent advances in the management of liposarcoma. *F1000Research* 2016, 5(F1000 Faculty Rev):2907.
14. Tirumani, S.h., H. Tirumani, J.p. Jagannathan, A.b. Shinagare, J.I. Hornick, N.h. Ramaiya, and A.j. Wagner. "Metastasis in Dedifferentiated Liposarcoma: Predictors and Outcome in 148 Patients." *European Journal of Surgical Oncology (EJSO)* 41.7 (2015): 899-904.
15. Golledge, Jonathan, Cyril Fisher, and Peter H. Rhys-Evans. "Head and Neck Liposarcoma." *Cancer* 76.6 (1995): 1051-1058.
16. Gerry, Daniel, Nyssa F. Fox, Laura S. Spruill, and Eric J. Lentsch. "Liposarcoma of the Head and Neck: Analysis of 318 Cases with Comparison to Non-head and Neck Sites." *Head & Neck* 36.3 (2013): 393-400.

Prepared by Ms. Kumar, Dr. Kurian, and Dr. Chin while at the Department of Radiology, St. Luke's Hospital, University of Missouri-Kansas City School of Medicine, Kansas City, MO.