Utilization of Breast MRI for Extent of Disease in Newly Diagnosed Malignancy

Kathy M. Borovicka, M.D., Sara K. Boyd, D.O., Julia D. Cameron-Morrison, D.O., Julia J. Hobson, D.O.

Department of Radiology, Beaumont Hospital, Farmington Hills, MI

Breast cancer remains the second leading cause of cancer-related death in women, with an approximately 1 in 8 (12%) chance of developing invasive breast cancer in a woman's lifetime.[1] Over the past two decades, significant advances in MRI have increased sensitivity in detecting breast cancer. Since then, radiologists, surgeons and oncologists have been utilizing breast MRI for both screening and staging of breast cancer. Numerous studies have shown that breast MRI can identify additional foci of carcinoma within the breasts and that it determines more extensive disease compared to conventional imaging of mammography and ultrasound.[2] This article will review how radiologists can use breast MRI in detecting additional disease within the breast and surrounding tissues.

Limitations of Mammography and Ultrasound in Breast Cancer Detection

Breast carcinomas are detected via screening and diagnostic evaluations. The workup of abnormalities includes evaluation with diagnostic mammography and ultrasound (US). Tomosynthesis is used as a 3-dimensional (3D) digital mammogram that has been shown to increase detection of invasive carcinomas.[3] Tissue sampling for pathologic diagnosis is then performed depending on the modality in which the abnormality is best visualized, including ultrasound guidance, stereotactic biopsy, and tissue sampling with MRI. Ultrasound-guided biopsies are preferred given the ease of performing and scheduling these cases. The radiologist must then determine whether the pathology result is concordant or discordant with the imaging findings. If discordant, a recommendation for additional tissue sampling via biopsy or surgical excision is then given.

While most primary lesions are found with mammography and ultrasound, these modalities have limitations. The most significant limitation with mammography is increased density of the fibroglandular tissue within the breasts, which may obscure carcinoma.[4] Mammography has been shown to have decreased sensitivity for detecting masses in extremely dense breasts. Additionally, these women have an increased relative risk for breast cancer compared to the average woman, with approximately a 4- to 6-fold increased risk.[4,5] For this reason, legislation is now in place to notify women with heterogeneous and extremely dense breasts, and 32 states require patients to be notified regarding their breast density and the possibility of additional screening, including whole-breast ultrasound and breast MRI depending on individual risk.[6] Decreased sensitivity of mammography is also noted in women with breast implants.[7] Breast ultrasound has its own limitations. It is operator dependent, with handheld scanning ultrasound most widely used. Ultrasound is also limited in evaluating or identifying calcifications.[8]

Current Role of Breast MRI

Breast MRI aids with the limitations of mammography and US, and has been shown to have the highest sensitivity of the 3 modalities, helping to detect cancers that are clinically, mammographically and sonographically occult.[2,9,10] Indications for screening breast MRI include high-risk patients such as women with a lifetime risk > 20%, women with a BRCA mutation or a first degree relative of a BRCA carrier, history of chest radiation, and women with hereditary syndromes such as Li-Fraumeni.[10] Breast MRI is used to determine the extent of invasive carcinomas and carcinoma in situ prior to treatment; assess response to neoadjuvant chemotherapy, metastatic carcinoma where the primary is unknown and suspected to be of breast origin; and problem solving for clinical or imaging findings. Breast MRI has also been used for assessment following surgery, as in cases with positive margins post lumpectomy; assessment for recurrence; and in cases with postoperative tissue reconstruction in which recurrence within tissue transfer flaps is suspected.[10]

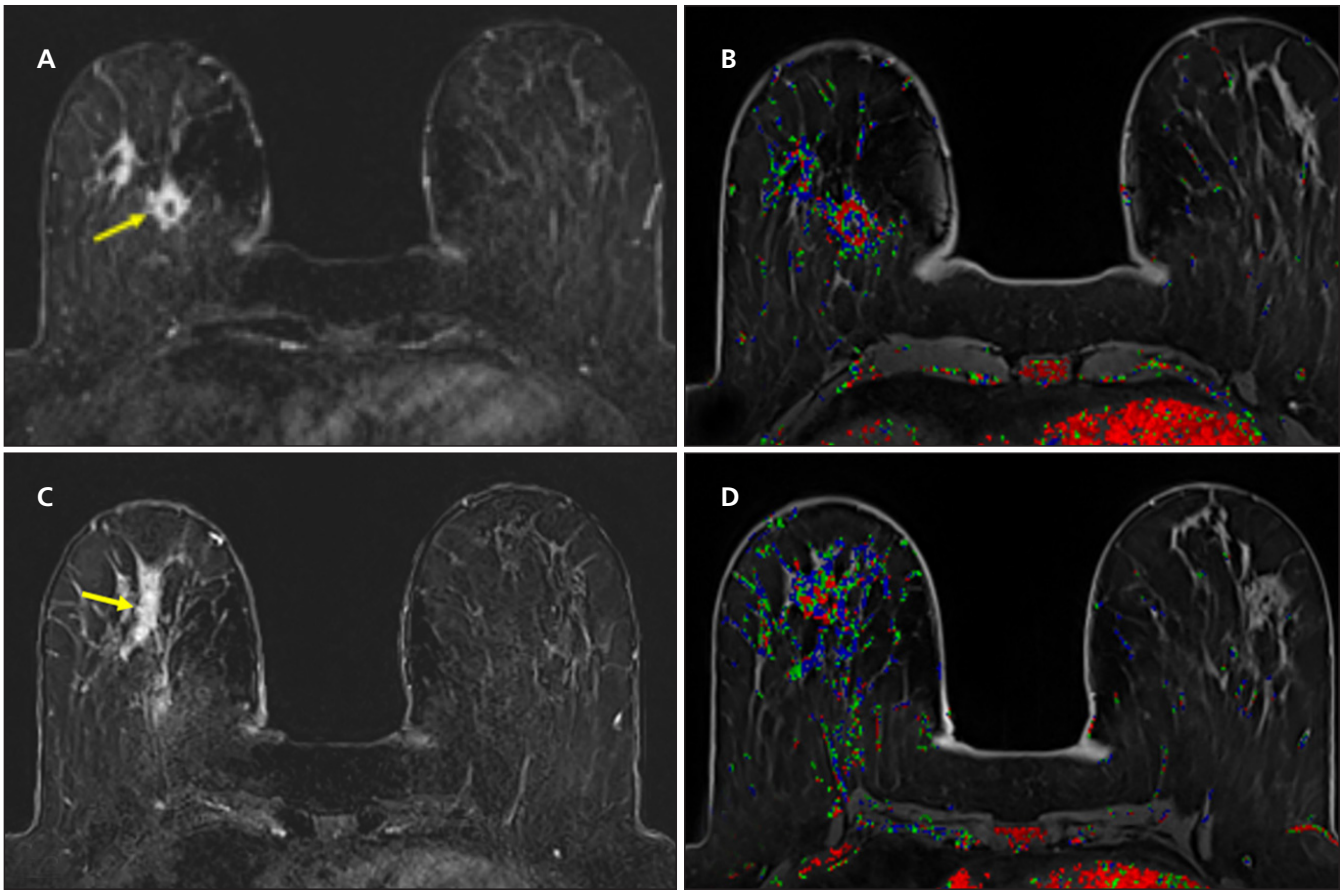

FIGURE 1. *Additional disease on MRI. Axial-subtracted (A) and color-overlay (B) images show a 1.8-cm spiculated mass at the 6 o'clock position in the middle depth of the right breast (arrow) with a central biopsy marker (biopsy confirmed invasive ductal carcinoma). Mixed kinetics are demonstrated on the color overlay image. Axial-subtracted (C) and color-overlay (D) images at an adjacent level reveal nonmass-clumped enhancement anterior to the primary mass. Mixed kinetics are also demonstrated in this region on the color overlay image. The patient underwent a right mastectomy, and pathology confirmed invasive ductal carcinoma with diffuse dermal lymphatic carcinomatosis.*

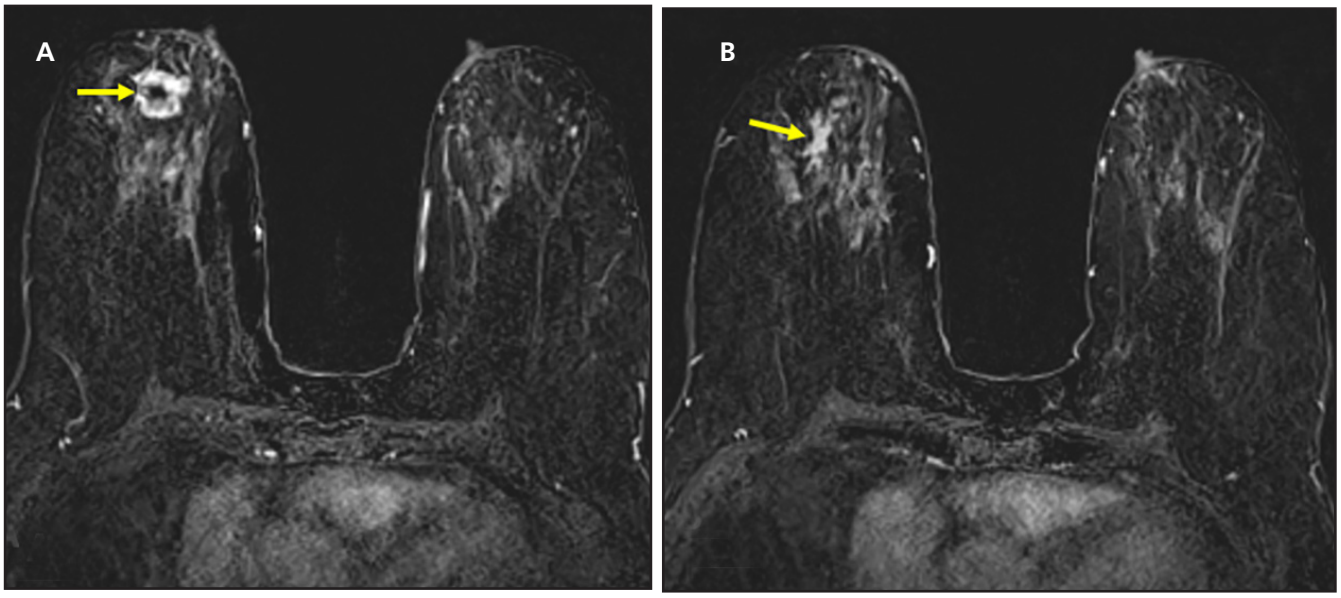

FIGURE 2. *Additional disease on MRI. Axial-subtracted image (A) shows a right 1.7-cm retroareolar mass (arrow) with a biopsy marker (biopsy confirmed invasive mucinous carcinoma). Axial-subtracted image inferior to the known mass (B) shows an additional right-sided 2.3-cm mass with irregular margins (arrow), which was confirmed to represent a second site of carcinoma.*

FIGURE 3. *Additional disease on MRI. Axial-subtracted (A) and color-overlay (B) images demonstrate a dominant mass (arrow) with mixed kinetics within the posterolateral right breast, which was proven to be invasive ductal carcinoma on biopsy. Axial-subtracted image C and color-overlay (D) images reveal additional masses in the same quadrant (arrows, C) with multifocal disease.*

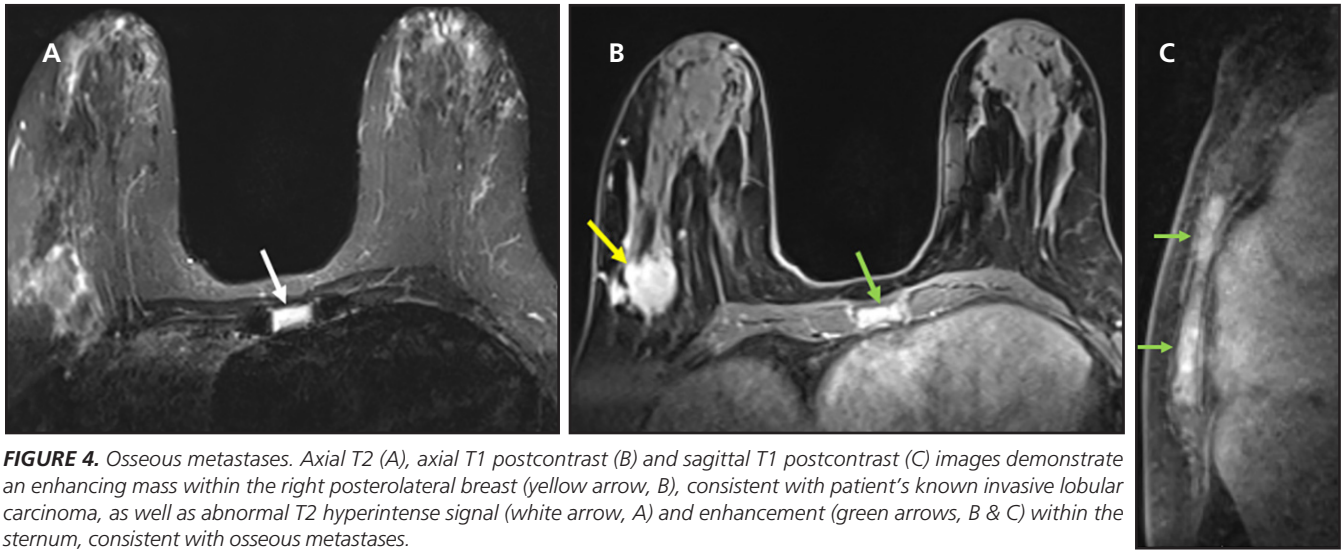

FIGURE 4. *Osseous metastases. Axial T2 (A), axial T1 postcontrast (B) and sagittal T1 postcontrast (C) images demonstrate an enhancing mass within the right posterolateral breast (yellow arrow, B), consistent with patient's known invasive lobular carcinoma, as well as abnormal T2 hyperintense signal (white arrow, A) and enhancement (green arrows, B & C) within the sternum, consistent with osseous metastases.*

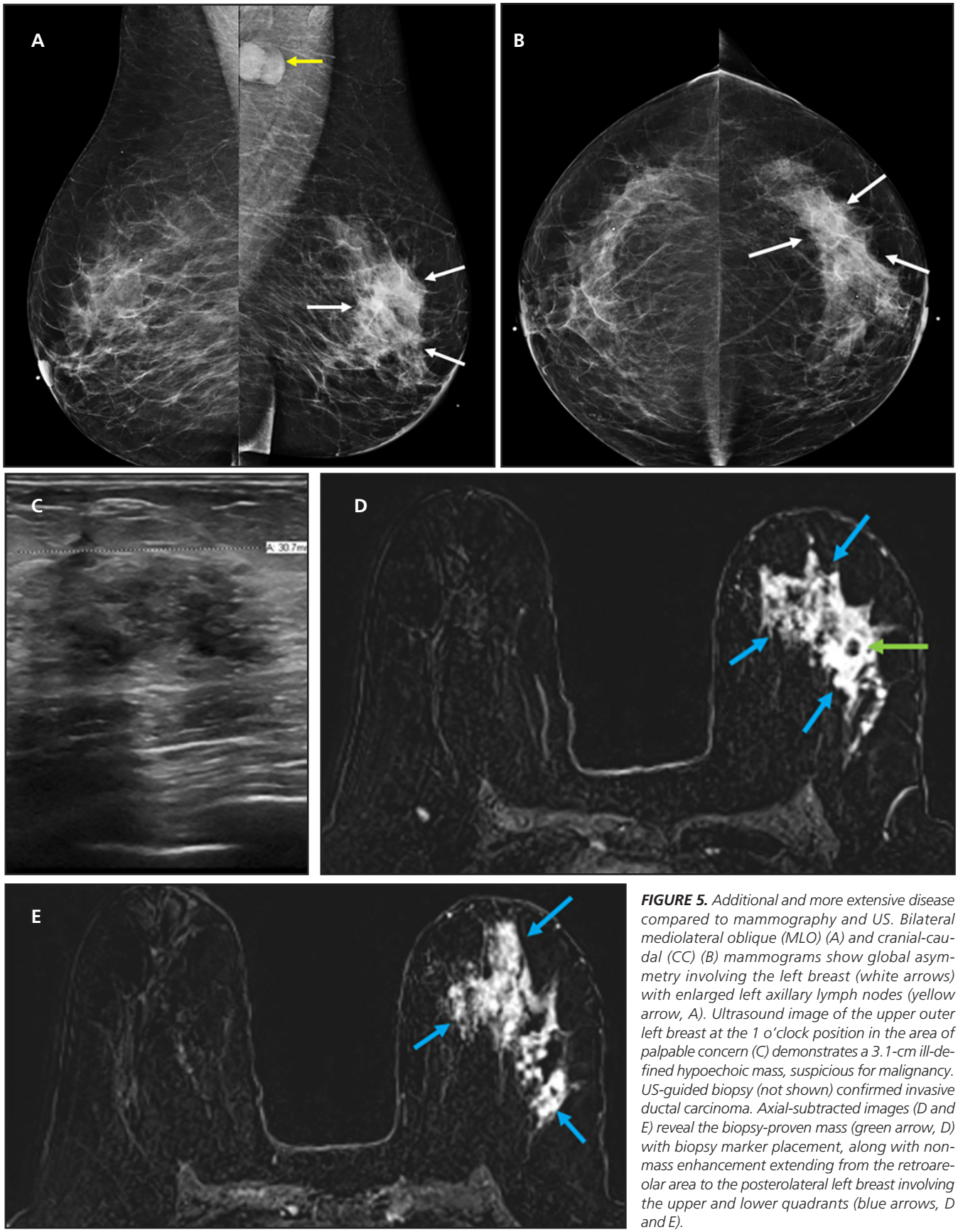

FIGURE 5. *Additional and more extensive disease compared to mammography and US. Bilateral mediolateral oblique (MLO) (A) and cranial-caudal (CC) (B) mammograms show global asymmetry involving the left breast (white arrows) with enlarged left axillary lymph nodes (yellow arrow, A). Ultrasound image of the upper outer left breast at the 1 o'clock position in the area of palpable concern (C) demonstrates a 3.1-cm ill-defined hypoechoic mass, suspicious for malignancy. US-guided biopsy (not shown) confirmed invasive ductal carcinoma. Axial-subtracted images (D and E) reveal the biopsy-proven mass (green arrow, D) with biopsy marker placement, along with non-mass enhancement extending from the retroareolar area to the posterolateral left breast involving the upper and lower quadrants (blue arrows, D and E).*

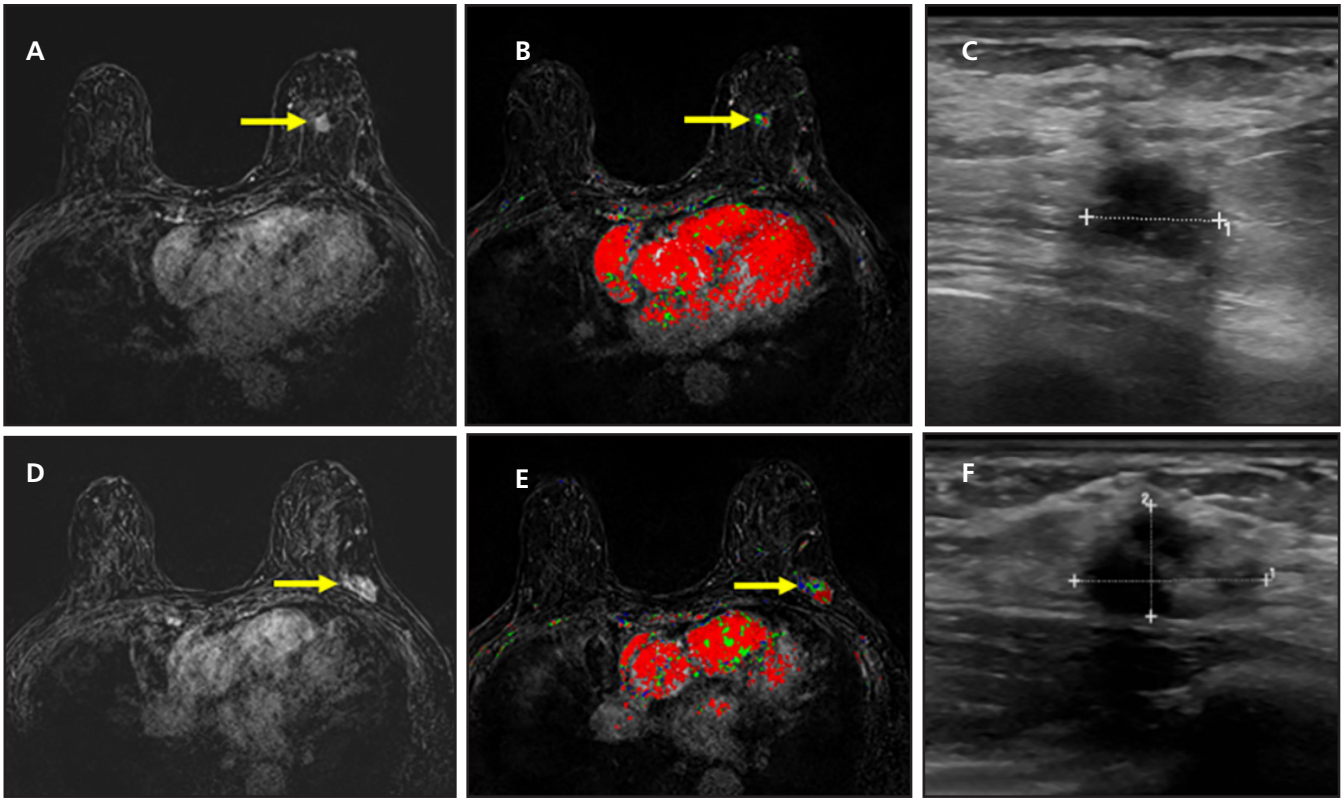

FIGURE 6. *Multicentric disease in the ipsilateral breast. Axial T1-subtracted (A) and color-overlay (B) images show an enhancing mass in the left retroareolar middle depth (arrows), which was confirmed to represent invasive ductal carcinoma and carcinoma in situ on biopsy. US image through this region (C) shows the mass with relatively circumscribed borders. Axial T1-subtracted (D) and color overlay (E) images through the upper breast demonstrate a second enhancing mass with mixed kinetics in the upper outer left breast (arrows), concerning for malignancy. Dedicated US through this region (F) shows the mass with angular margins. Biopsy confirmed invasive ductal carcinoma, consistent with multicentric disease.*

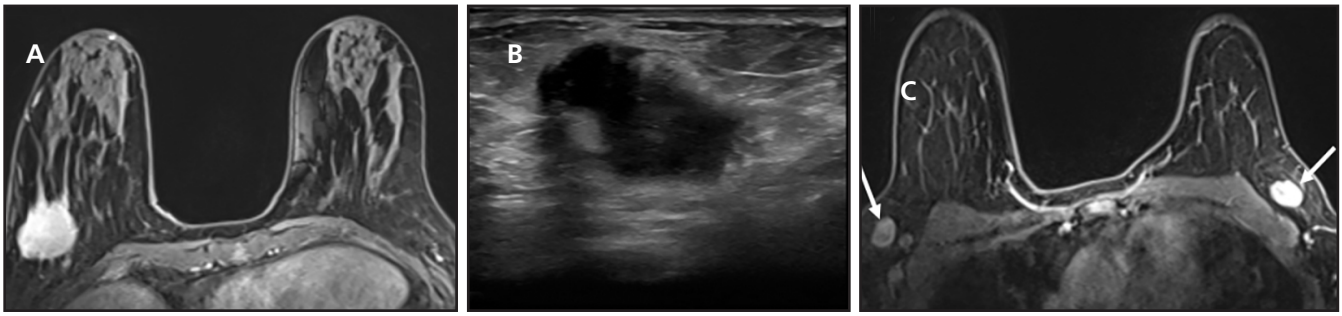

FIGURE 7. *Axillary lymph node involvement identified on MRI. Axial T1 postcontrast fat-suppressed image (A) demonstrates a large, spiculated 3.5-cm mass in the right upper outer breast that was palpable and confirmed on US (B). Additional axial T1 postcontrast fat-suppressed image (C) reveals bilateral axillary lymphadenopathy (arrows) with the largest measuring 1.3 cm in short axis. US-guided biopsies of the right breast mass and axillary lymph nodes confirmed invasive lobular carcinoma with metastatic bilateral axillary lymphadenopathy.*

BI-RADS for Breast MRI

The 2013 American College of Radiology (ACR) Breast Imaging Reporting and Data System (BI-RADS) 5 lexicon provides terminology that guides radiologists in the evaluation and description of breast MRI findings.[11] This includes description of the amount of fibroglandular tissue and background parenchymal enhancement. Abnormalities are further characterized into a focus, mass and nonmass enhancement. A focus is focal enhancement that is < 5 mm and considered to be a part of the parenchymal background enhancement. Masses are characterized by shape, margin and internal enhancement with an irregular shape and margin being most concerning. Nonmass enhancement is further characterized by distribution and internal enhancement. Linear and segmental distribution and clumped or clustered ring enhancement are most concerning.[11]

The morphology of a mass is more important than the enhancement kinetics. In terms of enhancement patterns, washout kinetics are of greatest concern, although many carcinomas are of mixed kinetics, including washout, persistent

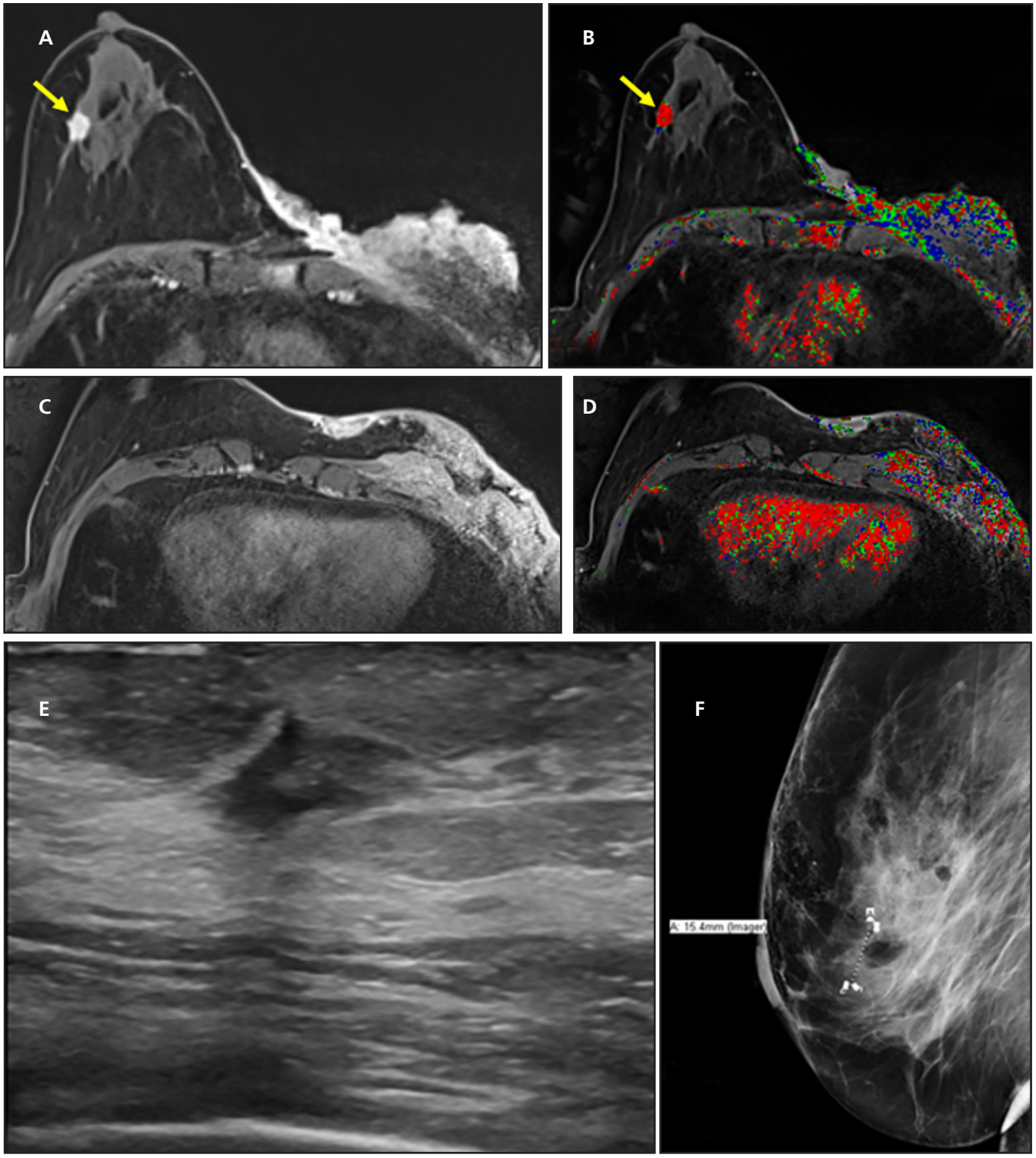

FIGURE 8. *Chest wall involvement and contralateral disease on MRI. Axial T1 postcontrast fat-suppressed (A and C) and corresponding color-overlay (B and D) images demonstrate a diffuse abnormal shrunken nodular appearance of the entire left breast, consistent with biopsy-proven invasive ductal carcinoma. There is diffuse posterior chest wall involvement and extension through the subcutaneous soft tissues and across midline to the medial margin of the right breast. The abnormal left breast and chest wall have mixed kinetics. Within the middle depth right breast there is a 1.5-cm oval mass at the 9 o'clock position with washout kinetics (arrows), suspicious for an additional site of malignancy in the right breast. Focused ultrasound image of the right breast (E) revealed a mass with angular margins that was felt to correspond with the mass on MRI. Initial and repeat US-guided biopsy demonstrated fibrosis, which was considered discordant. An MRI-guided biopsy was then performed, demonstrating low-grade invasive scirrhous ductal carcinoma with focal low-grade ductal carcinoma in situ. Postbiopsy mammogram (F) showed the rod-shaped MRI biopsy marker to be 1.5 cm from the coil-shaped US-guided biopsy markers.*

and plateau. If additional suspicious masses and enhancement patterns are detected that would impact surgical and oncologic management, then a BI-RADS of 4 or 5 is given to obtain a tissue diagnosis.[11]

Breast MRI for Extent of Disease

Preoperative breast MRI is increasingly used in staging newly diagnosed breast cancers. It is primarily utilized to look for evidence of more extensive disease than is noted on conventional imaging with diagnostic mammography and ultrasound. This includes additional disease in the ipsilateral or contralateral breast (**Figures 1-3**).

Location of the cancer in the breast is described in terms of breast quadrant (inner upper, inner lower, outer upper, and outer inner), depth (anterior, middle and posterior), and the o'clock position. Size of the mass or nonmass enhancement is described in all 3 dimensions: anteroposterior, transverse and craniocaudal dimensions. These descriptors are important for localization in terms of surgery and radiation, as well as when comparing the sizes and locations to mammography and ultrasound. If additional suspicious findings are detected, multifocal disease (within the same quadrant) and multicentric disease (within at least 2 quadrants) is described.[12] More extensive disease also needs to be described: extension to the nipple and skin, lymphadenopathy (axillary, internal mammary and supraclavicular), involvement of the pectoralis musculature and chest wall, and osseous metastases (**Figure 4**).[11]

On conventional imaging, the area of tissue involved is underestimated by approximately 14% on mammography and 18% on US, and only identified as more extensive with MRI (**Figure 5**).[13] In the ipsilateral breast, additional suspicious lesions have been seen in approximately 29% of individuals with confirmed malignant lesions in 16% of cases (**Figure 6**).[2,13] In the contralateral breast, MRI detects additional suspicious lesions in up to 19%, with synchronous contralateral breast malignancy found in approximately 4% of cases.[2,13] This contralateral disease has been found to be ductal carcinoma in situ (DCIS) in 35% of cases.[14,15] Biopsy is required to prove additional disease to be a malignancy since this impacts surgical management, including wider local excision or mastectomy depending on the extent of disease.[13,16]

Involvement of the regional lymph nodes in breast cancer has an impact on prognosis and can affect treatment planning. MRI is useful in detecting axillary, supraclavicular and internal mammary lymph node involvement (**Figure 7**). Abnormal lymph nodes include loss of the normal reniform shape, loss of the normal fatty hilum, hilar compression, or diffuse or focal thickening of the cortex > 3-4 mm.[12]

Extension of tumor to the chest wall (**Figure 8**), defined as invasion of the serratus anterior, ribs or intercostal muscles, upgrades tumor stage regardless of tumor size. Invasion of the pectoralis muscle is not considered chest wall invasion and does not change the staging. Pectoralis involvement is defined as enhancement of the pectoralis muscle, which will impact surgical excision. MRI is the imaging modality of choice in assessing pectoralis muscle and chest wall involvement. Distant metastasis is seen in approximately 4% of breast cancer cases. Osseous, liver and lung metastasis may be seen with the breast MRI.[17]

Conclusion

Breast MRI has been shown to be significantly more sensitive in evaluating the extent of disease in breast cancer patients when compared to mammography and US. This includes involvement of the unilateral and contralateral breast, as well as extramammary spread of disease. With a preoperative breast MRI, it is important for the radiologist to appropriately describe the extent of suspected disease in accordance with the BI-RADS lexicon, and make appropriate management and follow-up recommendations.

References

1. American Cancer Society. Breast Cancer Facts & Figures 2015-2016. Atlanta: American Cancer Society, Inc. http://www.cancer.org/cancer/breastcancer/detailedguide/breast-cancer-key-statistics. Accessed June 2, 2017.
2. Houssami N, Hayes DF. Review of preoperative magnetic resonance imaging (MRI) in breast cancer: should MRI be performed on all women with newly diagnosed, early stage breast cancer? CA Cancer J Clin 2009;59(5):290-302.
3. Sharpe RE, Venkataraman S, Phillips J, et al. Increased cancer detection rate and variations in the recall rate resulting from implementation of 3D digital breast tomosynthesis into a population-based screening program. Radiology 2016;278(3):698-706.
4. Freer PE. Mammographic breast density: impact on breast cancer risk and implications for screening. Radiographics 2015;35(2):302-315.
5. Harvey JA, Bovbjerg VE. Quantitative assessment of mammographic breast density: relationship with breast cancer risk. Radiology 2004;230(1):29-41.
6. Nebraska Becomes the 32nd Density Reporting State as Governor Ricketts signs Cheri's Law. http://areyoudenseadvocacy.org/worxcms_published/news_page224.shtml. Accessed May 31, 2017.
7. Wiedenhoefer JF, Shahid H, Dornbluth C. MR imaging of breast implants: useful information for the interpreting radiologist. Appl Radiol 2015:44(10):18-24.
8. Giger ML, Inciardi MF, Edwards A, et al. Automated breast ultrasound in breast cancer screening of women with dense breasts: reader study of mammography-negative and mammography-positive cancers. Am J Roentgenol 2016;206(6):1341-1350.
9. Sardanelli F, Giuseppetti GM, Panizza P, et al. Sensitivity of MRI versus mammography for detecting foci of multifocal, multicentric breast cancer in fatty and dense breasts using the whole-breast pathologic examination as a gold standard. Am J Roentgenol 2004;183(4):1149-1157.
10. ACR Practice Parameter for the Performance of Contrast-enhanced Magnetic Resonance Imaging (MRI) of the Breast. 2013. http://www.acr.org/~/media/2a0eb28eb59041e2825179afb72ef624. Accessed May 11, 2017.
11. Morris EA, Comstock CE, Lee CH, et al. ACR BI-RADS® Magnetic Resonance Imaging. In: ACR BI-RADS® Atlas, Breast Imaging Reporting and Data System. Reston, VA: American College of Radiology; 2013.
12. Lee SC, Jain PA, Jethwa SC, et al. Radiologist's role in breast cancer staging: providing key information for clinicians. Radiographics 2014;34(2):330-342.
13. Schell AM, Rosenkranz K, Lewis PJ. Role of breast MRI in the preoperative evaluation of patients with newly diagnosed breast cancer. Am J Roentgenol 2009;192(5):1438-1444.
14. Morrow M, Waters J, Morris E. MRI for breast cancer screening, diagnosis, and treatment. Lancet 2011;378(9805):1804-1811.
15. Brennan ME, Houssami N, Lord S, et al. Magnetic resonance imaging screening of the contralateral breast in women with newly diagnosed breast cancer: systematic review and meta-analysis of incremental cancer detection and impact on surgical management.
16. Boetes C, Mus RD, Holland R, et al. Breast tumors: comparative accuracy of MR imaging relative to mammography and US for demonstrating extent. Radiology 1995;197(3):743-747.
17. Patanaphan V, Salazar OM, Risco R. Breast cancer: metastatic patterns and their prognosis. South Med J 1988;81(9):1109-1112.