JAOCR at the Viewbox

Rashed Hasan, M.D., Steven D. Herman, M.D.

Department of Radiology, Hahnemann University Hospital, Drexel University College of Medicine, Philadelphia, PA

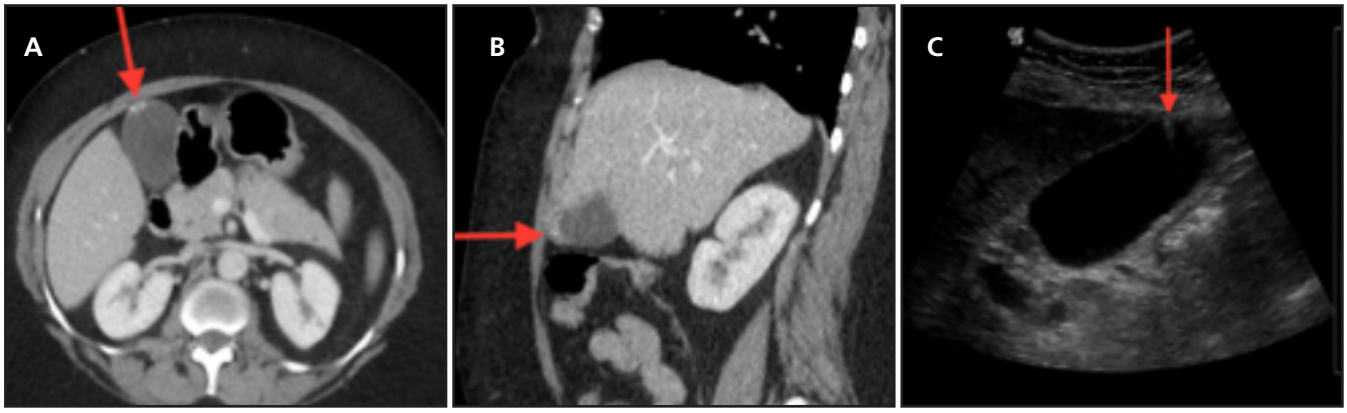

Gallbladder Adenomyomatosis

A 60-year-old woman underwent a CT of the abdomen for evaluation of the liver due to a history of hepatitis C. Incidentally noted were nondependent gallbladder wall calcifications with wall thickening, suspicious for adenomyomatosis (**Figures A and B**). An ultrasound was subsequently ordered for further evaluation, which demonstrated focal wall calcifications with "comet tail" artifact, clinching the diagnosis of adenomyomatosis (**Figure C**).

Adenomyomatosis is a common condition of unknown etiology, seen in approximately 9% of cholecystectomy specimens, which falls under the category of gallbladder cholecystosis. Importantly, adenomyomatosis is not considered a premalignant lesion. Most patients with adenomyomatosis are asymptomatic, but when symptomatic, patients may complain of right upper quadrant pain or dyspepsia. The differential diagnosis for these symptoms includes cholecystitis, hepatitis, hepatic steatosis, pancreatitis, and duodenal ulcer.

The hallmark feature of adenomyomatosis is focal or diffuse intramural hyperplasia and formation of intramural diverticula, known as Rokitansky-Aschoff sinuses, within the muscularis layer. These diverticula are lined by the epithelial layer of the mucosa and may trap bile, subsequently allowing crystals to precipitate. As one might expect, ultrasound findings include focal or diffuse wall thickening, intramural anechoic foci representing dilated sinuses, and echogenic intramural foci with comet tail artifact representing the precipitated crystals.[1] Computed tomography (CT) and MRI may demonstrate similar findings with the possible addition of hourglass gallbladder configuration when there is segmental adenomyomatosis and the "pearl necklace" sign, multiple adjacent T2 intense fluid collections representing the Rokitansky-Aschoff sinuses, specific to MR.[2] The differential diagnosis for these imaging findings include cholecystitis, gallbladder carcinoma, adenomatous polyps, and cholesterolosis.

References

1. Levy AD, Murakata LA, Abbott RM, et al. Benign tumors and tumorlike lesions of the gallbladder and extrahepatic bile ducts: radiologic-pathologic correlation. *RadioGraphics* 2002;22(2):387-413.
2. Mellnick, VM, Menias CO, Sandrasegaran K, et al. Polypoid lesions of the gallbladder: disease spectrum with pathologic correlation. *RadioGraphics* 2015; 35(2): 387-399.