Evaluation of Pelvic Floor Dysfunction with Dynamic MRI

Christopher G. Brown, M.D., Nancy S. Mohsen, M.D.

Department of Radiology, Hahnemann University Hospital, Drexel University College of Medicine, Philadelphia, PA

Pelvic floor dysfunction is a broad term that refers to disorders of pelvic organ prolapse, incontinence, or symptoms of obstructed defecation that more commonly affect women. Known risk factors include vaginal parity, neuropathy, obesity, advancing age, and prior pelvic surgery, although no single cause for pelvic floor dysfunction has been identified.[1, 2] Patients often present to medical professionals when quality of life is significantly impacted due to symptoms of pelvic pain, pelvic pressure, urinary or fecal incontinence, or difficulty with defecation. Physical examination often underestimates the degree of pelvic floor dysfunction because the position of internal pelvic organs cannot be accurately evaluated, and symptoms are most pronounced when straining or with defecation.[3]

Historically, pelvic floor dysfunction has been evaluated with dynamic fluoroscopic cystoproctography, in which the small bowel is opacified with ingested barium, the rectum is opacified with rectally administered barium paste, the bladder and vagina are opacified with contrast, and images are obtained at rest and during defecation (performed on a plastic toilet under fluoroscopy). With advances in MRI technology, dynamic MR defecography imaging (performed at rest and during defecation), is increasingly used to evaluate pelvic floor dysfunction. MRI allows for superior evaluation, without the use of ionizing radiation of reproductive organs, and of the sigmoid colon, peritoneum, and small bowel for prolapse. MRI evaluation of the rectum, bladder, and urethra for prolapse is equivalent if not superior to fluoroscopy. Dynamic MRI defecography, is also less invasive than its fluoroscopic counterpart, as it usually only requires administration of a rectal contrast agent. It can also evaluate the pelvic floor musculature for lateral hernias and can identify additional pelvic organ pathology (such as endometriosis, adhesions, unexpected uterine or adnexal masses, and complications of mesh repair) that may contribute to the patient's symptoms. MRI provides superior assessment of the contribution of uterine cervical prolapse to patient symptoms because these structures are directly imaged, in contrast to conventional cystoproctography where they are not visible. A theoretical weakness of MRI defecography is supine positioning of the patient, which may result in underestimation of dysfunction. This, however, is controversial and has not been our experience when patients are coached appropriately. The additional information yielded by MRI is invaluable to the surgeon for providing the optimal treatment plan for the patient, whether it is surgical or a conservative approach.

MRI Technique

The guiding principle behind dynamic MRI for evaluating pelvic floor dysfunction is imaging the pelvic organs both at rest and with maximal strain during defecation. In an open-magnet MRI, this can be performed in the sitting position which replicates the natural physiologic position for defecation and the effects of gravity on the pelvic organs. However, most imaging centers have a closed-magnet MRI, which requires imaging in the supine position. The patient's knees can be bent (propped on a wedge pillow) to increase patient comfort and more closely approximate the natural position for defecation. In terms of clinically significant pelvic floor dysfunction, there is little difference in results between imaging performed in the sitting vs. supine positions.[4] The examples shown here from our institution were all obtained in the supine position in a closed-magnet MRI.

Before the procedure, the patient must be counseled regarding examination requirements. Not surprisingly,

many patients are initially hesitant about the idea of defecating during the MRI examination. It is paramount to make the patient comfortable with the procedure, explaining the steps in advance, including rectal injection of ultrasound gel, placement of an adult diaper during the procedure, and that they will be asked to defecate several times throughout the study. We emphasize the importance of "recreating their problem" in the MRI scanner so that their physician will have the most complete information to make good treatment decisions. It also helps patients to know that this is a commonplace procedure for our staff and that the staff are not uncomfortable with it. The degree of pelvic floor dysfunction will almost certainly be underestimated if the patient cannot relax and fully cooperate.

Because the procedure requires imaging during maximal strain with defecation, the rectum must be filled with a soft substance visible on MRI. Most institutions, including our own, use sonographic gel, which has intrinsic T2 hyperintensity and is relatively inexpensive, readily available, and easy to clean. Other materials include a starch paste or mashed potatoes mixed with gadolinium. At our institution, the patient wears an adult diaper, which reduces patient embarrassment. We place additional disposable padding underneath the patient to minimize the chance of additional mess or discomfort. After the patient has secured the diaper and is lying in the left lateral decubitus position on the MRI table, the diaper is opened and approximately 240 mL of sonographic gel is injected into the rectum through 4 prepared 60-mL syringes. The diaper is then re-secured and the patient is placed in the supine position on the MRI table. Foam padding and pillows are placed under the knees to support them in a bent position to mimic physiologic positioning as much as possible. The degree to which this can be accomplished depends on patient body habitus.

At our institution, the first sequences obtained include sagittal and axial half-Fourier-acquired single-shot turbo spin echo (HASTE) through the entire pelvis, axial gradient echo T2, and axial gradient echo T1 fat-suppressed (FS) through the entire pelvis at rest. This provides an anatomic survey and general survey for uterine or adnexal pathology in women. The gradient echo imaging improves identification of surgical material (such as mesh), which can be useful to the surgeon if planning a surgical revision. The gradient echo T1FS is particularly useful in premenopausal patients to evaluate for endometriosis implants, which may present atypically, and contribute to symptoms of pelvic floor dysfunction/obstructed defecation. Next, steady-state free precession (SSFP) cine images are acquired in the midline sagittal plane utilizing 1-cm thick slices (which will visualize the pubic symphysis, bladder, vagina, cervix, uterus, rectum, and coccyx) as the patient strains and evacuates the rectum. Multiple attempts are usually required before the patient is comfortable enough to give maximum effort, and this can be repeated many times if necessary. Cine images in additional planes can be acquired as needed, but for most applications sagittal imaging is sufficient.

Of note, some protocols at other institution also include filling the vagina with sonographic gel to aid its visualization, but in our experience, the resolution of MRI images obviates this need.

Normal Anatomy

The pelvic floor consists of fascia and muscles, which provide passive and active support, respectively, to the pelvic organs and serve important functions for continence and voiding. The endopelvic fascia is made up of peritoneal reflections and connects the uterus and vagina to the pelvic sidewalls.[4,5] Its anterior portion forms the pubocervical fascia, and its posterior portion forms the rectovaginal fascia.[5] The sacrouterine-cardinal ligament complex suspends the vaginal cuff and is anchored to the sacrum posteriorly.[6]

The primary muscle of the pelvic floor is the levator ani, which forms the muscular pelvic diaphragm. The levator ani is composed of 3 paired muscle groups: the ileococcygeus, pubococcygeus, and puborectalis. Both the ileococcygeus and the pubococcygeus are horizontally oriented and form the largest portion of the pelvic floor. The ileococcygeus arises from the ischial spines and posterior aspect of the tendonous arch of the obturator fascia and inserts on the coccyx, and the pubococcygeus arises from the pubic bone and inserts on the coccyx. The puborectalis arises from the pubic bone and forms a U-shaped sling around the rectum and is part of the external anal sphincter. The impression of the puborectalis on the rectum marks the level of the anorectal junction. When relaxed, the resting muscular tone of the levator ani supports the pelvic organs from intraabdominal pressure and the effects of gravity. When contracted, the levator ani compresses the urethra, vagina (in women), and the anorectal junction, which helps maintain urinary and fecal continence.

The urogenital diaphragm is located inferior to the levator ani muscles and is composed primarily of connective tissue and the deep transverse perineus muscle. Its shape forms an anterior triangle with the apex at the pubic symphysis and a posterior triangle with the apex at the coccyx. The urethra and vagina traverse the anterior triangle, and the rectum traverses the posterior triangle.

The pelvis is divided into 3 functional compartments by anatomists and surgeons: anterior, middle and posterior. The anterior compartment is composed of the bladder and urethra; the middle compartment is composed of the vagina, cervix, uterus, and adnexa; and the posterior compartment is composed of the anus and rectum.

Interpretation of MRI

To standardize the imaging evaluation of pelvic floor dysfunction with dynamic MRI, the HMO classification system was developed (referring to H line, M line, and organ prolapse), which defines specific measurements and references points to be evaluated at

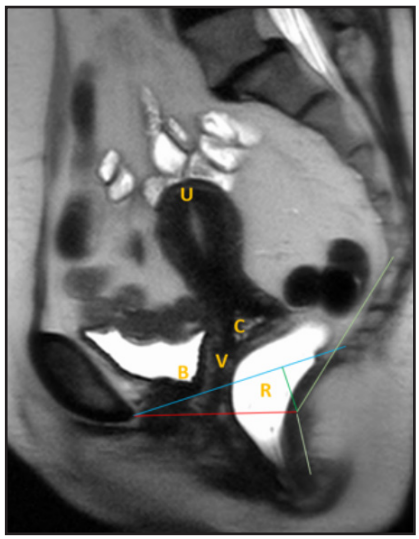

FIGURE 1. *Sagittal half-Fourier-acquired single-shot turbo spin echo (HASTE) of a 56-year-old woman with normal anatomy and no evidence of prolapse. Uterus (U), cervix (C), vagina (V), bladder (B), rectum (R), H line (red), PCL (blue), M line (green), and anorectal angle (light green).*

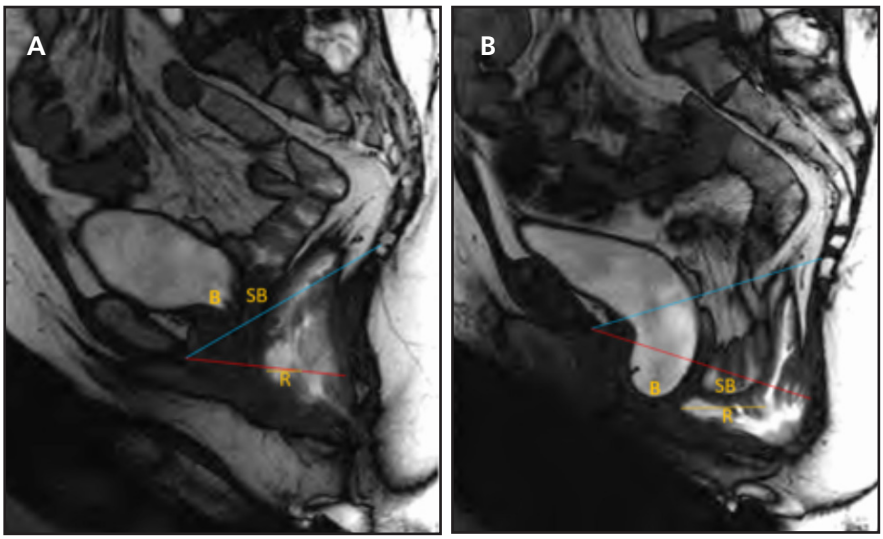

FIGURE 2. *Sagittal steady-state free precession (SSFP) images of a 61-year-old woman for evaluation of anal incontinence. Image A is at rest and B is with maximal strain. At rest, a small anterior rectocele is present but there is no pelvic organ prolapse. With maximal strain, there is moderate cystocele with the inferior bladder protruding 3 cm below the hiatus, moderate anterior rectocele, and moderate to large enterocele with small bowel loops protruding 3 cm below the H line. PCL (blue), H line (red), bladder (B), small bowel (SB), anterior rectocele (yellow line, R).*

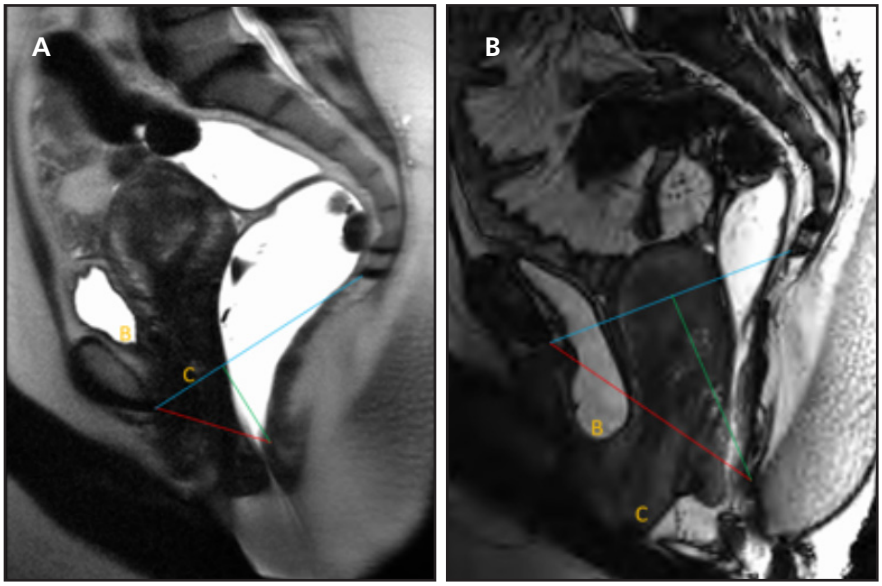

FIGURE 3. *Sagittal images of a 47-year-old with cervical prolapse, cystocele, and severe pelvic floor descent. Half-Fourier-acquired single-shot turbo spin echo (HASTE) images at rest (A) and steady-state free precession (SSFP) image with maximal strain (B). At rest, there is moderate pelvic floor descent, denoted by the M line, which measures 4 cm. With maximal strain, the cervix and bladder prolapses below the H line, and the pelvic floor descends to 8 cm, denoted by the M line. PCL (blue), H line (red), M line (green), cervix (C), bladder (B).*

rest (**Figure 1**) and with maximal strain during defecation.[7] All measurements are taken in the midsagittal plane.

The pubococcygeal line (PCL) is drawn from the inferior margin of the pubic symphysis to the most caudal coccygeal joint, which is a fixed line and serves as a reference point from which to measure descent of the pelvic floor musculature.

The hiatal line (H line) is drawn from the inferior margin of the pubic symphysis to the posterior anorectal junction (posterior superior margin of the puborectalis muscle sling), which measures the length of the puborectal hiatus and can be identified as a focal thickening along the posterior rectal wall. The length of the H line is used to assess pelvic floor relaxation, and level of the H line serves as a reference point from which to measure pelvic organ prolapse. Normally, the length of the H line increases with strain to allow for complete evacuation of the rectum. Likewise, the H line normally decreases when the levator muscles are contracted as the patient squeezes or tightens their pelvic floor musculature. In most individuals, the H line should not exceed 6 cm.[8]

The M line is drawn perpendicular from the posterior margin of the H line to the PCL and represents the descent of the pelvic floor musculature. In most patients, the M line should not exceed 2 cm.[8]

The anorectal angle (ARA) is defined as the angle between the anal canal and the distal rectum, which is measured at the level of the anorectal junction marked by the posterior impression of the puborectalis muscle sling on the posterior rectal wall. In most people, the ARA spans 108-127 degrees at rest.[9,10]

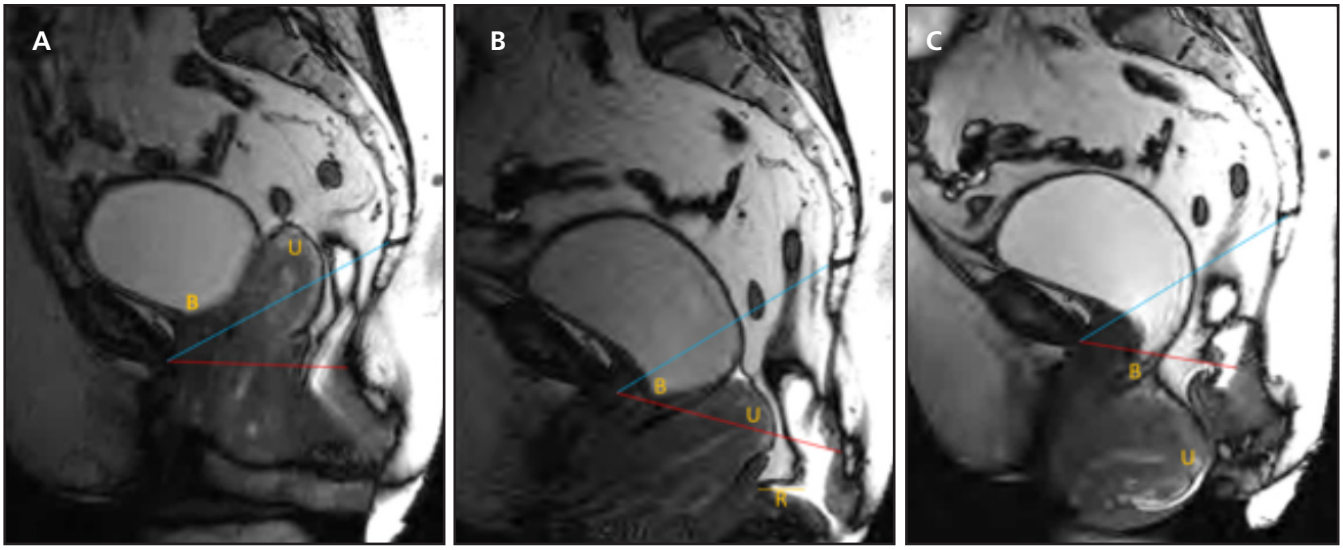

FIGURE 4. *Sagittal images of a 78-year-old woman with severe uterine prolapse. Steady-state free precession (SSFP) images at rest (A), with Valsalva (B), and with maximal strain (C). At rest, the caudal aspect of the uterus is at the level of the H line in the neutral position. With Valsalva, the uterus begins to prolapse below the H line, and an anterior rectocele (yellow line, R) is present. With maximal strain, the uterus completely prolapses below the H line. A mild cystocele is also present, with the inferior bladder protruding 2.6 cm below the H line. PCL (blue), H line (red), uterus (U), bladder (B).*

With squeezing, the puborectalis contracts and pulls the anorectal junction toward the pubic bone, making the angle more acute. With maximal strain and defecation, the puborectalis relaxes and the angle becomes more obtuse increasing by 15-20 degrees, allowing for complete evacuation of the rectum.[9,11]

Pathology

Pelvic floor relaxation and pelvic organ prolapse are 2 related subcategories of pelvic floor dysfunction that should be assessed separately. Pelvic floor relaxation describes hiatal enlargement, indicating pelvic floor muscle laxity or weakness. Pelvic floor descent is often associated with pelvic floor relaxation and is indicated by an increase in the M line. Pelvic organ prolapse is defined as protrusion of pelvic organs through the puborectalis hiatus. Grading of pelvic organ prolapse is determined by the distance from the most caudal aspect of the organ from the H line, measured at rest and during defecation, and is defined as mild (< 2 cm), moderate (2-4 cm), and severe (> 4 cm).[6] Although abnormalities in pelvic floor relaxation and pelvic organ prolapse often occur together in various combinations, they are separate entities and each has implications on surgical repair.

Pelvic Floor Relaxation

Pelvic floor relaxation can be described by abnormal hiatal enlargement and pelvic floor descent during maximal strain, which are measured with the H and M lines, respectively. In normal individuals, the H line should be < 6 cm, and the M line should be < 2 cm.[8] Pelvic floor relaxation occurs as the fascial and muscular supports of the pelvic floor weaken over time. As the pelvic floor relaxation increases, the pelvic organs it supports also are more likely to descend, indicating weakening of their supportive fascia and ligaments. Grading of hiatal enlargement is described as mild (6-8 cm), moderate (8-10 cm), and severe (> 10 cm), and grading of pelvic floor descent is described as mild (2-4 cm), moderate (4-6 cm), and severe (> 6 cm).[6]

Cystocele, Urethrocele

A cystocele is a protrusion of the bladder through the hiatus (**Figure 2**) caused by weakening of the pubocervical fascia.[10,12] Patients with cystoceles often present with stress incontinence. The position of the urethra can also easily be assessed in the midline sagittal plane, and it normally has a vertical course from the bladder neck through the hiatus. In cases where the posterior bladder prolapses more than the anterior bladder, the urethra may move into the horizontal plane and cause urethral hypermobility. This distinction is important because they are treated differently. Uncomplicated stress incontinence can be treated with retropubic urethropexy, while urethral hypermobility requires a pubovaginal sling to repair.[13] Other potential complications include urinary outlet obstruction and stasis from kinking of the urethrovesical junction, and ureteral obstruction from impingement by the pelvic floor musculature leading to hydronephrosis.

Vaginal, Cervical and Uterine Prolapse

Prolapse of the vaginal vault, cervix and uterus occurs with weakening of the pubocervical fascia, rectovaginal fascia, and uterosacral-cardinal ligament complex.[5] In mild cases of cervical or uterine prolapse, the vagina will appear shortened and the caudal part of the cervix and/or uterus will be below the hiatal line (**Figure 3**). With complete uterine prolapse, the vagina is everted and the uterus is outside of the pelvic cavity (**Figure 4**). Uterine prolapse is commonly treated with hysterectomy.

Vaginal vault prolapse is often accompanied by prolapse of other pelvic organs, especially enteroceles (small

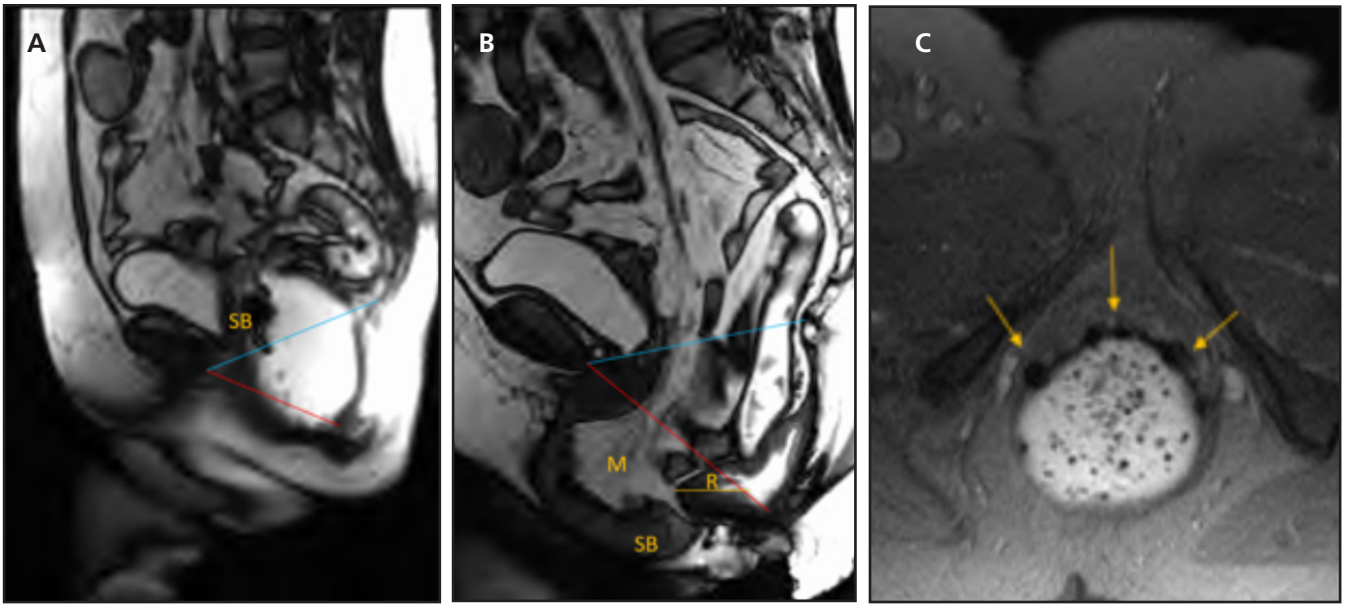

FIGURE 5. *A 55-year-old woman with history of anterior rectocele repair. Sagittal steady-state free precession (SSFP) images at rest (A) and with maximal strain (B). At rest, there is no organ prolapse. With maximal strain, there is a large enterocele with protrusion of small bowel and mesentery 6 cm below the H line. In addition, there is a small recurrent anterior rectocele. PCL (blue), H line (red), small bowel (SB), mesentery (M). Axial gradient image at rest (C) demonstrates susceptibility artifact in the anterior rectal wall from prior anterior rectocele repair.*

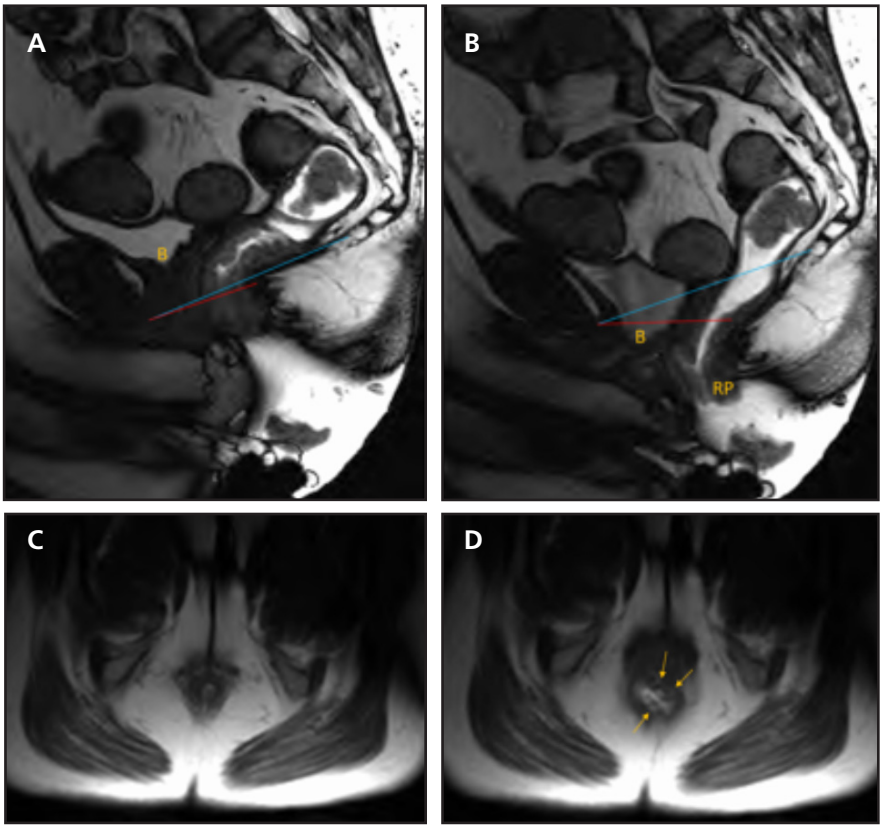

FIGURE 6. *A 49-year-old woman with small with mild internal rectal prolapse and mild cystocele. Sagittal steady-state free precession (SSFP) images at rest (A) and with maximal strain (B). At rest, there is no pelvic organ prolapse. With maximal strain, there is a mild cystocele and small external rectal prolapse. PCL (blue), H line (red), bladder (B), external rectal prolapse (RP). Axial SSFP images at rest (C) and with maximal strain (D) also demonstrate small external rectal prolapse (yellow arrows).*

bowel) or peritoneoceles, which occurs in the widened rectovaginal space.

Enteroceles

Enteroceles are identified when small bowel prolapses through the hiatus, which usually occurs into the rectovaginal space and posterior perineum (**Figure 5**). These are most often seen in patients who have undergone hysterectomy or other pelvic surgery. Similarly, other intraperitoneal structures can prolapse, including sigmoid colon (sigmoidocele), mesentery (mesenterocele), peritoneal fat (peritoneocele) and result in symptoms of obstructed/incomplete defecation or painful defecation. Detecting these entities is a particular strength of dynamic MRI compared to conventional cystoproctography, which only visualizes structures opacified with contrast. Surgical repair of enteroceles is accomplished by closing the rectovaginal space.[14]

Rectoceles, Rectal Invagination, and Rectal Prolapse

A rectocele is an abnormal bulging of the rectal wall and is measured as the depth from the expected location of the rectal wall. Most rectoceles are located

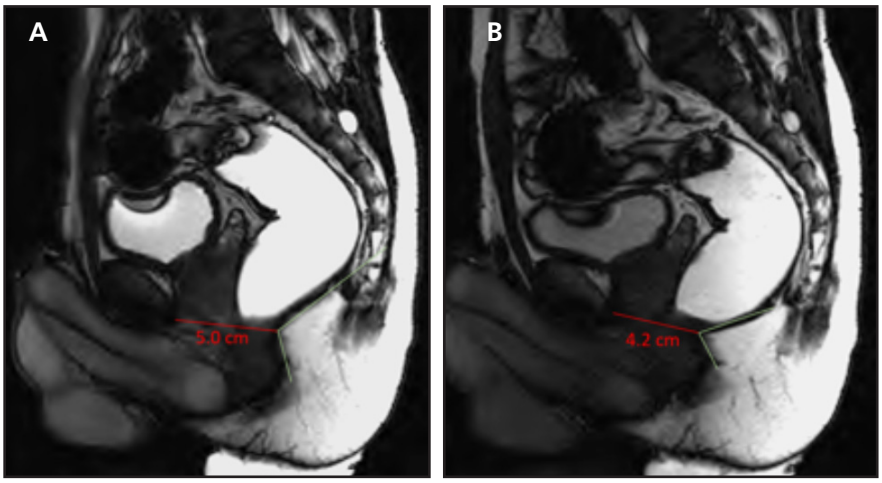

FIGURE 7. *Sagittal steady-state free precession (SSFP) images of a 46-year-old man with pelvic dyskinesia. SSFP images at rest (A) and with maximal strain (B). With maximal strain, the hiatus paradoxically narrows, indicated by the H line decreasing from 5.0 cm to 4.2 cm. The anorectal angle also narrows with maximal strain instead of becoming more obtuse, which also contributes to impaired evacuation. H line (red), anorectal angle (light green).*

along the anterior rectal wall and can bulge into the posterior wall of the vagina, but rarely they can occur along the posterior rectal wall. Rectoceles measuring < 2 cm are usually clinically insignificant.[15] However, retained material in the rectocele during dynamic MRI may explain symptoms of incomplete defecation.

Rectal invagination, also referred to as intussusception, is an internal rectal prolapse that occurs when there is distal telescoping of the rectal wall with strain. This can cause mechanical obstruction with defecation. On midline sagittal images, this is identified as increased folds along the rectal wall with associated narrowing of the rectal lumen during defecation. Low-grade rectal invagination involves the mucosal layer and does not typically cause obstructive symptoms. High-grade rectal invagination is full thickness (involving the mucosal and muscular layers), and is more likely to cause mechanical obstruction. Low-grade rectal invagination can be treated by surgical excision of the abnormal mucosa, and high-grade rectal invagination may require a rectopexy.[16]

External rectal prolapse is defined as rectal invagination protruding through the anus (**Figure 6**), which can lead to rectal bleeding, ulceration, and fecal incontinence.

Dyskinesis

Pelvic floor dyskinesis, also known as anismus or spastic pelvic floor syndrome, is a functional disorder that causes difficulty with defecation and chronic constipation.[17] This is caused by paradoxical contraction of the pelvic floor musculature with maximal strain for defecation, such that the puborectalis hiatus narrows and obstructs the passage of stool (**Figure 7**). People with pelvic floor dyskinesis often experience incomplete and prolonged evacuation, and the H line and the anorectal angle will paradoxically decrease during defecation rather than increase.

Conclusion

Pelvic floor dysfunction is a prevalent, complex disorder that can significantly impact quality of life with symptoms of pelvic pain, organ prolapse, fecal and urinary incontinence, and difficulty with defecation. Pathologies of the pelvic floor often coexist, making them particularly challenging to accurately characterize and plan appropriate surgical repair if indicated. Dynamic MRI is an excellent diagnostic tool that evaluates the pelvic organs and muscular floor in one examination, and helps guide optimal treatment, whether it be conservative or surgical.

References

1. Diokno A, Brock B, Herzog A, et al. Medical correlates of urinary incontinence in the elderly. Urology 1990;36:129-138.
2. Rowe JW, Beedine RW, Ford AB, et al. NIH consensus development panel: urinary incontinence in adults. JAMA 1989;261:2685-2690.
3. Maglinte DDT, Kelvin FM, Fitzgerald K, et al. Association of compartment defects in pelvic floor dysfunction. Am J Roentgenol 1999;172:439-444.
4. Bertschinger KM, Hetzer FH, Roos JE, et al. Dynamic MR imaging of the pelvic floor performed with a patient sitting in an open-magnet unit versus with patient supine in a closed-magnet unit. Radiology 2002;223:501-508.
5. Colaicomo MC, Masselli G, Polettini E, et al. Dynamic MR imaging of the pelvic floor: a pictorial review. RadioGraphics 2009;29(3):e35.
6. Boyadzhyan L, Raman, SS, Raz S. Role of static and dynamic MR imaging in surgical pelvic floor dysfunction. RadioGraphics 2008;28(4):949-967.
7. Comiter CV, Vasavada SP, Barbaric ZL, et al. Grading pelvic prolapse and pelvic floor relaxation using dynamic magnetic resonance imaging. Urology 1999;54: 454-457.
8. Barbaric ZL, Marumoto AK, Raz S. Magnetic resonance imaging of the perineum and pelvic floor. Top Magn Reson Imaging 2001;12:83-92.
9. Healy JC, Halligan S, Reznek RH, et al. Dynamic MR imaging compared with evacuation proctography when evaluating anorectal configuration and pelvic floor movement. Am J Roentgenol 1997;169:775-779.
10. Mortele KJ, Fairhurst J. Dynamic MR defecography of the posterior compartment: indications, technique and MRI features. Eur J Radiol 2007;61(3):462-472.
11. Fielding JR, Giffiths DJ, Versi E, et al. MR imaging of pelvic floor continence mechanism in the supine and sitting positions. Am J Roentgenol 1998;171:1607-1610.
12. DeLancey JO. The anatomy of pelvic floor. Curr Opin Obstet Gynecol 1994;6:313-316.
13. Blaivas JG, Appel FA, Fantl JA, et al. Standards of efficacy for evaluation of treatment outcome in urinary incontinence: recommendations of the urodynamic society. Neurourol Urodyn 1997;16:145-147.
14. Pannu HK, Kaufman HS, Cundiff GW, et al. Dynamic MR imaging of pelvic organ prolapse: spectrum of abnormalities. RadioGraphics 2000;20:1567-1582.
15. Goh V, Halligan S, Kaplan G, et al. Dynamic MR imaging of the pelvic floor in asymptomatic subjects. Am J Roentgenol 2000;174:661-666.
16. Tsiaoussis J, Chrysos E, Glynos M, et al. Pathophysiology and treatment of anterior rectal mucosal prolapse syndrome. Br J Surg 1998;85:1699–1702.
17. Stoker J, Halligan S, Bartram C. Pelvic floor imaging. Radiology 2001:218:621-641.