Enlargement of the Left Superior Intercostal Vein – "Aortic Nipple"

James V. Cortez, M.D., William Vanlandingham, M.D., Keri S. Conner, D.O.

Department of Radiological Sciences, University of Oklahoma Health Sciences Center, Oklahoma City, OK

Case Presentation

A 27-year-old man with a history of classical Hodgkin lymphoma presented to the interventional radiology suite for further investigation of long-term venous access following difficulty with left peripheral inserted central catheter (PICC) line positioning **(Figure 1)**.

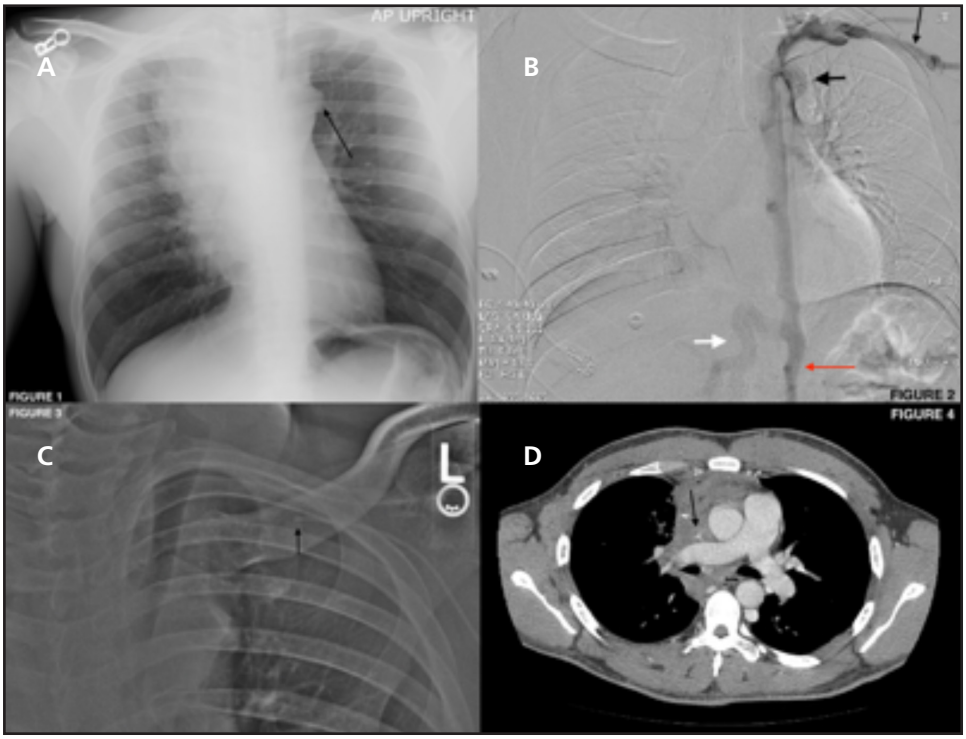

FIGURE 1. *Frontal pre-procedure chest radiograph (A) demonstrates the patient's known large mediastinal mass causing leftward tracheal deviation. A rounded soft-tissue density is seen adjacent to the lateral surface of the aortic knob, colloquially referred to as the "aortic nipple" (arrow). A digital subtraction venogram image obtained after injection of contrast into the patient's left-sided PICC line (B) demonstrates the left subclavian vein (long black arrow) and brachiocephalic vein draining into an enlarged left superior intercostal vein (LSIV) (short black arrow). The enlarged LSIV corresponds to the previously noted soft-tissue density lateral to the aortic knob. The LSIV drains into the accessory hemiazygos vein (red arrow). Note the communication with the azygos vein at the approximate T9 level (white arrow). The azygos vein was noted to communicate with the inferior vena cava (IVC) on subsequent CT through the lumbar veins (not shown). A magnified radiographic image of the chest (C) demonstrates the aberrantly positioned left-sided PICC line overlying the midclavicular area (black arrow). An axial CT image through the chest (D) demonstrates a large mediastinal mass causing significant compression and narrowing of the superior vena cava (SVC) (black arrow).*

Key Imaging Finding(s)

Enlargement of the left superior intercostal vein (LSIV)
Known large mediastinal mass
Superior vena cava (SVC) obstruction

Differential Diagnosis

SVC syndrome
Congestive heart failure (CHF)
Congenital vascular anomalies
Potential mimics of LSIV enlargement (other congenital vascular anomalies)

Discussion

Venous drainage within the thorax can be fairly complex with multiple tributaries eventually draining into the SVC. Although variations are common, the LSIV receives blood supply from the left 1-4 intercostal spaces and crosses anterior to the aortic arch to communicate with the left brachiocephalic vein. The accessory hemiazygos vein receives its blood supply from the hemiazygos and left superior intercostal veins and communicates with the hemiazygos vein inferiorly.[1] The hemiazygos vein receives its supply from the left ascending lumbar and left subcostal veins, as well as from the left renal and gonadal veins; it crosses midline dorsally and communicates with the azygos vein at the T8-T9 level. The azygos vein most commonly drains into the SVC at the level of T5-T6.[2] The number of connections between the azygos and hemiazygos vein can vary between 1 and 5.[3]

In one published series evaluating normal anatomical structures involving 1000 chest radiographs, an enlarged LSIV or "aortic nipple" was seen as a normal structure in 0.9% of cases.[4] An abnormally enlarged LSIV has been demonstrated in up to 7% of adults with known or suspected SVC obstruction secondary to mediastinal tumors or lymphadenopathy.[5] In general, an LSIV diameter > 4.5 mm on an upright posterioranterior (PA) chest x-ray is considered abnormal and should prompt careful scrutiny for subtle mediastinal pathology. In patients who are recumbent or assume a Valsalva maneuver during imaging, the diameter of the LSIV can increase by 1 to 2 mm.[6]

The differential diagnosis for an enlarged LSIV includes superior vena cava obstruction, congestive heart failure, and congenital vascular anomalies.[1] While it is important to be aware of the differential diagnosis for an enlarged left superior intercostal vein, it is also important to be cognizant of other congenital anomalies that may give the appearance of a para-aortic opacity on radiography.[2]

SVC Syndrome

SVC syndrome occurs from obstructed flow from the SVC into the right atrium as can be seen with thrombus, mediastinal fibrosis from prior radiation therapy, or a mediastinal tumor causing compression on the SVC. One pathway that exists for relieving obstruction is the vertebral-azygos-hemiazygos pathway.[7] In the setting of SVC obstruction, drainage through an existing collateral network of veins allows blood to return from the left brachiocephalic vein into the IVC. This occurs because the LSIV is connected to the left brachiocephalic vein superiorly and accessory hemiazygos vein inferiorly. The accessory hemiazygos vein continues as the hemiazygos vein inferiorly. The hemiazygos vein will then communicate with the azygos vein (approximately at the level of T9), and the azygos vein will communicate with the IVC via the lumbar veins as it is unable to drain into the SVC through the azygos arch.[1]

Congestive Heart Failure

Congestive heart failure can lead to enlargement of the LSIV as a result of right atrial hypertension; this increased pressure can be transmitted to the azygos-hemiazygos pathway, potentially enlarging the LSIV.[3]

Congenital Vascular Anomalies

Congenital absence of the azygos vein, although rare, results in enlargement of the left superior intercostal, hemiazygos, and accessory hemiazygos veins as a result of increased venous circulation through these venous strutures.[2] Additionally, absence of the inferior vena cava can lead to enlargement of the LSIV as the blood is shunted away through the azygos-hemiazygos pathway, eventually draining into the SVC. Similarly, if there is hypoplasia of the left brachiocephalic vein, enlargement of the LSIV can occur as a result of blood shunted away from the area of hypoplasia toward the azygos-hemiazygos pathway.[6]

Potential Mimics of LSIV enlargement

Other congenital vascular anomalies can lead to the appearance of a para-aortic opacity on chest radiography. For example, a congenital vascular anomaly that can cause focal widening of the mediastinum adjacent to the aortic knob on a lateral radiograph is a duplicated SVC; in this anomaly, the SVC will likely drain into the coronary sinus or left atrium and is often diagnosed due to a misplaced catheter. Another circumstance in which a congenital vascular anomaly can cause a para-aortic opacity on radiography can be seen in the setting of partial anomalous pulmonary venous return, whereby the anomalous vessel draining the left upper lobe will drain into the left brachiocephalic vein.[2]

Diagnosis

SVC syndrome with an enlarged LSIV

Summary

Knowledge of the normal chest structures is vital to evaluating the chest radiograph, as subtle abnormalities such as a focal soft-tissue density lateral to the aortic knob may suggest the presence of an enlarged LSIV. LSIV enlargement may result from an underlying SVC obstruction, CHF, or congenital vascular anomaly. In the case presented, the LSIV enlargement was due to SVC obstruction from Hodgkin lymphoma.

References

1. Berk RN. Dilatation of the left superior intercostal vein in the plain-film diagnosis of chronic superior vena caval obstruction. Radiology 1964;83(3): 419-423.
2. Demos TC, Posniak HV, Pierce KL, et al. Venous anomalies of the thorax. Am J Roentgenol 2004; 182(5):1139-1150.
3. Dudiak CM, Olson MC, Posniak HV. CT evaluation of congenital and acquired abnormalities of the azygos system. Radiographics 1991;11(2):233-246.
4. Abiru H, Ashizawa K, Hashmi R, et al. Normal radiographic anatomy of thoracic structures: analysis of 1000 chest radiographs in Japanese population. Br J Radiol 2005;78(929):398-404.
5. Mcdonald CJ, Castellino RA, Blank N. The aortic "nipple." Radiology 1970;96(3):533-536.
6. Friedman A, Chambers E, Sprayregen S. The normal and abnormal left superior intercostal vein. Am J Roentgenol 1978;131(4):599-602.
7. Piciucchi S, Barone D, Sanna S, et al. The azygos vein pathway: an overview from anatomical variations to pathological changes. Insights Imaging 2014;5(5):619-628.