Intermetatarsal Lesion

Jeff Lee, D.O., Timothy McCay, D.O., Donald von Borstel, D.O.

Department of Radiology, Oklahoma State University Medical Center, Tulsa, OK

Case Presentation

A 44-year-old woman presented with a 2-year atraumatic history of right forefoot pain. Past medical history and review of systems were noncontributory. She complained of worsening pain with ambulation and physical activity, with pain centered over the forefoot. The clinician was primarily concerned about a metatarsal stress fracture upon physical examination. Initial foot radiographs were normal, leading to further evaluation with MRI (**Figures 1A-D**).

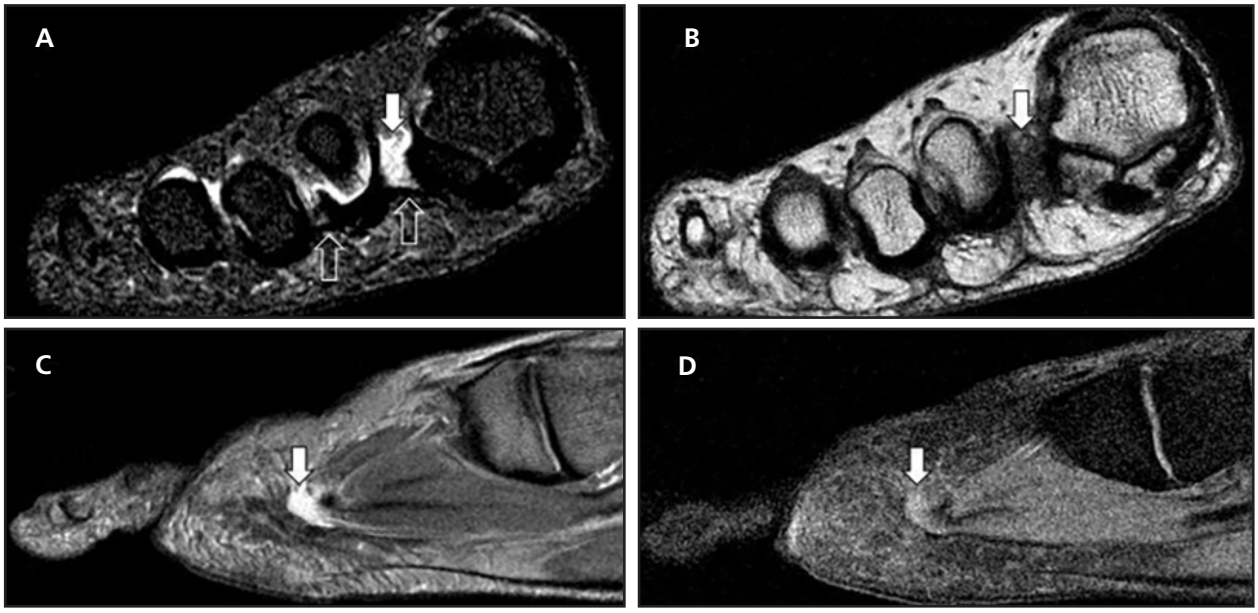

FIGURE 1. *Coronal short tau inversion recovery (STIR) (A), coronal T1 (B), sagittal STIR (C), and sagittal fat-suppressed postcontrast T1 (D) images of the right forefoot demonstrate a STIR hyperintense and T1 hypointense lesion (solid arrows) within the first intermetatarsal space. The lesion lies entirely above the deep transverse metatarsal ligament (open arrows). The lesion is iso- to slightly hyperintense compared with adjacent musculature on the postcontrast image (D) indicating no or minimal enhancement.*

Key Imaging Finding

First intermetatarsal space lesion

Differential Diagnosis

Stress fracture
Morton neuroma
Intermetatarsal bursitis
Ganglion cyst
Abscess (osteomyelitis)
Schwannoma

Discussion

Forefoot pain is a common symptom encountered by clinicians. The forefoot is the major site of load bearing during ambulation and undergoes additional stress with running or jumping motion.[1] As a result, a wide range of patients from elite athletes to the elderly can present with this symptomatology.

The forefoot contains many intricate support structures and, consequently, a myriad of sources can lead to pain in this region.[2] These can be categorized into trauma, infection, arthropathy, tendon disorders, and neoplastic and non-neoplastic masses.

Traumatic lesions such as metatarsal stress fractures or capsuloligamentous injuries (ie, turf toe) are commonly seen in athletes or active individuals such as military recruits. Patients with diabetes or other neuropathic processes frequently develop osteomyelitis and septic joint due to transcutaneous spread of infection from overlying ulcers. Degenerative joint disease is the most common arthropathy affecting the forefoot; however, other etiologies such as rheumatoid arthritis and gout often affect the metatarsal region with accompanying soft-tissue sequelae (ie, pannus and tophus). Tendon disorders such as tendinosis and tenosynovitis are commonly post-traumatic in nature; however, the etiology is often multifactorial with contributing systemic diseases or underlying infection. Many osseous and soft-tissue masses may cause forefoot pain, with non-neoplastic soft tissue lesions representing the overwhelming majority.[2-4]

Due to this wide range in forefoot disorders, MRI has become increasingly important in determining the underlying etiology. While radiologists should be somewhat familiar with the expansive list of potential causes, this case report will predominantly discuss intermetatarsal lesions.

Stress fracture

Metatarsal stress fractures are a common cause of forefoot pain.[1] Radiologists and clinicians alike should have a high index of suspicion for this condition, especially if the patient is prone to chronic repetitive forefoot stress (eg, runners, military members, gymnasts, ballet dancers, etc.). Other structural abnormalities such as hallux valgus deformity or a flattened longitudinal arch may contribute to the development of this disorder.[1,2] Stress fractures are often overlooked due to their chronic insidious manifestation. Failure to recognize and promptly treat stress fractures can lead to increased morbidity and significant time lost from the activity.

On MRI, initial stress response may appear as nonspecific amorphous marrow edema. Subsequent development of a stress fracture presents as a linear band of hypointense signal on both T1- and T2-weighted images. Other secondary findings such as cortical thickening, increased T2-signal, and enhancement of the surrounding soft tissues may also be seen. In terms of location, the middle to distal portions of the second through fourth metatarsals and the hallux sesamoids are the most commonly involved.[1,2]

Morton Neuroma

Morton neuroma is a non-neoplastic fibrosis involving the intermetatarsal nerve. The specific pathogenesis of this entity is not completely understood; however, it is likely related to nerve entrapment and subsequent neural thickening.[2-4] Prolonged forefoot weight bearing, as seen with wearing high-heeled shoes, is thought to contribute to and exacerbate this condition. For this reason, it is most common in middle-aged women.

On MRI, Morton neuroma frequently presents as a circumscribed fusiform mass that demonstrates low to intermediate signal on T1- and T2-weighted images due to its fibrous nature. Some lesions may demonstrate increased signal on T2-weighted images, presumably related to acute edematous changes.[2-4] Variable enhancement may be seen. Regarding location, Morton neuromas commonly arise between the metatarsal heads of the second and third metatarsals and extend above and below the deep transverse metatarsal ligament (DTML).[2,5] The DTML is a forefoot stabilizer composed of 4 intermetatarsal bands extending between the adjacent metatarsal heads, connecting the respective plantar plates.[5]

Intermetatarsal Bursitis

Intermetatarsal bursitis is a common cause of forefoot pain that can be related to multiple pathologies (including Morton neuroma and stress fracture), but is most frequently affiliated with degenerative joint disease.[2-4] The intermetatarsal bursae lie just above the DTML and between the interosseous tendons. The bursae of the second and third intermetatarsal spaces extend distal to the DTML and demonstrate close approximation with the respective neurovascular bundles.[5] This anatomical arrangement may contribute to the concomitant presentation of bursitis with Morton neuromas in these locations.

On MRI, intermetatarsal bursitis presents as a circumscribed fluid collection > 3 mm in diameter, which demonstrates homogeneously increased signal on T2-weighted images and decreased signal on T1-weighted images. Small intermetatarsal fluid collections, < 3 mm in diameter, are considered physiologic.[2,3,5] Intermetatarsal bursitis does not extend below the deep transverse metatarsal ligament, a key distinguishing factor from a Morton neuroma. Peripheral enhancement may be seen.

Ganglion Cyst

Ganglion and synovial cysts are terms often used interchangeably to describe cystic lesions arising from the tendon sheath and synovium.[2,3,6] They

are the most common benign soft-tissue lesions of the foot and are typically dorsal to the metatarsophalangeal joints. Ganglia are thought to be caused by repetitive trauma, as seen with degenerative joint disease, which leads to mucoid cystic neural degeneration.[6]

On MRI, ganglion cysts present as circumscribed homogeneously T2-hyperintense fluid-signal masses that demonstrate variable signal on T1-weighted images, based on proteinaceous content. An associated thin stalk may be visualized extending to the joint space. Thin peripheral and septal enhancement is common without central enhancement.[6]

Abscess (Osteomyelitis)

Abscesses and osteomyelitis in the foot are most commonly caused by transcutaneous spread of infection and may be located anywhere along the length of a sinus tract.[2] Clinical presentation is typically a diabetic patient with cellulitis and ulcers. Ulcers of the forefoot usually present along areas of high pressure, such as the plantar surfaces of the first and fifth metatarsal heads.[2]

On MRI, abscesses demonstrate increased signal on T2-weighted imaging and corresponding decreased signal on T1-weighted imaging with thick peripheral enhancement.[2] Findings of osteomyelitis are typically visualized along the adjacent osseous structures. These include decreased marrow signal on T1-weighted images, corresponding increased signal on T2-weighted images, and heterogeneous contrast enhancement. Reactive adjacent soft-tissue edema and cortical erosions may also be visualized.

Schwannoma

A schwannoma is a benign tumor that develops from Schwann cells along the peripheral nerve sheath. Combined with neurofibromas they constitute approximately 10% of all benign soft-tissue lesions.[2,7] Extremity schwannomas typically present along the flexor aspects, commonly involving the ulnar and peroneal nerves of the arm and leg. Development of a schwannoma in the foot is uncommon, with the incidence estimated as low as 1%.[7]

On MRI, schwannomas present as fusiform encapsulated lesions demonstrating increased signal on T2-weighted imaging that are eccentric to the associated nerve. Additional imaging characteristics can include a surrounding rim of fat, visualization of entering and exiting nerve roots, and a central area of decreased signal on T2-weighted images representing fibrocartilaginous tissue ("target sign").[2]

Diagnosis

Intermetatarsal bursitis

Summary

Intermetatarsal disease is one of the many pathologies that can lead to chronic forefoot pain. If an intermetatarsal lesion is identified on MRI, the location and signal characteristics can be used to suggest a specific disease process. Precise imaging diagnosis, in conjunction with the clinical history, can lead to appropriate treatment and ultimately improve patient outcome.

References

1. Cothran VE, Young CC, White RD, et al. Metatarsal stress fracture. Medscape https://emedicine.medscape.com/article/85746. Updated November 2016. Accessed November 5, 2017.
2. Ashman CJ, Klecker RJ, Yu JS. Forefoot pain involving the metatarsal region: differential diagnosis with MR imaging. Radiographics 2001;21(6):1425-1440.
3. Van Hul E, Vanhoenacker F, Van Dyck P, et al. Pseudotumoural soft tissue lesions of the foot and ankle: a pictorial review. Insights Imaging 2011;2(4):439-452.
4. Bermejo A, De Bustamante TD, Martinez A, et al. MR imaging in the evaluation of cystic-appearing soft-tissue masses of the extremities. Radiographics 2013;33(3):833-855.
5. Theumann NH, Pfirrmann CW, Chung CB, et al. Intermetatarsal spaces: analysis with MR bursography, anatomic correlation, and histopathology in cadavers. Radiology 2001;221(2):478-484.
6. Neto N, Nunnes P. Spectrum of MRI features of ganglion and synovial cysts. Insights Imaging 2016;7(2):179-186.
7. Albert P, Patel J, Badawy K, et al. Peripheral nerve schwannoma: a review of varying clinical presentations and imaging findings. J Foot Ankle Surg 2017;56(3):632-637.