MRI Degenerative Disease of the Lumbar Spine: A Review

Mark Buller, MD

Department of Neuroradiology, Barrow Neurological Institute, Phoenix, AZ

Low back pain is an exceedingly common problem, with a lifetime prevalence of 70% to 85%.[1] This condition is the most common cause of disability in people ages 45 years or younger, with an estimated economic impact of over $100 billion dollars per year, predominantly due to loss of productivity.[2] The etiology of low back pain is multifactorial and is influenced by genetics,[3] age,[4-6] sex[4] and mechanical stresses.[4,7]

Imaging plays a critical role in the diagnosis of low back pain. MRI has become a mainstay in the workup of low back pain due to its excellent soft tissue contrast, cross-sectional capability, and lack of ionizing radiation. This paper will present common MRI findings associated with low back pain, as well as grading systems and common nomenclature to assist in consistent and reproducible reporting of these findings.

MRI Imaging Techniques

An MRI of the lumbar spine generally includes a sagittal T1-weighted spin echo sequence, a sagittal T2-weighted spin echo sequence, and axial T2-weighted images. Additional sequences including axial T1-weighted sequences, sagittal fat-nulling T2-weighted sequences such as short tau inversion recovery (STIR) or modified Dixon (mDixon), and gadolinium-based contrast enhanced T1-weighted sequences may be obtained depending on the institution and the indication for the MRI examination.

Sagittal T1-weighted images are useful in the assessment of bone marrow, which is normally fatty in adults and demonstrates high T1 and T2 signal. Alignment of the vertebral bodies can also be assessed on the sagittal T1-weighted sequence. Due to the high contrast between fat and nerve roots, the T1 sagittal sequences are excellent for assessing the degree of neural foraminal stenosis.

Sagittal T2-weighted images provide excellent contrast between cerebrospinal fluid (CSF) in the thecal sac and the surrounding structures, allowing for assessment of the degree of spinal stenosis at multiple levels on a single image. These sequences are also useful for assessment of the intervertebral discs, and the presence of disc herniation. Fluid sensitive sequences such as STIR and mDixon are used for detecting areas of bone marrow edema.

Axial T2-weighted images provide a level-by-level assessment of the relationship between the thecal sac and the surrounding bony and ligamentous structures and are particularly useful for assessing spinal stenosis and narrowing of the lateral or subarticular recesses. These sequences are also used in assessing the facet joints and ligamentum flava.

In addition to the previously mentioned techniques, several other MRI sequences can be used for assessment of the lumbar spine. There is evidence to suggest that upright MRI of the lumbar spine provides a more accurate assessment of the physiology of low back pain as many patients are more symptomatic when standing.[8,9] However, limited availability, high false-positive rates, and increased motion artifact have limited widespread adoption of this technique.[8] Other techniques such as T1 and T2 relaxation mapping and new sequences like sodium MRI, magic echo and $T1_\rho$ are being developed to assess early molecular changes in the intervertebral disc.[10]

Normal Anatomy

Vertebral Bodies

Lumbar vertebrae are composed of a vertebral body anteriorly, which gives rise to bilateral pedicles from its superior aspect. These extend posteriorly and connect to the transverse processes, which project laterally, and the lamina, which project posteromedially. The

FIGURE 1. *Normal lumbar spine intervertebral disc and neural foramen. Axial T2-weighted image (A) and midline sagittal T2-weighted image (B) of an intervertebral disc with hyperintense nucleus pulposis (asterisk) and hypointense annulus fibrosus (arrowhead). Para-midline sagittal T2-weighted image (C) demonstrates a normal neural foramen with the hypointense nerve root (arrowhead) surrounded by hyperintense perineural fat.*

Table 1. Pfirrmann Classification for Disc Degeneration*

Grade	Disc Structure	NP/AP Distinction	NP Signal	Disc Height
1	Homogeneous	Sharp	Bright hyperintense	Preserved
2	Inhomogeneous	Sharp, cleft may be present	Hyperintense	Preserved
3	Inhomogeneous	Unclear	Isointense	Preserved or slightly decreased
4	Inhomogeneous	No distinction	Hypointense	Mild to moderate decrease
5	Inhomogeneous	No distinction	Black signal	Collapsed

*Modified from reference 19

lamina come together in the midline and connect to the posteriorly projected spinous process. Interposed between each pedicle and lamina are the superior and inferior articular processes, joined by the pars interarticularis.

The vertebral bodies consist of an outer layer of cortical bone, which is low signal intensity on T1- and T2-weighted imaging and surrounds the inner trabecular bone. Trabecular bone is normally high signal on T1- and T2-weighted sequences in adults due to its fatty marrow.

The posterior wall of the vertebral body and inner margins of the pedicles and lamina form a bony ring around the thecal sac. The neural foramina are bordered superiorly and inferiorly by the pedicles of adjacent vertebral bodies, anteriorly by the posterolateral margin of the suprajacent vertebral body and intervertebral disc, and posteriorly by the superior articular process of the subjacent vertebral body. Neural foramina allow the passage of lumbar nerve roots from the thecal sac to the peripheral tissues. Nerve roots within the neural foramina are low signal on T1- and T2-weighted imaging and are normally surrounded by a rim of perineural fat.

Intervertebral Discs

Interposed between the vertebral bodies are the intervertebral discs (**Figure 1**). These discs form the anterior articulation of the vertebral column and have two components: the outer annulus fibrosis (AF) and the inner nucleus pulposis (NP). The AF is a dense fibrocartilaginous structure comprised of 15 to 20 layers of obliquely oriented fibers that run from the inferior endplate of the suprajacent vertebral body to the superior endplate of the subjacent vertebral body.[11] These fibers are primarily comprised of type 1 collagen.[12] This portion of the intervertebral disc normally demonstrates low T1 and low T2 signal. The NP is composed of a loose type 2 collagen matrix and is 70% to 90% water and proteoglycans.[12] The NP demonstrates high T2 and low T1 signal, due to its high water content. A low T2 signal band can be seen centrally within the NP in patients over age 30 and represents a fibrous band or cleft.[13] These discs contact the vertebral body endplates, which are made up of hyaline

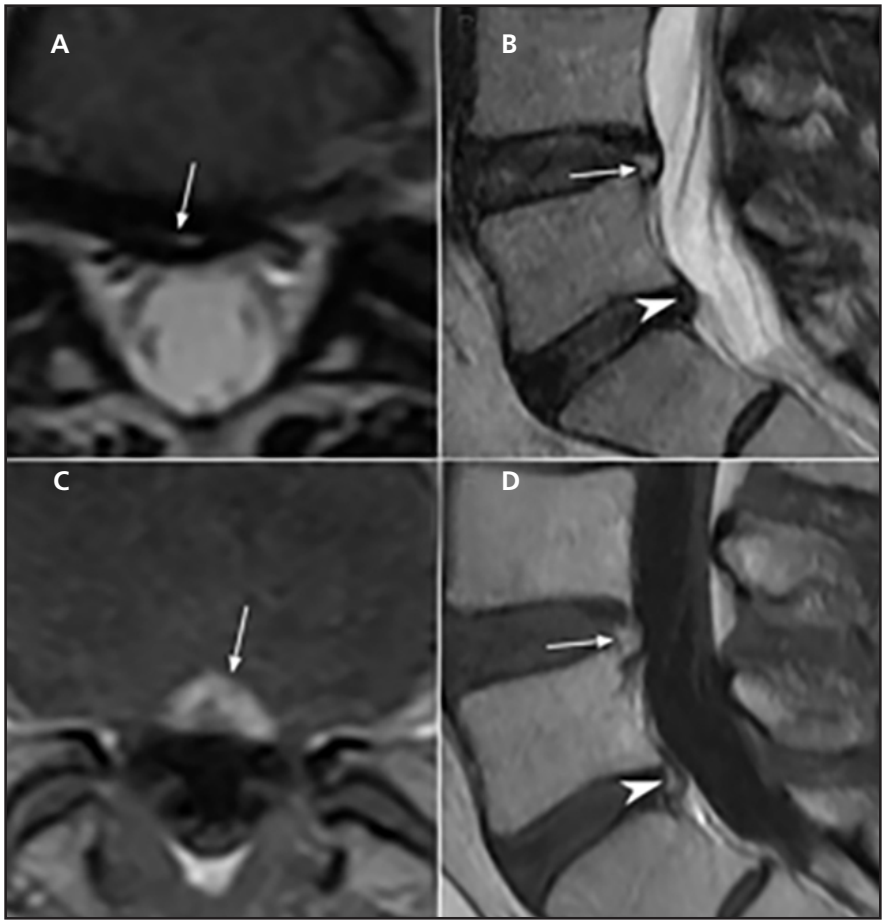

FIGURE 2. *Annular fissures. Axial T2-weighted image of a lumbar disc (A) demonstrates a T2 hyperintense concentric line within the annulus fibrosus (arrow) representing an annular fissure. Midline sagittal T2-weighted image of two lumbar discs (B) with a large annular fissure affecting the superior disc (arrow) and a smaller annular fissure in the lower disc (arrowhead). Axial (C) and midline sagittal (D) T1-weighted images following administration of contrast demonstrate enhancement of the annular fissures.*

cartilage on the vertebral body side and fibrocartilage along the disc.[11]

Facet Joints

The posterior articulation of the vertebral bodies is formed by the facet (zygoapophyseal) joints. These are obliquely oriented synovial joints comprised anterolaterally of the superior articular process of the subjacent vertebral body and posteromedially by the inferior articular process of the suprajacent vertebral body. Facet joints have articular surfaces composed of hyaline cartilage within a fibrous joint capsule lined with synovium.[11] The joint spaces of the facet joints normally measure 2 to 4 mm and demonstrate isointense to high T2 signal.[14]

Ligamentum Flava

Multiple ligamentous structures contribute to the stability of the spinal column. These include the anterior longitudinal ligament, the posterior longitudinal ligament, the interspinous ligament, and the supraspinous ligament. Of particular interest when considering degenerative disease of the lumbar spine are the ligamentum flava, paired ligaments that extend between the lamina of adjacent vertebral bodies. These ligaments are normally thin and low signal on T1- and T2- weighted sequences.

Degenerative Disease

Intervertebral discs

Normal intervertebral discs transition through three phases: growth, maturation, and degeneration.[15] The growth phase is characterized by synthesis of aggrecan and procollagens and increased type 2 collagen and takes place between ages 0 and 15. The maturation phase occurs with a reduction in the synthesis and volume of type 2 collagen in the NP from approximately 15 to 40 years of age. The final stage is degeneration, characterized by increased fibrosis with decreasing type 2 collagen and increasing type 1 collagen, which takes place after age 40.

This disc degeneration, as well as annular fissures and apophyseal osteophyte formation, in the absence of disc height loss, have been termed spondylosis deformans and are considered normal processes associated with aging.[16-18] On MRI, apophyseal osteophytes are characterized by low T1 and T2 outgrowths along the anterior and lateral margins of the endplates. Disc degeneration manifests as loss of T2 signal in the NP. Annular fissures are small areas of T2 hyperintensity in the posterior AF. More extreme changes, including severe disc fissuring, disc height loss and endplate erosion, have been termed intervertebral osteochondrosis, which is a pathologic process.[16-18]

Pfirrmann et al proposed a grading system for intervertebral disc degeneration based on disc structure, distinction between the NP and AF, NP signal intensity and disc height (**Table 1**).[19] This grading system demonstrated good interobserver reliability. A review of the literature in 2005 by Kettler et al found that the Pfirrmann grading system was the only MRI-based system for disc degeneration with a kappa value of greater than 0.6.[20] This system has since been modified by Griffith et al to increase the discriminatory power in the elderly population, with three additional severity levels and a quantitative measurement of disc height reduction.[21]

Annular fissures are regions of high T2 signal intensity seen in the posterior AF of degenerated discs (**Figure 2**). Nearly all degenerated discs have annular fissures, although these may not be visible on MRI.[22] The role of annular

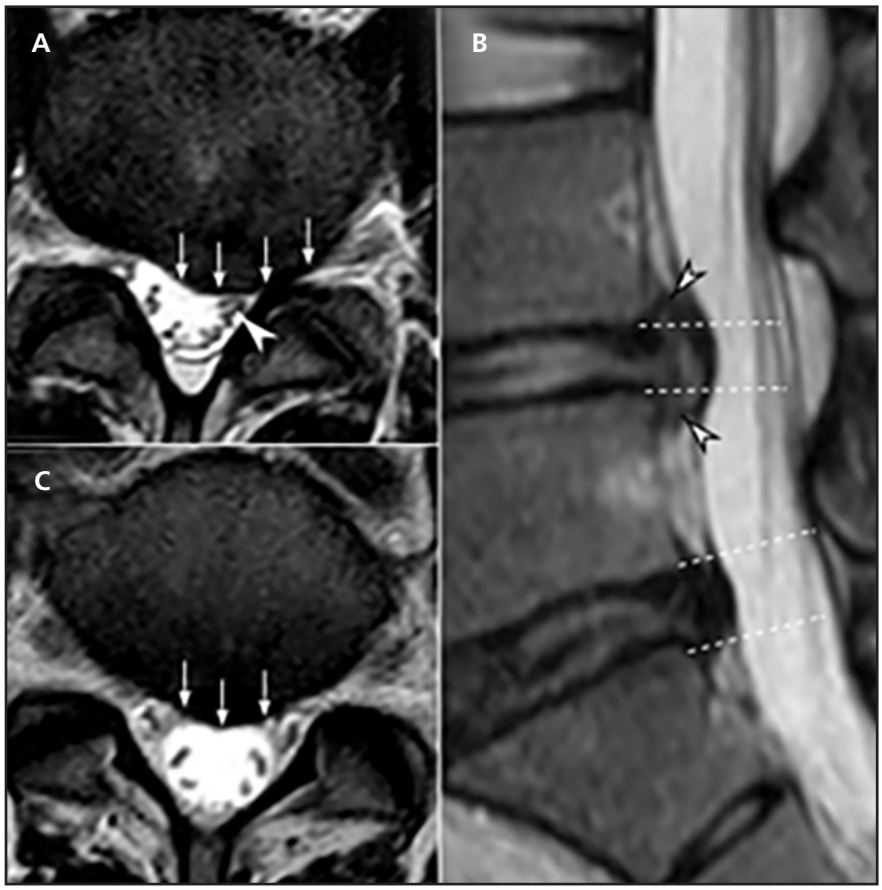

FIGURE 3. *Disc protrusion and extrusion. Axial T2-weighted image of an intervertebral disc (A) demonstrates a focal disc herniation (less than 25% disc circumference) on the left. This posteriorly displaces the nerve root in the left lateral recess (arrowhead). Axial T2-weighted image of the subjacent disc in the same patient (B) demonstrates a similar appearing focal disc herniation located centrally. Sagittal T2-weighted image in the same patient (C) differentiates between the upper level extrusion and lower level protrusion. Note that the extrusion has an apex (arrowheads) that is wider than its base (dashed lines), while the protrusion does not.*

fissures in pain generation is uncertain, with multiple studies noting that annular fissures are often seen in asymptomatic individuals.[23-26] Additionally, evidence suggests that the presence of annular fissures does not increase progression of degenerative disc disease when compared to discs without fissures.[27] For these reasons, the Combined Task Force (CTF) of the North American Spine Society, American Society of Spine Radiology and American Society of Neuroradiology recommend the term "annular fissure" instead of "annular tear" to avoid implying that these regions of signal intensity are a type of acute disc injury.[28]

Another common disc-related finding in degenerative disease of the lumbar spine is disc herniation. There are multiple systems for classification of disc herniations; however, the two most studied systems are those proposed by Jensen et al[29] and Fardon et al.[28] The Jensen classification system splits disc herniations into three categories: disc bulges, protrusions and extrusions. Bulges are defined as symmetric extensions of disc material beyond the interspace. Protrusions are focal or asymmetric extensions of disc material beyond the interspace with the base of the herniation being wider than the apex. Finally, extrusions are defined as more extreme extensions of disc material beyond the interspace with the dimension of the extruded component either wider than the base or not connected to the base. The findings of the CTF published by Fardon et al do not consider disc bulges a form of herniation as bulging can be a normal variant or the result of adjacent bony remodeling or ligamentous laxity.[28] The CTF defines protrusions and extrusions as involving less than 25% of the circumference of the disc, in addition to the features described by Jensen et al (**Figure 3**). Additional terminology proposed by the CTF includes "sequestration" as a subset of extrusion where the extruded material is not continuous with the parent disc (**Figure 4**). A recent systematic review of the literature found that the recommendations by the CTF demonstrated superior interrater reliability compared to Jensen et al.[30] The CTF recommends that this classification be coupled with the localization system proposed by Wiltse et al,[31] which divides the spinal canal into central, subarticular, foraminal and extraforaminal zones (**Figure 5**).

An alternate method for classification of disc herniations differentiates subligamentous herniations from extra-ligamentous herniations. This classification scheme, proposed by Oh et al,[32] describes five criteria that can be used to determine extra-ligamentous herniations: spinal canal compromise of more than half its dimension, internal signal difference in the herniated disc, ill-defined margin of the herniation, disruption of low-signal intensity line covering the herniation, and the presence of an internal dark line in the herniated disc. The authors note that this type of classification is potentially more clinically useful as minimally invasive methods are more successful with subligamentous disc herniations than extra-ligamentous herniations.

Another clinically oriented classification scheme was developed at Michigan State University by Mysliwiec et al.[33] This grading system proposes to separate disc herniations into those that are "substantial" and require surgical intervention, and those that are not and are more likely to have poor surgical outcomes. The authors propose using a line drawn between the anterior margins of the facet joints in the axial plane

FIGURE 4. *Disc sequestration. Axial T2-weighted image (A) demonstrates herniated disc material in the left lateral recess (asterisk), posteriorly displacing and compressing the traversing nerve root (arrow). Para-midline sagittal T2-weighted image (B) of the same disc sequestration (asterisk), which demonstrates higher T2 signal than the parent disc. Note the lack of continuity with the parent disc (arrowhead). Pre-contrast T1-weighted (C) and postcontrast T1-weighted (D) axial images demonstrate the T1 hypointense sequestration (asterisk) with thin peripheral enhancement, again displacing and compressing the traversing nerve root (arrow).*

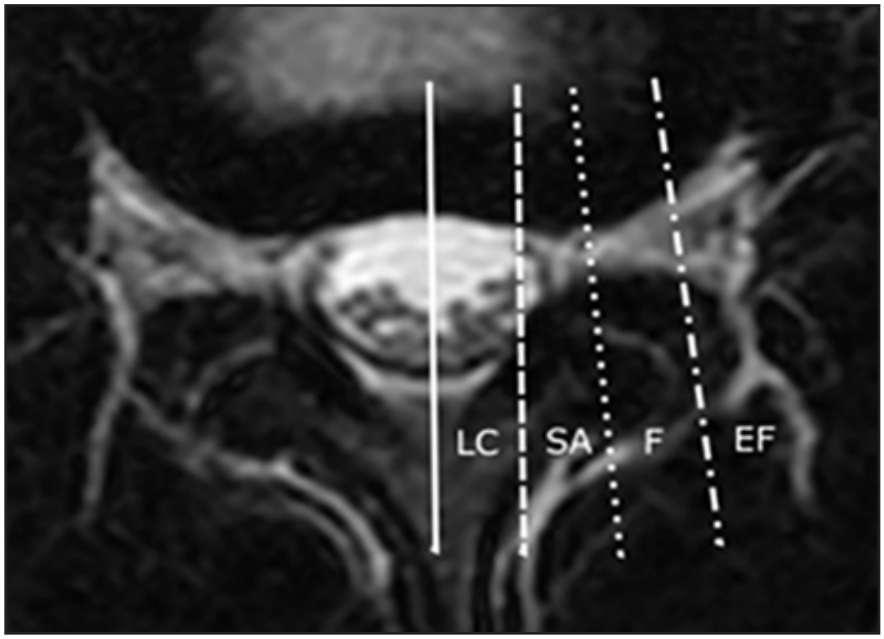

FIGURE 5. *Anatomic scheme proposed by Wiltse et al.[31] Solid line = midline, dashed line = medial margin of the articular facet, dotted line = medial margin of the pedicle, dot-dash line = lateral margin of the pedicle. These landmarks are used to separate the left-central (LC), subarticular (SA), foraminal (F), and extra-foraminal (EF) zones.*

as a reference for the extent of disc herniation. Those herniations that do not extend more than 50% of the distance between the interspace and intrafacet line are classified grade 1 and should be managed conservatively. Those extending beyond grade 1 but not beyond the intrafacet line (grade 2), and those extending beyond the intrafacet line (grade 3) were treated surgically, with good outcome rates that compared favorably to existing literature. While this technique is less subjective than other schemes, it is somewhat limited in that it cannot be used in patients with abnormal facet joints and ligamentum flavum hypertrophy.

Vertebral Body Endplates

Degenerative endplate changes have been classified by Modic et al,[34,35] into three categories: Type 1 changes are edematous changes related to subchondral end plate fractures, formation of vascularized fibrous tissue and an acute reparative response. On MRI, these changes are characterized by increased T2 and decreased T1 signal in the bone marrow adjacent to the endplate. Type 2 changes are related to fatty replacement of normal marrow and are more chronic and stable. These changes will demonstrate increased T1 and T2 signal, with loss of signal on fat suppression sequences. Type 3 changes relate to chronic endplate sclerosis and development of dense woven bone. This dense bone is low signal intensity on both T1- and T2-weighted sequences. Transitions through these stages are not uniformly progressive, and multiple studies have shown resolution of Type 1 changes or progression from Type 2 change to Type 1 change.[35-37] Type 1

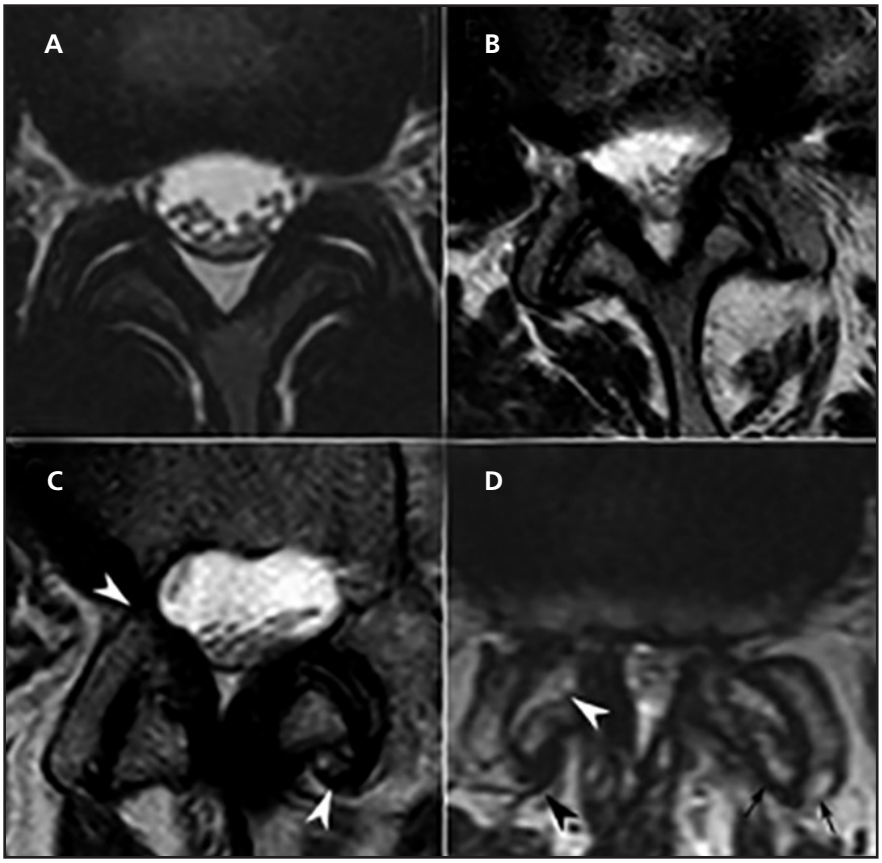

FIGURE 6. *Facet joint degeneration. Axial T2-weighted image of normal facet joints (A). Note the smooth T2 hyperintense joint space. Axial T2-weighted image of mildly degenerated facet joints (B) (Weishaupt grade 1) with irregular joint space narrowing. There is no osteophyte formation. Axial T2-weighted image of moderately degenerated facet joints (C) (Weishaupt grade 2). Joint spaces are narrowed with moderate osteophyte formation (arrowheads). Axial T2-weighted images of severely degenerated facet joints (D) (Weishaupt grade 3), with large osteophyte formation (black arrowhead), subchondral erosion (white arrowhead) and subchondral cysts (black arrows).*

Table 2. Weishaupt Classification of Facet Degeneration*

Grade	Joint Space	Hypertrophy/ Osteophytes	Subarticular erosion
0	Normal (2-4 mm)	None	None
1	Narrow	Mild/Small	None
2	Narrow	Moderate	Mild erosions
3	Narrow	Severe/Large	Severe erosion and/or subchondral cysts

*Modified from reference 13

and Type 3 changes are more associated with low back pain and instability, while Type 2 change is more frequently seen in degenerative disc disease and is less associated with back pain.[38] The Modic classification system has been shown to have good interrater reliability.[39]

More recently, a classification system for endplate changes based on morphology was proposed by Rajasekaran et al.[40] This system grades defects in the endplate, with severity based on the area of the endplate involved. The authors demonstrated good correlation between increasing stage of endplate destruction and increasing degeneration of the associated disc.

Facet Joints

Degenerative changes can occur in the facet joints independent of the presence of degenerative disc disease.[41] Findings of degenerative disease in the facet joints include joint space narrowing, subchondral erosions and cystic change, osteophyte formation, and synovial cyst formation (**Figure 6**). Weishaupt et al utilized these features to develop a grading system for facet disease on MRI.[13] (**Table 2**). This system was found to have moderate to good agreement with CT grading of facet disease, and excellent agreement when allowing for differences of only one grade. This was the only system for MR facet joint degeneration grading recommended by Kettler et al following their literature review.[20]

Superimposed on independent degeneration of the facet joints, loss of disc height can produce a cascade of events causing increased degeneration of the facet joints and surrounding structures. Loss of height causes abnormal contact of the superior tip of the superior articular process of the subjacent vertebra with the undersurface of the pedicle of the suprajacent vertebra. Additional abnormal contact forms between the inferior tip of the inferior articular process of the suprajacent vertebra with the posterior surface of the pars interarticularis of the subjacent vertebra. These contact points cause additional degenerative remodelling, osteophyte formation, and neocyst/synovial cyst formation secondary to altered mechanical forces. These changes can lead to thinning and fractures of the pars interarticularis, neoarthroses of the superior articular facet/pedicle, and narrowing of the neural foramina. These changes are summarized and ac-

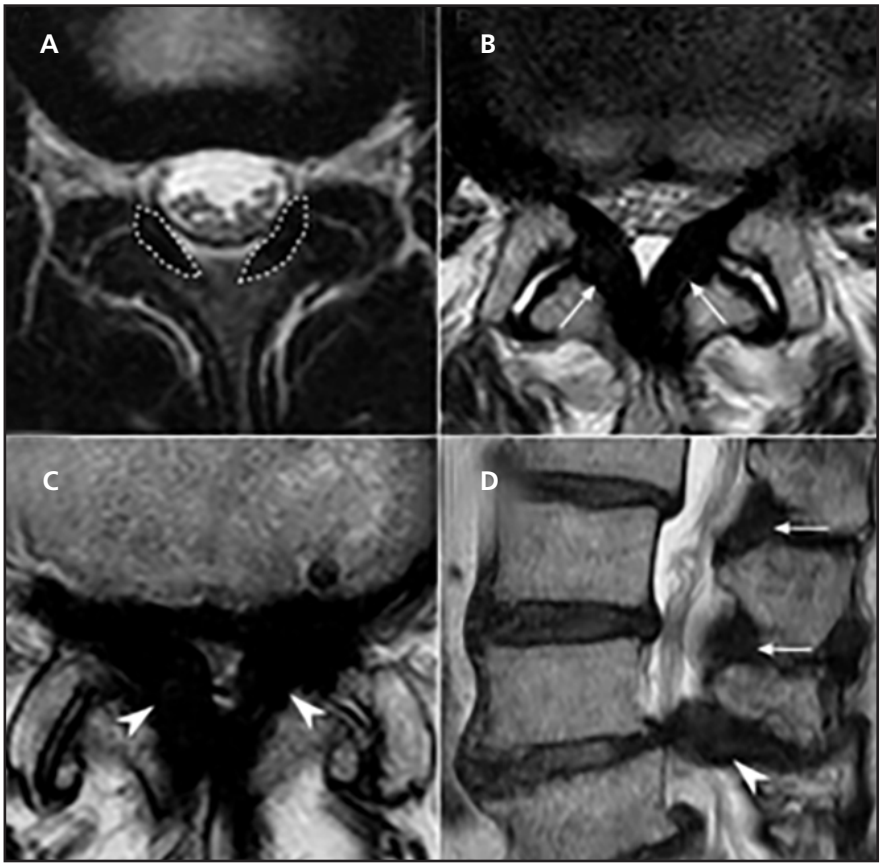

FIGURE 7. *Ligamentum flavum thickening. Axial T2-weighted image of normal liagmentum flava (A) (bordered by dashed lines). Axial T2-weighted images of sequential disc spaces with the upper disc level (B) demonstrating moderate thickening of the ligamentum flava (arrows) and the lower disc level (C) demonstrating severe thickening of the ligamentum flava (arrowheads). Para-midline sagittal T2-weighted image of the same patient (D) demonstrating the moderate (arrows) and severe (arrowhead) thickening of the ligaments.*

companied by detailed line diagrams in a review by Jinkins.[42]

Ligamentum Flava

Ligamentum flavum thickening is a common finding in degenerative disease of the lumbar spine, manifested by increased thickness of low T1 and T2 signal along the posterolateral spinal canal (**Figure 7**). Debate remains about the etiology of the thickening of the ligamentum flava seen in degenerative spine disease. Some authors suggest that this is due to true hypertrophy of the ligament secondary to increased fibrotic change in response to adjacent inflammatory markers.[43] Others suggest that the thickening observed is not true hypertrophy, but rather buckling of a redundant ligament secondary to loss of disc height.[42,44]

Structural sequelae

Spinal Stenosis

The previous section discussed the common degenerative findings affecting the ring of structures surrounding the thecal sac—at the endplates and discs anteriorly, the facet joints posterolaterally, and the ligamentum flava posteriorly. There is conflicting evidence regarding the clinical significance of these findings in isolation and uncertainty regarding which degenerative findings are associated with low back pain.[5,45-47] Indeed, a literature review by Brinjikji et al[47] found that the percentage of asymptomatic 80-year-old patients with disc degeneration, disc bulging and facet hypertrophy was 96%, 84%, and 83%, respectively. This uncertainty makes clinical correlation of back pain with imaging findings extremely difficult. However, these degenerative findings in combination often cause narrowing of the spinal canal and neural foramina with resultant compression of lumbar nerve roots. This compression results in radicular symptoms such as leg pain and weakness, which can be correlated with imaging findings of nerve compression.[48,49]

As with disc herniation, there are multiple grading systems for nerve root compression in the spinal canal. Pfirrmann et al proposed a system to grade the effect of disc herniation on the lumbar nerve roots using three grades: contact of the nerve root, displacement of the nerve root (**Figure 3A**), and compression of the nerve root (**Figure 4**). This scale was found to have good interrater reliability and good correlation with surgical grading.[50]

An alternate grading system was subsequently published by van Rijn et al, which used a 5-point scale that was subsequently dichotomized to either "no root compression" (for initial categories "definitely no root compression," "possibly no root compression" and "indeterminate") and "root compression" (for initial categories "possibly root compression" and "definitely root compression").[51]

A recent review of grading systems for lumbar disc herniations noted that while the van Rijn system was the most reliable grading system to date, the Pfirrmann system has been clinically correlated and demonstrates very good reliability at higher grades, allowing for accurate capture of symptomatic and clinically relevant lesions.[52]

Neural Foraminal Stenosis

Classification systems for neural foraminal narrowing are based on the degree of effacement of perineural fat within the foramen on T1-weighted sagittal images (**Figure 8**). Two such systems were proposed by Wildermuth et al[53] and Lee et al.[54] Both systems use four grades that represent normal

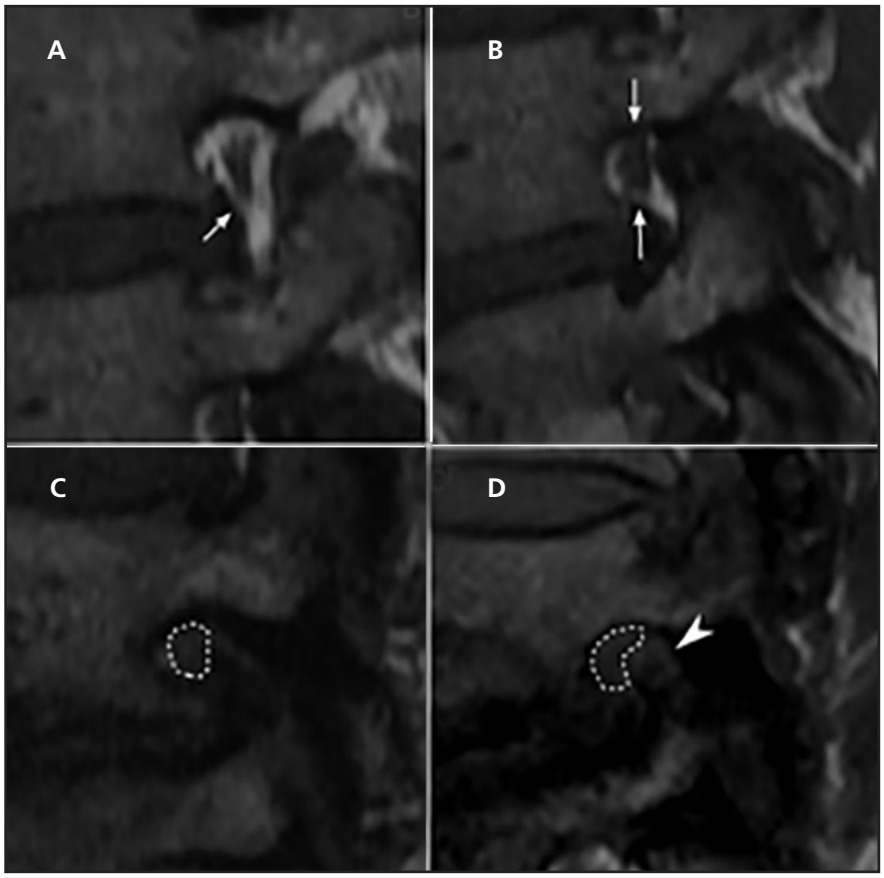

FIGURE 8. *Neural foraminal narrowing. Para-midline sagittal T1-weighted images through four different neural foramina (A-D). A) Mild foraminal narrowing with indentation of the perineural fat that still surrounds the nerve root. B) Moderate foraminal narrowing with obliteration of the perineural fat in two opposite directions (Wildermuth grade 3, Lee grade 1). C) Severe foraminal narrowing with obliteration of the perineural fat but no nerve compression (nerve root outlined with dashed line). D) Severe foraminal with compression of the nerve root (nerve root outlined with dashed line) by a large osteophyte (arrowhead).*

Table 3. Comparison of Wildermuth[53] and Lee[54] Foraminal Narrowing Classifications

System	Normal	Mild	Moderate	Severe
Wildermuth	Perineural fat surrounds nerve root without indentation (grade 0)	Mild indentation of perineural fat still surrounds the nerve (grade 1)	Indentation of perineural fat only partially surrounding the nerve (grade 2)	Complete obliteration of perineural fat (grade 3)
Lee	Perineural fat surrounds nerve root (grade 0)	Perineural fat obliteration in two opposing directions without morphologic change (grade 1)	Perineural fat obliteration in four directions without morphologic change (grade 2)	Nerve root collapse or morphologic change (grade 3)

foramina and mild, moderate, and severe foraminal narrowing (**Table 3**).

The clinical correlation of the Wildermuth and Lee systems was compared by Park et al[55] who concluded that while both systems had similarly excellent interrater reliability, the Wildermuth grading scheme more precisely reflected clinical symptoms, particularly in patients over 50 years of age.

Conclusion

Degenerative disease of the lumbar spine is a common condition that radiologists will encounter frequently. MRI is a mainstay in the assessment of low back pain and degenerative disease of the lumbar spine. This paper has reviewed the common findings affecting the vertebral bodies, intervertebral discs, facet joints, and ligamentum flava, as well as the combined effects of these changes on the spinal canal and neural foramina. Multiple grading systems were presented, with supporting evidence, to help increase the accuracy and consistency when reporting these findings.

References

1. Cassidy JD, Cote P, Carroll LJ, et al. Incidence and course of low back pain episodes in the general population. Spine 2005;30(24)2817-2823.
2. Katz JN. Lumbar disc disorders and low-back pain: socioeconomic factors and consequences. J Bone Jt Surg. 2006;88(Suppl 2):21-24.
3. Battie MC, Videman T, Levalathi E, et al. Genetic and environmental effects on disc degeneration by phenotype and spinal level: a multivariate twin study. Spine 2008;33(25):2801-2808.
4. Miller JA, Schmatz C, Schultz AB. Lumbar disc degeneration: correlation with age, sex, and spine level in 600 autopsy specimens. Spine 1988;13(2):173-178.
5. Boden SD, Davis DO, Dina TS et al. Abnormal magnetic resonance scans of the lumbar spine in asymptomatic subjects. A prospective investigation. J Bone Jt Surg Am (1990);72(3):403-408.
6. Powell MC, Wilson M, Szypryt P, et al. Prevalence of lumbar disc degeneration observed by magnetic resonance in symptomless women. Lancet 1986;2(8520):1366-1367.
7. Lotters F, Burdorf A, Kuiper J et al. Model for the work-relatedness of low-back pain. Scandinavian J Work, Environ Health 2011;29(6):431-440.
8. Khalil JG, Nassr A, Maus TP. Physiologic imaging of the spine. Radiol Clin North Am 2012;50(4): 599-611.
9. Tarantino U, Fanucci E, Iundusi R, et al. Lumbar spine MRI in upright position for diagnosing acute and chronic low back pain: statistical analysis of morphological changes. J Orthop Traumatol 2013;14(1):15-22.

10. Wang C, Auerbach JD, Witschey WRT, et al. Advances in magnetic resonance imaging for the assessment of degenerative disc disease of the lumbar spine. Semin Spine Surg 2007;19(2):65-71.
11. Heuck A, Glaser C. Basic aspects in MR imaging of degenerative lumbar disk disease. Semin Musculoskelet Radiol 2014;18(3):228-239.
12. Panagiotacopulos ND, Pope MH, Bloch R. Water content in human intervertebral discs. Part II. Viscoelastic behavior. Spine 1987;12:912-917.
13. Aguila LA, Piraino DW, Modic MT, et al. The intranuclear cleft of the intervertebral disk: magnetic resonance imaging. Radiology 1985;155(1): 155-158.
14. Weishaupt D, Zanetti M, Boos, N. MR Imaging and CT in osteoarthritis of the lumbar facet joints. Skeletal Radiol 1999;28(4):215-219.
15. Antoniou J, Steffen T, Nelson F, et al. The human lumbar intervertebral disc: evidence for changes in the biosynthesis and denaturation of the extracellular matrix with growth, maturation, aging, and degeneration. J Clin Invest 1996;98(4):996-1003.
16. Modic MT, Herfkens RJ. Intervertebral disc: normal age-related changes in MR signal intensity. Radiology 1990;177(2):332-334.
17. Resnick D, Niwayama G. Degenerative disease of the spine. In: Resnick D, ed. Diagnosis of bone and joint disorders. 3rd ed. Philadelphia: WB Saunders, 1995:1372-1462.
18. Ross JS. Babel 2.0. Radiology 2010; 254(3): 640-641.
19. Pfirrmann CW, Metzdorf A, Zanetti M, et al. Magnetic resonance classification of lumbar intervertebral disc degeneration. Spine 2001;26(17):1873-1878.
20. Kettler A, Wilke HJ. Review of existing grading systems for cervical or lumbar disc and facet joint degeneration. Eur Spine J 2006;15(6):705-718.
21. Griffith JF, Wang Y-XJ, Antonio GE, et al. Modified Pfirrmann grading system for lumbar intervertebral disc degeneration. Spine 2001;32(24):E708-712.
22. Yasuma T, Makino E, Saito S, et al. Histologic development of intervertebral disc herniation. J Bone Joint Surg 1986;68(7):1066-1073.
23. Frymoyer JW, Wiesel SW. The Adult and Pediatric Spine. Philadelphia, PA: Lippincott Williams & Wilkins. 2004.
24. Carragee EJ, Paragioudakis SJ, Khurana S. Lumbar high-intensity zone and discography in subject without low back problems. Spine 2000; 25(23):2987-2992.
25. Schellhas KP, Pollei SR, Gundry CR, et al. Lumbar disc high signal intensity zone. Correlation of magnetic resonance imaging and discography. Spine 1996;21(1):79-86.
26. Quencer RM. The abnormal annulus fibrosus: an we infer the acuteness of an annular injury? Am J Neuroradiol 2002;23(7):1069.
27. Farshad-Amacker NA, Hughes AP, Aichmair A, et al. Is an annular tear a predictor for accelerated disc degeneration? Eur Spine J 2014;23(9): 1825-1829.
28. Fardon DF, Williams AL, Dohring EJ. Lumbar disc nomenclature: version 2.0. The Spine Journal 2014;14(11):2525-2545.
29. Jensen MC, Brant-Zawadzki MN Obuchowski N, et al. Magnetic resonance imaging of the lumbar spine in people without back pain. N Engl J Med 1994;331(2):69-73.
30. Li Y, Fredrickson V, Resnick DK. How should we grade a lumbar disc herniation and nerve root compression? A systematic review. Clin Orthop Relat Res 2015;473:1897-1902.
31. Wiltse LL, Berger PE, McCulloch JA. A system for reporting the size and location of lesions in the spine. Spine 1997; 22(12):1534-1537.
32. Oh K-J, Lee JW, Kwon ET, et al. Comparison of MR imaging findings between exraligamentous and subligamentous disk herniations in the lumbar spine. Am J Neuroradiol 2013;34(3):683-687.
33. Mysliwiec LW, Cholewicki J, Winkelpleck, et al. MSU Classification for herniated lumbar discs on MRI: toward developing objective criteria for surgical selection. Eur Spine J 2010;19(7):1087-1093.
34. Modic MT, Steinberg PM, Ross JS, et al. Degenerative disk disease: assessment of changes in vertebral body marrow with MR imaging. Radiology 1988;166(1 Pt 1):193-199.
35. Modic MT, Masaryk TJ, Ross JS, Carter JR. Imaging of degenerative disc disease. Radiology 1988;168(1):177-186.
36. Vital JM, Gille O, Pointillart, et al. Course of Modic 1 six months after lumbar posterior osteosynthesis. Spine 2003;28(7):715-720.
37. Hutton MJ, Bayer J, Sawant M, et al. Vertebral endplate changes: the natural history as assessed by consecutive magnetic resonance imaging. Bone Jt J 2005;87:233.
38. Toyone T, Takahashi K, Kitahara H, et al. Vertebral bone-marrow changes in degenerative lumbar disc disease. An MRI study of 74 patients with low back pain. J Bone Jt Surg Br 1994;76(5):757-764.
39. Jones A, Clarke A, Freeman BJ, Lam KS, Grevitt MP. The Modic classification: inter- and intraobserver error in clinical practice. Spine 2005; 30(16);1867-1869.
40. Rajasekaran S, Venkatadass K, Naresh Babu J, et al. Pharmacological enhancement of disc diffusion and differentiating of healthy, ageing and degenerated discs: results from in-vivo serial post-contrast MRI studies in 365 human lumbar discs. Eur Spine J 2008;17(5):626-643.
41. Schellinger D, Wener L, Ragsdale BD, et al. Facet joint disorders and their role in the production of back pain and sciatica. Radiographics 1987;7(5):923-944.
42. Jinkins JR. Acquired degenerative changes of the intervertebral segments at and suprajacent to the lumbosacral junction. Radiol Clin N Am 2001;39(1):73-99.
43. Sairyp K, Biyani A, Goel V, et al. Pathomechanism of ligamentum flavum hypertropjhy: a multidisciplinary investigation based on clinical, biomechanical, histologic, and biologic assessments. Spine 2005;30:2649-2656.
44. Altinkaya N, Ylidirim T, Demir S, et al. Factors associated with the thickness of the ligmentum flavum: is ligamentum flavum thickening due to hypertrophy or buckling? Spine 2011;36(16):E1093-1097.
45. Takatalo J, Karppinen J, Niinimaki J, et al. Association of Modic changes, Schmorl's nodes, spondylitic defects, high-intensity zone lesions, disc herniations, and radial tears with low back symptom severity among young Finnish adults. Spine 2012;37(14):1231-1239.
46. Steffens D, Hancock MJ Maher CG, et al. Does magnetic resonance imaging predict future low back pain? A systematic review. Eur J Pain 2014; 18(6):755-765.
47. Brinjikji W, Diehn FE, Jarvik JG. MRI findings of disc degeneration are more prevalent in adults with low back pain than in asymptomatic controls: a systematic review and meta-analysis. Am J Neuroradiol 2015;36(12):2394-2399.
48. Janardhana AP, Rajagopal, Rao S, et al. Correlation between clinical features and magnetic resonance imaging findings in lumbar disc prolapse. Indian J Orthop 2010;44(3):263-269.
49. Beattie PF, Meyers SP, Stratford P, et al. Associations between patient report of symptoms and anatomic impairment visible on lumbar magnetic resonance imaging. Spine 2000;25(7):819-828.
50. Pfirrmann CW, Dora C, Schmid MR, et al. MR imaging-based grading system of lumbar root compromise due to disk herniation: reliability study with surgical correlation. Radiology 2004;230(2): 583-588.
51. van Rijn JC, Klemetso N, Reitsma JB, et al. Observer variation in MRI evaluation of patients suspected of lumbar disk herniation. Am J Roentgenol 2005;184(1):299-303.
52. Li Y, Fredrickson V, Resnick DK. How should we grade a lumbar disc herniation and nerve root compression? A systematic review. Clin Orthop Relat Res 2015;473(6):1897-1902.
53. Wildermuth S, Zanetti M, Duewell S, et al. Lumbar spine: quantitative and qualitative assessment of positional (upright flexion and extension) MR imaging and myelography. Radiology 1998;207(2): 391-398.
54. Lee S, Lee JW, Yeom JS, et al. A practical MRI grading system for lumbar foraminal stenosis. Am J Roentgenol 2010;194(4):1095-1098.
55. Park H-J, Kim SS, Lee S-Y, et al. Clinical correlation of a new MR Imaging method for assessing lumbar foraminal stenosis. Am J Neuroradiol 2012;33(5):818-822.