

The horse that was a zebra: primary lymphoma of bone mimicking shoulder strain in an elderly male

Warren J Keyes, BSc, DC*

Christopher Morgan, BSc, DC*

Andrew Pulinec, BSc, DC**

Primary malignant tumours of the extremities are rarely seen in chiropractic clinics. A case is presented of an eighty year old male who had complained of pain in the right shoulder of several days duration. History and clinical examination were consistent with mechanical joint pain. Following an appropriate course of conservative care the patient continued to improve until a re-injury occurred 3 months later. At that time, radiographs revealed an ill-defined moth-eaten lesion in the proximal humeral head. Subsequent evaluation demonstrated it to be a rare histologic sub-type of lymphoma. This case highlights several important issues ranging from clinical presentation to case management. (JCCA 2000; 44(1):21-28)

KEY WORDS: bone tumours, lymphoma, epidemiology, diagnosis, treatment, prognosis.

Il est rare de rencontrer des cas de tumeur maligne primaire des extrémités en chiropratique. Voici l'histoire d'un homme de quatre-vingts ans qui ressent une douleur à l'épaule droite depuis plusieurs jours. L'anamnèse et l'examen clinique sont compatibles avec une lésion mécanique de l'articulation. Un traitement conservateur approprié est mis en œuvre et l'état du patient s'améliore jusqu'à ce que celui-ci se blesse de nouveau trois mois plus tard. Les radiographies montrent alors une lésion mal définie, mitée, dans la tête proximale de l'humérus. L'évaluation qui s'ensuit révèle la présence d'un lymphome d'un rare sous-type histologique. Le cas soulève plusieurs questions importantes depuis la présentation clinique jusqu'au traitement lui-même. (JACC 2000; 44(1):021-28)

MOTS CLÉS : tumeur osseuse, lymphome, épidémiologie, diagnostic, traitement, pronostic.

Introduction

The clinical presentation of primary lymphoma of bone (PLB), a subtype of non-Hodgkin's lymphoma (NHL) can be a challenging diagnosis for the primary health care professional. Chronic intermittent pain of a dull, achy nature may be the only presenting complaint. In the current case, following detailed history and physical examination, an aged patient with a previous history of similar shoulder pain over several years was presumptively diagnosed with a benign mechanical condition. Considering the relative

and absolute rarity of PLB, especially in this location, the possibility of such an occurrence was considered quite low on the list of differential diagnoses.

The risk of making an incorrect initial diagnosis thereby delaying detection and proper management of life threatening conditions is highlighted by this case. Following the case presentation, this report presents a discussion of PLB emphasising epidemiologic, diagnostic, management and prognostic issues. This case also highlights the responsibility of the chiropractor as a primary care health provider.

* Private practice, Toronto, Ontario.

** Clinical Faculty, Canadian Memorial Chiropractic College, Toronto, Canada.

© JCCA 2000.

Case Report

An eighty-year-old retired, male oral surgeon presented complaining of insidious right sided shoulder pain of three days duration. Since the onset, the pain had been present constantly, but worse in the evening, causing difficulty falling asleep. The character of the pain was described as dull and achy, located over the right humeral head with radiation to the lateral aspect of the arm and extending to the elbow. Pain was aggravated by use of the arm but was present at rest as well. Heat provided relief. Motrin was taken for pain relief. The patient reported a history of previous shoulder pain which he attributed to overuse. General health was reported as good. Although he had smoked for 10 years, he quit 40 years ago. There was no other significant past medical or surgical history.

Examination revealed an older gentleman in moderate discomfort. Range of motion analysis of the right shoulder revealed pain on resisted abduction and at 180 degrees of passive abduction, and limited circumduction. A positive impingement sign was noted. The humeral head and greater tuberosity were very tender to palpation. Cervical spine examination revealed a mild global reduction in range of motion. Nerve root compression tests were unremarkable. Deep tendon reflexes, gross motor strength (qualitatively) and sensory testing were within expected parameters. There was no evidence of muscle wasting. A diagnosis of rotator cuff tendinitis and sub-acromial bursitis was made, and a therapeutic protocol consisting of ultrasound, passive shoulder and neck mobilisation, heat and exercise was initiated.

Over the ensuing two weeks, the pain progressively worsened, and was accompanied by a decrease in function. Shoulder abduction with internal rotation was painful at 80 degrees, and the patient complained of an increasing inability to raise his arm sufficiently enough to put on a shirt. The plan of management was modified to include home cryotherapy. Following the next several days, the pain began to ameliorate. Both the frequency and severity of pain decreased over the next six weeks, as did the difficulty dressing and falling to sleep. Treatment frequency was decreased.

Two and a half months following initial presentation, the patient re-aggravated his shoulder after raking leaves. At that time, passive right shoulder flexion and abduction was painful at 170 and 90 degrees respectively, and a drop sign was noted at 90 degrees. Right sided shoulder pain

was localised to a 3 cm circular area over the anterior aspect of the right humeral head. This region was hypersensitive to pin-prick, but otherwise there were no significant neurological findings. It was decided to continue with the original treatment plan.

Subjective improvement was reported over the next two weeks, at which time a re-evaluation was performed. Palpable tenderness, moderate swelling, and decreased cutaneous sensation was found over the humeral head. A painful arc from 45 to 90 degrees, and a positive drop arm

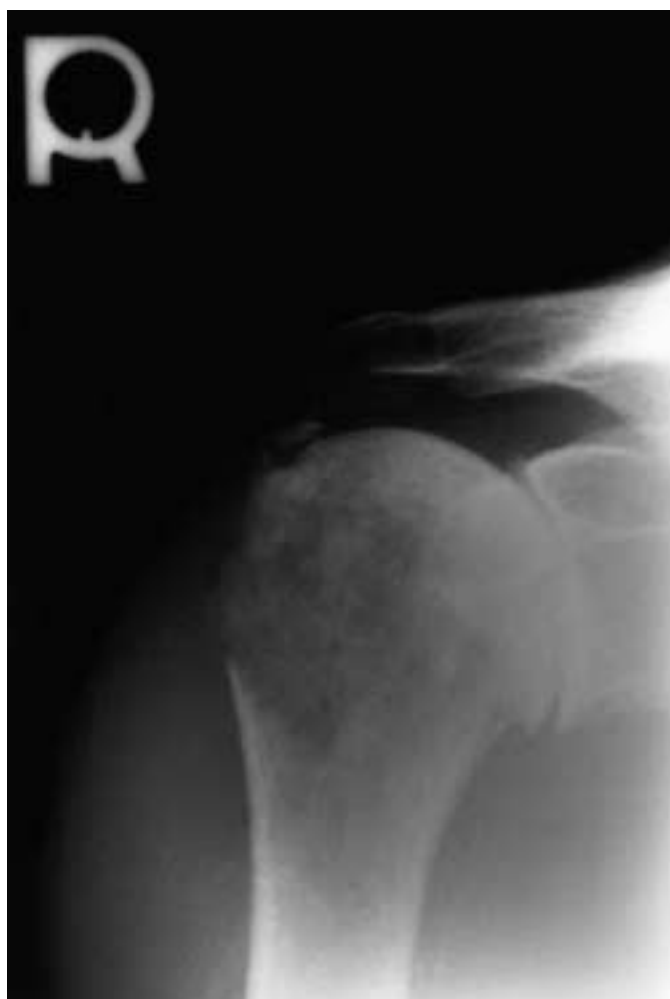

Figure 1 Plain-film radiograph of the right shoulder. Note the large, ill defined, moth-eaten lesion located on the lateral two-thirds of the humeral head (arrows), with destruction and fragmentation of the greater tuberosity (arrowheads). Note the incidental calcific deposit within the supraspinatus tendon (hatched arrow).

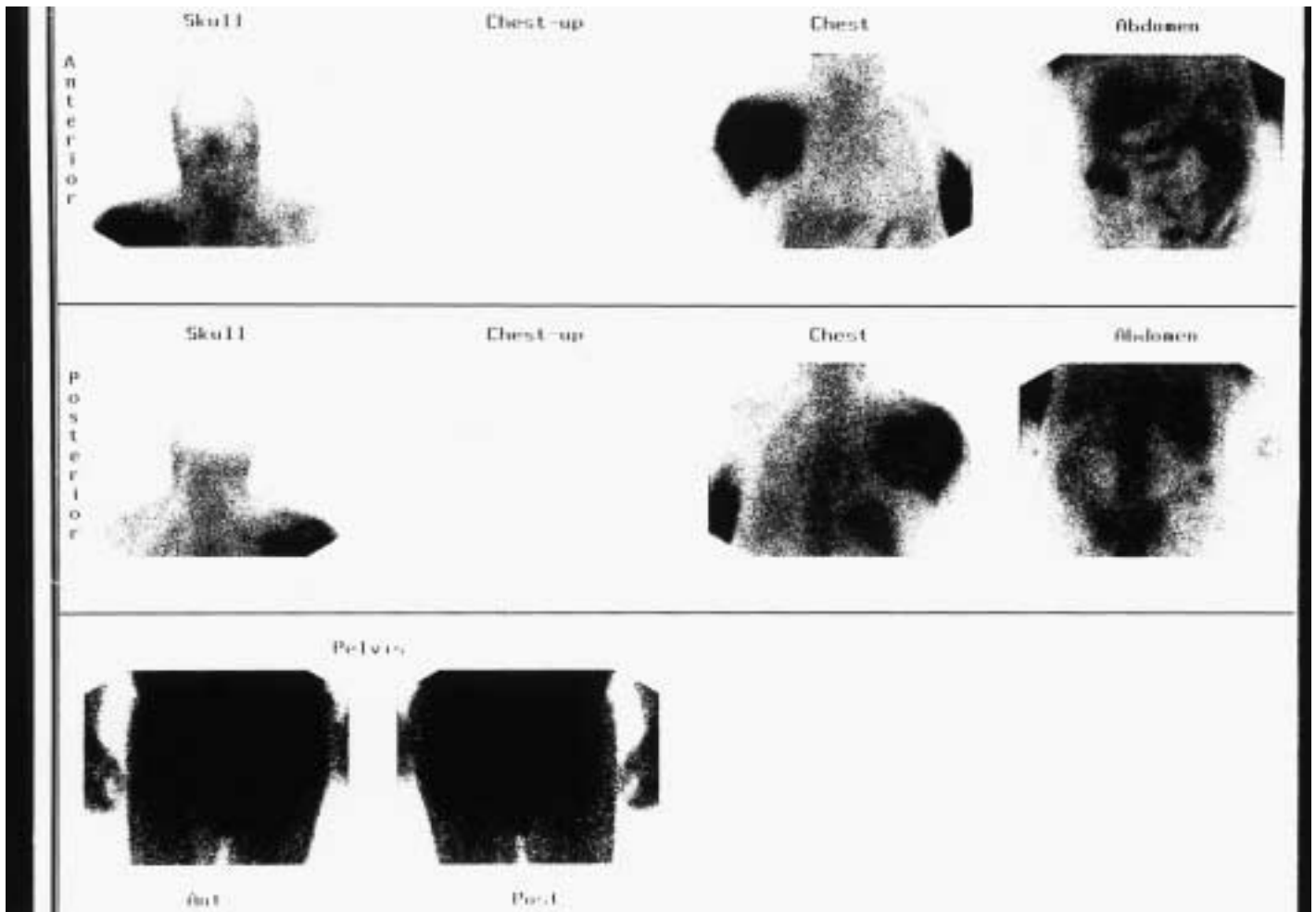


Figure 2 Gallium (Ga 67) bone scan. Observe the region of increased uptake in the right shoulder (arrows), representing the location of the tumour. The increased uptake in the left arm, represents the injection site. (arrowhead)

sign at 55 degrees was noted. Impingement sign was present at 75 degrees of flexion. Due to the recalcitrant nature of this patient's condition, the possibility of the presence of calcific tendinitis was entertained, and a plain-film radiographic assessment was performed.

X-rays identified a large, ill-defined, moth eaten lytic lesion located in the lateral two-thirds of the right humeral head with destruction and fragmentation of the greater tuberosity (Figure 1). Ironically, the suspicion of calcific tendinitis of supraspinatus was also confirmed. A referral to Sunnybrook Health Sciences Centre was made. In the week following his assessment at Sunnybrook, the patient reported that he was now waking 3 to 4 times per night due to pain. He was reviewed again by the chiropractor. Active

abduction was limited to 30 degrees, marked shoulder swelling with pitting oedema was noted in the right arm and shoulder, and it was apparent that he was experiencing a progressive decrease in his functional capacity. The patient had not experienced fever, night sweats or weight loss.

Clinical assessment at Sunnybrook confirmed the above findings. Additionally, abdominal examination revealed no organomegaly or pathology. Chest x-rays, blood work and liver function tests were normal. Neurological examination was unremarkable. Swelling of the right arm with dilated veins, decreased shoulder abduction, flexion and external rotation were found.

Subsequent assessment included Doppler ultrasound,

needle biopsy, gallium bone-scan (Figure 2) and haematological studies. Doppler ultrasound revealed a large multilobulated, mixed echogenic mass measuring $12 \times 5 \times 7$ centimetres anterior to the right shoulder joint related to the anterior cortical surface of the right humeral head and neck, and extending medially into the infraclavicular and axillary regions. There was compression of the axillary and cephalic veins. Correlation with plain films showed a permeative lytic lesion in the right humeral head as well as changes in the glenohumeral joint. There were no other signs of adenopathy. Needle biopsy confirmed a diagnosis of an intermediate to high grade malignant B-cell lymphoma, lymphoblastic type.

The patient was treated with five sessions of *CHOP*,¹ an aggressive chemotherapeutic regimen including cyclophosphamide, doxorubicin, vincristine and prednisone, over several weeks. At the last contact with the oncologist, the patient was reported to have responded extremely well to treatment, but unfortunately he was experiencing clinical depression. A CT scan at that time demonstrated a dramatic reduction in mass size from $12 \times 5 \times 7$ cm to $2 \times 2 \times 1.5$ cm.

Discussion

The appearance of lymphoma has been documented in every body tissue and organ system.² Of the lymphomas, the vast majority (76%) consist of a heterogeneous group, the NHLs, with Hodgkin's disease (HD) accounting for the remaining 24%. Primary Non-Hodgkin's Lymphoma of bone (PLB), however, is a rare, extra-nodal lymphoma histologically identical with others arising in lymphoid or soft tissues, presenting initially as a localised solitary bone lesion.³ First described in 1939,⁴ there have been relatively few reported cases in the literature to date. Many of the reported cases stem from long term clinical data collection in large centres,^{5,6,7,8} while the remainder are single or multiple case reports and series.^{9,10,11,12,13,14,15,16} Reporting of cases has been complicated by inconsistencies in the definition of PLB; several reports include multiple bone sites, others restrict the definition to one site, while still others include soft tissue extension. Furthermore, literature searching and comparison between studies is made difficult by the variety of names applied to this condition, prompting one author to propose the umbrella term "osteolymphoma".¹⁰ PLB has also been defined as a tumour involving a single focus with no evidence of dissemi-

nation within 6 months of the onset of symptoms, and unequivocal histologic evidence of lymphoma in the bone lesion;¹⁷ the current case conforms with this definition.

PLB is a malignant tumour comprising 5% of malignant primary bone tumours,¹⁹ less than 5% of all extra nodal tumours,^{5,7,19} and approximately 1% of all NHLs. Six percent of untreated cases of NHL eventually involve bone, while only 1% have isolated single bone involvement.¹⁷ Limb,⁵ in a study of 2075 cases of the Leeds Bone Tumour Registry found only 54 cases (2.6%) of PLB from 1958 to 1994. Shannon et al. found only 39 cases of PLB at the Royal North Shore Hospital in Sydney, Australia between 1975 and 1992.⁷ Ostrowski⁸ analysed the 422 cases of malignant lymphoma of bone seen at the Mayo Clinic between 1907 and 1982. Of these, only 179 (42%) were classifiable as PLB. Freeman and coworkers¹⁹ examined files from data collected by the End Results Group of cancer registries in the years spanning 1950–1964. In that study, of 1467 cases of non-disseminated lymphomas of extra-nodal origin, only 69 (4.7%) were primary lymphoma of bone.

The ratio of males to females of PLB is approximately 1.6:1.^{5,8,20,21} The average age at diagnosis is in the middle of the 5th decade,^{8,20,21} although there are rare cases in the extreme age groups.⁸ Two recent studies found a bimodal age distribution with peaks in the second to third decade, and fifth to sixth decades.^{5,20}

PLB can involve a wide variety of skeletal locations.^{8,20} Generally, axial sites do not predominate over appendicular sites,^{5,6} although some authors cite a slight preference for the appendicular skeleton.³ The most common appendicular sites are the femur, tibia and humerus, while the most common axial sites include the pelvis, vertebrae, facial bones and scapula. In a study of 422 cases of PLB, 7.6% involved the humerus.⁸ Another study of 98 cases of PLB 14% involved the humerus.²⁰ In a study of 39 cases of PLB,⁷ 17.9% of tumours were located in the humerus. As these numbers appear to indicate, PLB occurs in the humerus in less than one fifth of cases, highlighting the unusual nature of the current case.

Clinical presentation

The most common presenting complaint in primary lymphoma of bone is localized pain with a dull and achy character, with or without a lump or swelling.⁷ Ninety percent of patients with diagnosed PLB reported local pain as their

primary complaint in one large study.²⁰ In that same study, 33% reported an associated mass. Neurological symptoms tend to occur only in cases involving the vertebrae. We identified one unusual case that involved a patient presenting with symptoms suggestive of carpal tunnel syndrome, a manifestation of median nerve compression in the arm from a lymphomatous tumour mass.²² A relative lack of systemic signs and symptoms such as fever, weight loss and night sweats is typical despite extensive local pathologic findings.^{6,7,20,23} The duration of symptoms prior to diagnosis ranges from 24 hours to several years.^{5,6,7,20} Initial evaluation should include an extensive search for other sites of disease.⁴

Radiographic findings

There is no single pathognomonic radiographic presentation for PLB, making it indistinguishable from systemic lymphoma with secondary bone involvement and other bone tumours on this basis alone.¹⁷ Nevertheless, radiographic findings demonstrate abnormalities which warrant immediate referral to tertiary centres. The decision to perform a radiographic assessment in this particular case was the critical step in arriving at a correct diagnosis leading to definitive treatment. The lesion is typically a permeative medullary lytic process with patchy areas of bone destruction which may extend to the adjacent cortical bone.¹⁷ Roughly 77% of cases can be described as permeative osteolytic.¹⁷ Nevertheless, mixed lytic and blastic cases have been reported,²⁴ and represent 16% of cases.¹⁷ The destructive bone lesion may be geographic, localised or moth-eaten.¹⁷ The transition zone may be long or short or sclerotic at the margin. Periosteal reactions are rare.^{4,17} Radiographic signs of aggressivity are pathologic fracture, periosteal new bone (lamellated or interrupted), cortical destruction and soft-tissue mass or swelling.²⁶ The greater the number of signs, the poorer the prognosis.¹⁸ Features that do not seem to affect prognosis include permeative or moth-eaten appearances, blastic lesions, or sunburst periosteal reactions.²⁶ Soft tissue masses may develop independently or through direct extension through the periosteum.²⁵ The radiographic presentation of PLB generates a differential diagnosis of multiple myeloma, Ewing's sarcoma, chronic osteomyelitis, Histiocytosis X, or neuroblastoma when it affects the axial skeleton (although it generally affects multiple bones).^{4,5,7}

The anatomic lesions of PLB are generally more exten-

sive than is identified on plain-film radiographs.⁹ Consequently, advanced radiographic techniques have been used to further elucidate the nature of bone lesions. Ultrasound plays no role in the evaluation of bone disease because of the poor sound transmission characteristics of bone.⁴ Nevertheless it is useful in the determination of soft-tissue involvement. In a retrospective study of 22 cases of PLB, Leeson and coworkers²⁶ found consistent results using technetium 99 and gallium 67 bone scans, enabling them to assess the biologic behaviour of the bone lesions. Few reports have described the appearance of PLB using magnetic resonance imaging (MRI). In one study,²⁷ MRI was used to define the extent of tumour and degree of soft tissue and bone marrow involvement. Salter and co-workers²⁸ report a case in which MRI unveiled other foci of disease undetected by routine staging. Hicks et al.,⁹ using high resolution MRI, propose a mechanism by which tumour cells from PLB can produce soft-tissue masses despite minimal evidence of cortical destruction on plain radiographs. Clinical staging is assessed using bone marrow aspiration and biopsy, bone radiographs, bone scan, CT scanning, lymphangiogram, angiogram and routine laboratory investigations.⁶

Definitive diagnosis

Definitive diagnosis is rendered through histological analysis of biopsied specimens. There are several systems currently in use for classification of morphological subtypes and grading. Among these are the Rappaport, Lukes and Collins, Dorfman, British, World Health Organisation and Keil classifications.²⁹ Based upon a critical analysis of the similarities and differences among classifications, a compromise working classification which incorporates the relevant concepts and terminology from several classifications has been developed.³⁰ Clinical staging is done according to the Ann Arbor Classification⁹ which determines the extent to which the tumour has spread or metastasized. The staging designation IE refers to no nodal disease, and IIE refers to regional nodal disease.

Grading refers to the degree of malignancy of the tumour. Lymphomas are graded on histological grounds with particular cell features associated with the rate of progress of the tumour.³¹ Low grade malignancies are associated with well differentiated relatively inactive cell types, and progress slowly, over years.³¹ Alternatively,

high grade malignancies are associated with primitive actively proliferating cells, and progress over weeks or months.³¹

The current case was staged as IIE (local nodal involvement), and graded as medium to high. Although a detailed discussion of the histopathology of PLB goes beyond the scope of this report, there are two major subtypes of PLB, notably poorly differentiated lymphoma (PDL) and diffuse histiocytic lymphoma (DHL). Of the two, DHL is the most common subtype accounting for approximately 70% of cases of PLB;⁶ interestingly, the DHL subtype demonstrates the most favourable outcome to conventional treatment.^{6,32} Both grading and staging impact directly on treatment options, prognosis and survival.

Treatment

Treatment of primary lymphoma of bone has changed substantially over the past 50 years. Historically, from the time of the original report on PLB,⁴ and well into the 1950’s, both amputation and radiation were the treatments of choice, and were met with varying results. A landmark study of 44 cases in 1954 recommended irradiation of the primary lesion in conjunction with one or more courses of *Coley’s toxin* (an early chemotherapeutic agent), and advised against amputation except in specific cases.³³ Cur-

rently, amputation is rare, but radiation and chemotherapy alone or in combination are very common.³⁴

Survival Rates

Survival rates have changed somewhat over the past several years. Table 1 presents the results of several studies regarding survival rates. In general, stage of disease was found to be the single most important prognostic indicator of overall survival.²⁰ Furthermore, gender and histologic grade had no influence on prognosis.²⁰ Overall, PLB appears to have a relatively good prognosis, but further refinement in classification may lead to more scientific selection of methods of treatment and increased survival rates.⁵

Summary and conclusions

The preceding report documents a case of primary NHL of bone in an elderly male presenting to a chiropractic clinic. The clinical presentation was not unlike that which would be seen as a result of mechanical overuse; history of previous trauma, raking of leaves and so forth all correlate well with onset of shoulder pain. This case, in light of the relative rarity of PLB illustrates several important points for the practising clinician. First, the appropriateness of periodic reassessment of patients’ conditions; this is possible

Table 1
Rates of survival for lymphoma of bone

Study	Year	N	Type	Survival Rate
Francis et al. ³³	1925–1948	N/A	Primary lymphoma of bone	5 year – 48.4% 10 year – 33.3%
Ostrowsky et al. ⁸	1907–1982	422	Primary lymphoma of bone	5 year – 58% 10 year – 53%
Boston et al. ²⁰	N/A	98	Group I – primary lymphoma of bone Group II – multifocal bone disease	5 year – 44% 5 year – 23%
Shannon et al. ²⁰	1975–1992	39	Primary lymphoma of bone	5 year – 68%
Christie et al. ³⁴	1979–1993	70	Primary lymphoma of bone	5 year – 59%
Limb et al. ⁵	1958–1994	54	Primary lymphoma of bone	2 year – 64% 5 year – 46% 10 year – 24%

only when systematic histories and clinical examinations have been performed initially. This allows the clinician to objectively assess the progress of care and the possible need for modification of the management protocol. In this case, a reassessment led to the discovery of a potentially life-threatening condition.

Secondly, this case highlights the invaluable nature of the plain film radiograph as a first-line diagnostic imaging tool. Although x-rays are not required in every case, they should be considered in suspicious cases. Indications for taking diagnostic x-rays relevant to this case are age over 50 years, history of previous and recent trauma, lack of clinical improvement despite conservative care, marked decrease in range of motion, presence of swelling, clinical evidence of venous obstruction (recent dilated veins in the arm) and progressive pain. Any of these conditions should initiate prompt radiological evaluation.

Thirdly, is the need for early referral for definitive diagnosis and treatment. This particular form of cancer responds quite well in the early stages, but its aggressive nature renders it more difficult to treat in the later stages. Finally, an axiom from a wise old sage (neither one of us); when you hear the sound of hoof beats, it may be zebras.

Acknowledgements

The authors would like to thank Dr. Ken Imree of the Sunnybrook Health Sciences Centre, Toronto, Canada, for his kind assistance in the preparation of this case report. We would also like to thank Dr Igor Steiman of the Canadian Memorial Chiropractic College for proofreading the final manuscript.

References

- 1 Shipp MA, Neuberg D, Janicek M, Canellos GP, Shulman LN. High dose CHOP as initial therapy for patients with poor-prognosis aggressive non-Hodgkin's lymphoma: a dose-finding pilot study. *J Clin Oncol* 1995; 12:2916–2923.
- 2 Isaccson PG, Norton AJ. *Extranodal Lymphomas*. New York: Churchill Livingstone, 1994.
- 3 Yochum TR, Rowe LJ. *Essentials of Skeletal Radiology*. 2nd Edition, Vol II, 1996.
- 4 Parker BR, Marglin S, Castellino RA. Skeletal manifestations of leukemia, Hodgkin Disease, and non-Hodgkin lymphoma. *Semin Roentgenol* 1980; 4:302–315.
- 5 Limb D, Dreghorn C, Murphy JK, Mannion R. Primary lymphoma of bone. *Int Orthop* 1994; 18:180–183.
- 6 Desai, S, Jambhekar NA, Soman CS, Advani SH. Primary lymphoma of bone: a clinicopathologic study of 25 cases reported over 10 Years. *J Surg Oncol* 1991; 46:256–259.
- 7 Shannon, JA, Bell DR, Levi JA, Wheeler HR, Boyle FM. Bone presentation of non-Hodgkin's lymphoma: experience at the Royal North Shore Hospital, Sydney; highlighting primary bone lymphoma. *Aust NZ J Med* 1994; 24:701–704.
- 8 Ostrowski, ML, Unni KK, Banks PM, Shives TC, Evans RG, O'Connell MJ, Taylor WF. Malignant lymphoma of bone. *Cancer* 1986; 58:2646–2655.
- 9 Hicks DG, Totterman SMS, Judkins AR, Rubens DJ, Rosier RN. Primary lymphoma of bone, correlation of magnetic resonance imaging features with cytokine production by tumor cells. *Cancer* 1995; 75:973–980.
- 10 Christie DR, Cahil SP, Barton MB. Primary Bone Lymphoma (osteolymphoma). *Australas Radiol* 1996; 40(3):319–23.
- 11 Yang H, Zhao, L, Zheng Z. Primary lymphoma of bone: a clinicopathologic study of 22 cases. *Chung Hua Ping Li Hsueh Tsa Chih* 1995; 24(5):300–302 (abstract only).
- 12 Paige ML, Bernstein JR. Transcalvarial primary lymphoma of bone. A report of two cases. *Neuroradiology* 1995; 37(6):456–458.
- 13 Wang JC, Kim DS, Goldberg M. Anaplastic large cell Ki-1 lymphoma: primary bone presentation in an elderly man. *Acta Haematol* 1996; 96(1):45–49.
- 14 Wang Y, Cai R, Wang G. Primary non-Hodgkin's malignant lymphoma of bone in 5 patients. *Chung Hua Wai Ko Tsa Chih* 1995; 33(2):86–88 (abstract only).
- 15 Schmidt AG, Kohn D, Bernhards J, Braitinger S. Solitary skeletal lesions as primary manifestations of non-Hodgkin's's lymphoma. Report of two cases and review of the literature. *Arch Orthop Trauma Surg* 1994; 113(3):121–128.
- 16 White LM, Siegel S, Shin SS, Weisman MH, Sartoris DJ. Primary lymphoma of the calcaneus. *Skeletal Radiol* 1996; 25(8):775–778.

- 17 Edeiken-Monroe B, Ediken J, Kim E. Radiologic concepts of lymphoma of Bone. *Rad Clin North Am*, 1990; 28:841–864.
- 18 Huvos AG. Bone Tumors. In: *Diagnosis, treatment and Prognosis*. Philadelphia: WB Saunders, 1979; 392–402.
- 19 Freeman C, Berg JW, Cutler SJ. Occurrence and prognosis of extranodal lymphomas. *Cancer* 1972; 29:252–260.
- 20 Boston HC Jr, Dahlin DC, Ivins JC, Cupps RE. Malignant lymphoma (so-called reticulum cell sarcoma) of bone. *Cancer* 1974; 34:1131–1137.
- 21 Shoji H, Miller TR. Primary reticulum cell sarcoma of bone, significance of clinical features upon prognosis. *Cancer* 1971; 28: 1234–1244.
- 22 Desta K, O’Shaughnessy M, Milling MAP. Non-Hodgkin’s Lymphoma Presenting as Median Nerve Compression in the Arm. *J Hand Surg (British and European Volume)* 19B No.3 1994; 289–291.
- 23 Dosoretz DE, Raymond AK, Murphy GF, Dopke KP, Schiller AL, Wang, CC, Suit HD. Primary lymphoma of bone: the relationship of morphologic diversity to clinical behaviour. *Cancer* 1982; 50:1009–1014.
- 24 Fuller LM, Sullivan MP, et al. *Hodgkin’s disease and non Hodgkin’s; lymphomas in adults and children*. New York: Raven Press, 1984.
- 25 Lodwick GS, Wilson AJ, Farrell C et al. Estimating rate of growth in bone lesions: observer performance and error. *Radiology* 1980; 134:585–590.
- 26 Leeson MC, Makely JT, Carter JR, Krupco T. The use of radioisotope scans in the evaluation of primary lymphoma of bone. *Orthop Rev* 1989; 18(4):410–416.
- 27 Cook MA, Manfredi OL, Kasaw S, Murukulta S. Primary skeletal lymphoma imaging and pathologic correlation. *J Am Osteopath Assoc* 1996; 10,610–612.
- 28 Salter M, Sollaccio RJ, Bernreuter WK, Weppelmann B. Primary lymphoma of bone: the use of MRI in pretreatment evaluation. *Am J Clin Oncol* 1989; Apr 12:2,101–105.
- 29 Simon R, Durrleman S, Hoppe RT et al. The non-Hodgkin lymphoma pathologic classification project. Long-term follow-up of 1153 patients with non-Hodgkin’s lymphoma. *Ann Intern Med* 1988; 109:939–945.
- 30 Nathwani BN. A critical analysis of the classifications of non-Hodgkin’s lymphomas. *Cancer* 1979; 44:2:347–384.
- 31 Govan ADT, Macfarlane PS, Callander R. *Pathology Illustrated*. New York: Churchill Livingstone Inc., 1991; pp. 599–604 .
- 32 Horwich A, Peckham M. Bad risk non-Hodgkin’s lymphomas. *Semin Hematol* 1983; 20:35–56.
- 33 Francis KC, Higinbotham NL, Coley, BL. Primary reticulum cell sarcoma of bone. Report of 44 cases. *Surg Gynecol Obstet* 1954; 99:142–146.
- 34 Christie DR, Barton MB, Bryant G, Cheuk R, Gebiski V, Hornsey J, Lonergan D, MacLeod C, Pratt G, Roos D. Osteolymphoma (primary bone lymphoma): an Australian review of 70 cases. *Aust NZ J Med* 1999; 29(2):214–219.

