March / April 2022
Volume 51, Number 2

Applied Radiology

AppliedRadiology®

50 YEARS

The Journal of Practical Medical Imaging and Management

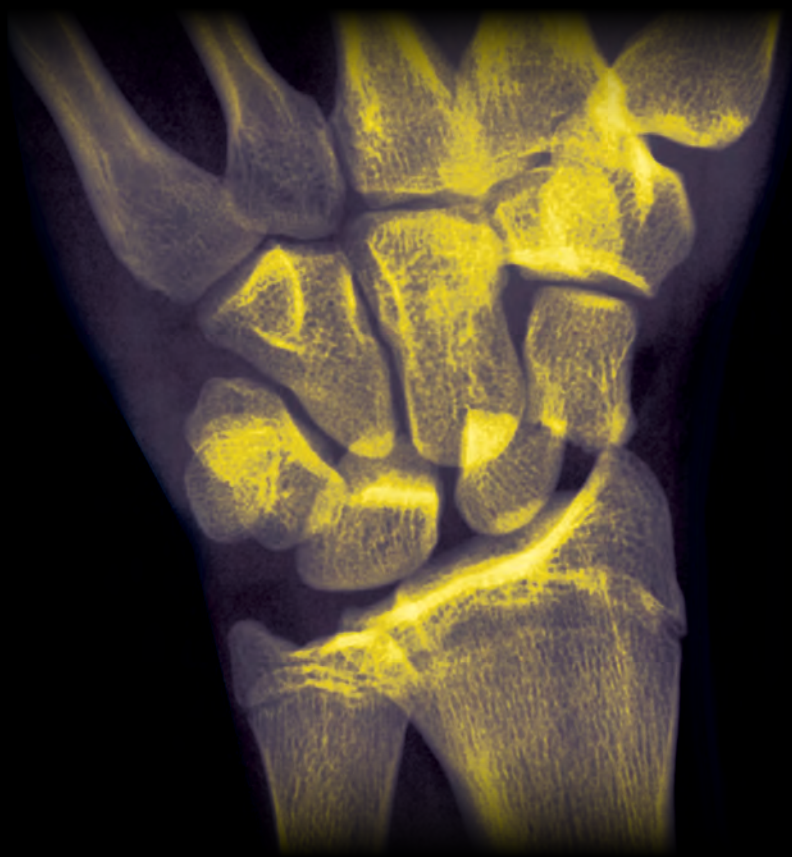

SA–CME
Imaging Upper Extremity Injuries in Pediatric Athletes

Blind Spots in Spine Imaging

Developing Breast Imaging Services in Low-Resource Settings

Imaging Utilization: A Matter of Dollars and Sense

Endovascular Catheter Fragment Retrieval

March / April 2022 Volume 51, Number 2

www.appliedradiology.com

What does seeing better with MultiHance® mean?[1-4,*]

MultiHance® demonstrated significantly improved visualization and contrast enhancement of CNS lesions when compared with Gadavist® at 0.1 mmol/kg.[1,†]

- 3 blinded independent readers reported superiority for MultiHance in signifi cantly (*P* .0001) more patients for all evaluated end points. The opinions of the 3 readers were identical for 61.9%–73.5% of the patients, resulting in values of 0.414–0.629 for inter-reader agreement.
- The 0.1 mmol/kg dose of MultiHance demonstrated consistently better visualization for all readers for all visualization endpoints vs non-contrast MRI.

The individuals who appear are for illustrative purposes. All persons depicted are models and not real patients.
Please see Brief Summary of Prescribing Information including Boxed Warning on adjacent page.
*MRI imaging of the CNS in adult and pediatric patients to visualize lesions with abnormal BBB or abnormal vascularity of the brain, spine and associated tissues or to evaluate adults with known or suspected renal or aorto-ilio- femoral occlusive vascular disease.

MultiHance® (gadobenate dimeglumine) injection, 529 mg/mL and
MultiHance® Multipack™ (gadobenate dimeglumine) injection, 529 mg/mL

Indications and Usage:
MultiHance® (gadobenate dimeglumine) injection, 529 mg/mL is a gadolinium-based contrast agent indicated for intravenous use in:
- Magnetic resonance imaging (MRI) of the central nervous system (CNS) in adults and pediatric patients (including term neonates) to visualize lesions with abnormal blood-brain barrier or abnormal vascularity of the brain, spine, and associated tissues and
- Magnetic resonance angiography (MRA) to evaluate adults with known or suspected renal or aorto-ilio-femoral occlusive vascular disease

IMPORTANT SAFETY INFORMATION:

WARNING: NEPHROGENIC SYSTEMIC FIBROSIS

Gadolinium-based contrast agents (GBCAs) increase the risk for NSF among patients with impaired elimination of the drugs. Avoid use of GBCAs in these patients unless the diagnostic information is essential and not available with non-contrasted MRI or other modalities. NSF may result in fatal or debilitating systemic fibrosis affecting the skin, muscle and internal organs.
- **The risk for NSF appears highest among patients with:**
  - **chronic, severe kidney disease (GFR < 30 mL/min/1.73m^2), or**
  - **acute kidney injury.**
- **Screen patients for acute kidney injury and other conditions that may reduce renal function. For patients at risk for chronically reduced renal function (e.g. age > 60 years, hypertension or diabetes), estimate the glomerular filtration rate (GFR) through laboratory testing.**
- **For patients at highest risk for NSF, do not exceed the recommended MultiHance dose and allow a sufficient period of time for elimination of the drug from the body prior to re-administration.**

CONTRAINDICATIONS
MultiHance is contraindicated in patients with known allergic or hypersensitivity reactions to gadolinium-based contrast agents.

WARNINGS AND PRECAUTIONS
Nephrogenic Systemic Fibrosis: NSF has occurred in patients with impaired elimination of GBCAs. Higher than recommended dosing or repeated dosing appears to increase risk.
Hypersensitivity Reactions: Anaphylactic and anaphylactoid reactions have been reported, involving cardiovascular, respiratory, and/or cutaneous manifestations. Some patients experienced circulatory collapse and died. In most cases, initial symptoms occurred within minutes of MultiHance administration and resolved with prompt emergency treatment. Consider the risk for hypersensitivity reactions, especially in patients with a history of hypersensitivity reactions or a history of asthma or other allergic disorders.
Gadolinium Retention: Gadolinium is retained for months or years in several organs. The highest concentrations have been identified in the bone, followed by brain, skin, kidney, liver, and spleen. At equivalent doses, retention varies among the linear agents. Retention is lowest and similar among the macrocyclic GBCAs. Consequences of gadolinium retention in the brain have not been established, but they have been established in the skin and other organs in patients with impaired renal function. Minimize repetitive GBCA imaging studies, particularly closely spaced studies when possible.
Acute Renal Failure: In patients with renal insufficiency, acute renal failure requiring dialysis or worsening renal function have occurred with the use of GBCAs. The risk of renal failure may increase with increasing dose of the contrast agent. Screen all patients for renal dysfunction by obtaining a history and/or laboratory tests.
Extravasation and Injection Site Reactions: Extravasation of MultiHance may lead to injection site reactions, characterized by local pain or burning sensation, swelling, blistering, and necrosis. Exercise caution to avoid local extravasation during intravenous administration of MultiHance.
Cardiac Arrhythmias: Cardiac arrhythmias have been observed in patients receiving MultiHance in clinical trials. Assess patients for underlying conditions

or medications that predispose to arrhythmias. The effects on QTc by MultiHance dose, other drugs, and medical conditions were not systematically studied.
Interference with Visualization of Certain Lesions: Certain lesions seen on non-contrast images may not be seen on contrast images. Exercise caution when interpreting contrast MR images in the absence of companion non-contrast MR images.

ADVERSE REACTIONS
The most commonly reported adverse reactions are nausea (1.3%) and headache (1.2%).

USE IN SPECIFIC POPULATIONS
Pregnancy: GBCAs cross the human placenta and result in fetal exposure and gadolinium retention. Use only if imaging is essential during pregnancy and cannot be delayed.
Lactation: There is no information on the effects of the drug on the breastfed infant or the effects of the drug on milk production. However, limited literature reports that breastfeeding after MultiHance administration to the mother would result in the infant receiving an oral dose of 0.001%-0.04% of the maternal dose.
Pediatric Use: MultiHance is approved for intravenous use for MRI of the CNS to visualize lesions with abnormal blood brain barrier or abnormal vascularity of the brain, spine, and associated tissues in pediatric patients from birth, including term neonates, to less than 17 years of age. Adverse reactions in pediatric patients were similar to those reported in adults. No dose adjustment according to age is necessary in pediatric patients two years of age and older. For pediatric patients, less than 2 years of age, the recommended dosage range is 0.1 to 0.2 mL/kg. The safety of MultiHance has not been established in preterm neonates.

Please see full Prescribing Information and Patient Medication Guide for additional important safety information for/regarding MultiHance (gadobenate dimeglumine) injection, 529 mg/mL at https://www.braccoimaging.com/us-en/products/magnetic-resonance-imaging/multihance

You are encouraged to report negative side effects of prescription drugs to the FDA. Visit www.fda.gov/medwatch or call 1-800-FDA-1088.

MultiHance is manufactured for Bracco Diagnostics Inc. by BIPSO GmbH – 78224 Singen (Germany) and by Patheon Italia S.p.A., Ferentino, Italy.
MultiHance is a registered trademark of Bracco International B.V.
MultiHance Multipack is a trademark of Bracco International B.V.
All other trademarks and registered trademarks are the property of their respective owners.

References: 1. Seidl Z, Vymazal J, Mechi M, et al. Does higher gadolinium concentration play a role in the morphologic assessment of brain tumors? Results of a multicenter intraindividual crossover comparison of gadobutrol versus gadobenate dimeglumine (the MERIT Study). *AJNR Am J Neuroradiol.* 2012;33(6):1050-1058. **2.** Maravilla KR, Maldjian JA, Schmalfuss IM, et al. Contrast enhancement of central nervous system lesions: multicenter intraindividual crossover comparative study of two MR contrast agents. *Radiology.* 2006;240(2):389-400. **3.** Rowley HA, Scialfa G, Gao PY, et al. Contrast-enhanced MR imaging of brain lesions: a large-scale intraindividual crossover comparison of gadobenate dimeglumine versus gadodiamide. *AJNR Am J Neuroradiol.* 2008;29(9):1684-1691. **4.** Vaneckova M, Herman M, Smith MP, et al. The benefits of high relaxivity for brain tumor imaging: results of a multicenter intraindividual crossover comparison of gadobenate dimeglumine with gadoterate meglumine (The BENEFIT Study). *AJNR Am J Neuroradiol.* 2015 Sep;36(9):1589–1598.

Bracco Diagnostics Inc.
259 Prospect Plains Road, Building H
Monroe Township, NJ 08831 USA
Phone: 609-514-2200
Toll Free: 1-877-272-2269 (U.S. only)
Fax: 609-514-2446
© 2022 Bracco Diagnostics Inc. All Rights Reserved.

Bracco Diagnostics

multihance
(gadobenate dimeglumine) injection, 529 mg/mL

Rx ONLY
Please see full prescribing information.
A brief summary follows:

WARNING: NEPHROGENIC SYSTEMIC FIBROSIS

Gadolinium-based contrast agents (GBCAs) increase the risk for NSF among patients with impaired elimination of the drugs.
Avoid use of GBCAs in these patients unless the diagnostic information is essential and not available with non-contrasted MRI or other modalities. NSF may result in fatal or debilitating systemic fibrosis affecting the skin, muscle and internal organs.

- The risk for NSF appears highest among patients with:
  - chronic, severe kidney disease (GFR <30 mL/min/1.73m2), or
  - acute kidney injury.
- Screen patients for acute kidney injury and other conditions that may reduce renal function. For patients at risk for chronically reduced renal function (e.g. age > 60 years, hypertension or diabetes), estimate the glomerular filtration rate (GFR) through laboratory testing.
- For patients at highest risk for NSF, do not exceed the recommended MultiHance dose and allow a sufficient period of time for elimination of the drug from the body prior to re-administration. [see *Warnings and Precautions (5.1)*]

1 INDICATIONS AND USAGE

1.1 MRI of the Central Nervous System (CNS)

MultiHance is indicated for intravenous use in magnetic resonance imaging (MRI) of the central nervous system (CNS) in adults and pediatric patients (including term neonates), to visualize lesions with abnormal blood-brain barrier or abnormal vascularity of the brain, spine, and associated tissues.

1.2 MRA of Renal and Aorto-ilio-femoral Vessels

MultiHance is indicated for use in magnetic resonance angiography (MRA) to evaluate adults with known or suspected renal or aorto-ilio-femoral occlusive vascular disease.

4 CONTRAINDICATIONS MultiHance is contraindicated in patients with known allergic or hypersensitivity reactions to gadolinium-based contrast agents [see *Warnings and Precautions (5.2)*].

5 WARNINGS AND PRECAUTIONS

5.1 Nephrogenic Systemic Fibrosis (NSF) Gadolinium-based contrast agents (GBCAs) increase the risk for nephrogenic systemic fibrosis (NSF) among patients with impaired elimination of the drugs. Avoid use of GBCAs among these patients unless the diagnostic information is essential and not available with non-contrast enhanced MRI or other modalities. The GBCA-associated NSF risk appears highest for patients with chronic, severe kidney disease (GFR <30 mL/min/1.73m²) as well as patients with acute kidney injury. The risk appears lower for patients with chronic, moderate kidney disease (GFR 30-59 mL/min/1.73m²) and little, if any, for patients with chronic, mild kidney disease (GFR 60-89 mL/min/1.73m²). NSF may result in fatal or debilitating fibrosis affecting the skin, muscle and internal organs. Report any diagnosis of NSF following MultiHance administration to Bracco Diagnostics (1-800-257-5181) or FDA (1-800-FDA-1088 or www.fda.gov/medwatch).

Screen patients for acute kidney injury and other conditions that may reduce renal function.

Features of acute kidney injury consist of rapid (over hours to days) and usually reversible decrease in kidney function, commonly in the setting of surgery, severe infection, injury or drug-induced kidney toxicity. Serum creatinine levels and estimated GFR may not reliably assess renal function in the setting of acute kidney injury. For patients at risk for chronically reduced renal function (e.g., age > 60 years; diabetes mellitus or chronic hypertension), estimate the GFR through laboratory testing.

Among the factors that may increase the risk for NSF are repeated or higher than recommended doses of a GBCA and the degree of renal impairment at the time of exposure. Record the specific GBCA and the dose administered to a patient. For patients at highest risk for NSF, do not exceed the recommended MultiHance dose and allow a sufficient period of time for elimination of the drug prior to re-administration. For patients receiving hemodialysis, physicians may consider the prompt initiation of hemodialysis following the administration of a GBCA in order to enhance the contrast agent's elimination. The usefulness of hemodialysis in the prevention of NSF is unknown [see *Dosage and Administration (2) and Clinical Pharmacology (12)*].

5.2 Hypersensitivity Reactions Anaphylactic and anaphylactoid reactions have been reported, involving cardiovascular, respiratory, and/or cutaneous manifestations. Some patients experienced circulatory collapse and died. In most cases, initial symptoms occurred within minutes of MultiHance administration and resolved with prompt emergency treatment. Prior to MultiHance administration, ensure the availability of personnel trained and medications to treat hypersensitivity reactions. If such a reaction occurs stop MultiHance and immediately begin appropriate therapy. Additionally, consider the risk for hypersensitivity reactions, especially in patients with a history of hypersensitivity reactions or a history of asthma or other allergic disorders. Observe patients for signs and symptoms of a hypersensitivity reaction during and for up to 2 hours after MultiHance administration.

5.3 Gadolinium Retention Gadolinium is retained for months or years in several organs. The highest concentrations (nanomoles per gram of tissue) have been identified in the bone, followed by other organs (e.g. brain, skin, kidney, liver, and spleen. The duration of retention also varies by tissue and is longest in bone. Linear GBCAs cause more retention than macrocyclic GBCAs. At equivalent doses, gadolinium retention varies among the linear agents with Omniscan (gadodiamide) and Optimark (gadoversetamide) causing greater retention than other linear agents [Eovist (gadoxetate disodium), Magnevist (gadopentetate dimeglumine), MultiHance (gadobenate dimeglumine)]. Retention is lowest and similar among the macrocyclic GBCAs [Dotarem gadoterate meglumine), Gadavist (gadobutrol), ProHance (gadoteridol)].

Consequences of gadolinium retention in the brain have not been established. Pathologic and clinical consequences of GBCA administration and retention in skin and other organs have been established in patients with impaired renal function [see *Warnings and Precautions (5.1)*]. There are rare reports of pathologic skin changes in patients with normal renal function. Adverse events involving multiple organ systems have been reported in patients with normal renal function without an established causal link to gadolinium retention [see *Adverse Reactions (6.2)*]. While clinical consequences of gadolinium retention have not been established in patients with normal renal function, certain patients might be at higher risk. These include patients requiring multiple lifetime doses, pregnant and pediatric patients, and patients with inflammatory conditions. Consider the retention characteristics of the agent when choosing a GBCA for these patients. Minimize repetitive GBCA imaging studies, particularly closely spaced studies when possible.

5.4 Acute Renal Failure In patients with renal insufficiency, acute renal failure requiring dialysis or worsening renal function have occurred with the use of gadolinium-based contrast agents. The risk of renal failure may increase with increasing dose of the contrast agent. Screen all patients for renal dysfunction by obtaining a history and/or laboratory tests. Consider follow-up renal function assessments for patients with a history of renal dysfunction.

5.5 Extravasation and Injection Site Reactions Extravasation of MultiHance may lead to injection site reactions, characterized by local pain or burning sensation, swelling, blistering, and necrosis. In animal experiments, local reactions including eschar and necrosis were noted even on Day 8 post perivenous injection of MultiHance. Exercise caution to avoid local extravasation during intravenous administration of MultiHance. If extravasation occurs, evaluate and treat as necessary if local reactions develop.

5.6 Cardiac Arrhythmias Cardiac arrhythmias have been observed in patients receiving MultiHance in clinical trials [see *Adverse Reactions (6.1)*]. Assess patients for underlying conditions or medications that predispose to arrhythmias.

A double-blind, placebo-controlled, 24-hour post dose continuous monitoring, crossover study in 47 subjects evaluated the effect of 0.2 mmol/kg MultiHance on ECG intervals, including QTc. The average changes in QTc values compared with placebo were minimal (≤5 msec). QTc prolongation between 30 and 60 msec were noted in 20 subjects who received MultiHance vs. 11 subjects who received placebo. Prolongations ≥ 61 msec were noted in 6 subjects who received MultiHance and in 3 subjects who received placebo. None of these subjects had associated malignant arrhythmias. The effects on QTc by MultiHance dose, other drugs, and medical conditions were not systematically studied.

5.7 Interference with Visualization of Certain Lesions Certain lesions seen on non-contrast images may not be seen on contrast-images. Exercise caution when interpreting contrast MR images in the absence of companion non-contrast MR images.

6 ADVERSE REACTIONS

The following adverse reactions are discussed in greater detail in other sections of the label:
• Nephrogenic systemic fibrosis [see *Warnings and Precautions (5.1)*]
• Hypersensitivity reactions [see *Warnings and Precautions (5.2)*]

6.1 Clinical Trials Experience

Because clinical trials are conducted under widely varying conditions, adverse reaction rates observed in the clinical trials of a drug cannot be directly compared to rates in the clinical trials of another drug and may not reflect the rates observed in practice.

Adult In clinical trials with MultiHance, a total of 4967 adult subjects (137 healthy volunteers and 4830 patients) received MultiHance at doses ranging from 0.005 to 0.4 mmol/kg. There were 2838 (57%) men and 2129 (43%) women with a mean age of 56.5 years (range 18 to 93 years). A total of 4403 (89%) subjects were Caucasian, 134 (3%) Black, 275 (6%) Asian, 40 (1%) Hispanic, 70 (1%) in other racial groups, and for 45 (1%) subjects, race was not reported.

The most commonly reported adverse reactions in adult subjects who received MultiHance were nausea (1.3%) and headache (1.2%). Most adverse reactions were mild to moderate in intensity. One subject experienced a serious anaphylactoid reaction with laryngeal spasm and dyspnea [see *Warnings and Precautions (5.2)*]. Serious adverse reactions consisting of convulsions, pulmonary edema, acute necrotizing pancreatitis, and anaphylactoid reactions were reported in 0.1% of subjects in clinical trials.

Adverse reactions that occurred in at least 0.5% of 4967 adult subjects who received MultiHance are listed below (Table 2), in decreasing order of occurrence within each system.

TABLE 2: ADVERSE REACTIONS REPORTED IN ≥ 0.5% OF ADULT SUBJECTS WHO RECEIVED MULTIHANCE IN CLINICAL TRIALS

Number of subjects dosed	4967
Number of subjects with any adverse reaction	517 (10.4%)
Gastrointestinal Disorders:	
Nausea	67 (1.3%)
General Disorders and Administration Site Disorders:	
Injection Site Reaction	54 (1.1%)
Feeling Hot	49 (1.0%)
Nervous System Disorders:	
Headache	60 (1.2%)
Dysgeusia	33 (0.7%)
Paresthesia	24 (0.5%)
Dizziness	24 (0.5%)

The following adverse reactions occurred in less than 0.5% of the 4967 adult subjects who received MultiHance. Serious adverse reactions described above are not repeated below.

Blood and Lymphatic System Disorders: Basophilia; **Cardiac Disorders:** Atrioventricular block first degree; **Eye Disorders:** Eye pruritus, eye swelling, ocular hyperemia, visual disturbance; **Gastrointestinal Disorders:** Abdominal pain or discomfort, diarrhea, dry mouth, lip swelling, paraesthesia oral, tongue edema, vomiting; **General Disorders and Administration Site Conditions:** Chest pain or discomfort, chills, malaise; **Immune System Disorders:** Hypersensitivity; **Investigations:** Nonspecific changes in laboratory tests (including hematology, blood chemistry, liver enzymes and urinalysis), blood pressure and electrocardiogram parameters (including PR, QRS and QT intervals and ST-T segment changes). **Musculoskeletal and Connective Tissue Disorders:** Myalgia; **Nervous System Disorders:** Parosmia, tremor; **Respiratory, Thoracic and Mediastinal Disorders:** Dyspnea, laryngospasm, nasal congestion, sneezing, wheezing; **Skin and Subcutaneous Tissue Disorders:** Hyperhidrosis, pruritus, rash, swelling face, urticaria.

Pediatric In clinical trials of MultiHance in MRI of the CNS, 217 pediatric subjects received MultiHance at a dose of 0.1 mmol/kg. A total of 112 (52%) subjects were male and the overall mean age was 8.3 years (range 4 days to 17 years). A total of 168 (77%) subjects were Caucasian, 12 (6%) Black, 12 (6%) Asian, 24 (11%), Hispanic, and 1 (<1%) in other racial groups.

Adverse reactions were reported for 14 (6.5%) of the subjects. The frequency and the nature of the adverse reactions were similar to those seen in the adult patients. The most commonly reported adverse reactions were vomiting (1.4%), pyrexia (0.9%), and hyperhidrosis (0.9%). No subject died during study participation. A serious adverse reaction of worsening of vomiting was reported for one (0.5%) patient with a brain tumor (glioma) for which a causal relationship to MultiHance could not be excluded.

Pediatric Patients in clinical trials of MultiHance in MRI of the CNS, 307 pediatric subjects received MultiHance at a dose of 0.1 mmol/kg. A total of 160 (52%) subjects were male and the overall mean age was 6.0 years (range, 2 days to 17 years). A total of 211 (69%) subjects were Caucasian, 24 (8%) Black, 15 (5%) Asian, 39 (13%), Hispanic, 2 (<1%) in other racial groups, and for 16 (5%), race was not reported. Adverse reactions were reported for 14 (4.6%) of the subjects. The frequency and the nature of the adverse reactions were similar to those seen in the adult patients. The most commonly reported adverse reactions were vomiting (1.0%), pyrexia (0.7%), and hyperhidrosis (0.7%). No subject died during study participation.

6.2 Post-marketing Experience

The following adverse reactions have been identified during post approval use of MultiHance. Because these reactions are reported voluntarily from a population of uncertain size, it is not always possible to reliably estimate their frequency or establish a causal relationship to drug exposure.

Immune System Disorders: Anaphylactic, anaphylactoid and hypersensitivity reactions manifested with various degrees of severity up to anaphylactic shock, loss of consciousness and death. The reactions generally involved signs or symptoms of respiratory, cardiovascular, and/or mucocutaneous abnormalities.

General Disorders and Administration Site Conditions: Extravasation of MultiHance may lead to injection site reactions, characterized by local pain or burning sensation, swelling, blistering, and necrosis [*see Warnings and Precautions (5.4)*]. Adverse events with variable onset and duration have been reported after GBCA administration [*see Warnings and Precautions (5.3)*]. These include fatigue, asthenia, pain syndromes, and heterogeneous clusters of symptoms in the neurological, cutaneous, and musculoskeletal systems.

Skin: Gadolinium associated plaques.

7 DRUG INTERACTIONS

7.1 Transporter-Based Drug-Drug Interactions MultiHance and other drugs may compete for the canalicular multispecific organic anion transporter (MOAT also referred to as MRP2 or ABCC2). Therefore MultiHance may prolong the systemic exposure of drugs such as cisplatin, anthracyclines (e.g. doxorubicin, daunorubicin), vinca alkaloids (e.g. vincristine), methotrexate, etoposide, tamoxifen, and paclitaxel. In particular, consider the potential for prolonged drug exposure in patients with decreased MOAT activity (e.g. Dubin Johnson syndrome).

8 USE IN SPECIFIC POPULATIONS

8.1 Pregnancy Risk Summary GBCAs cross the placenta and result in fetal exposure and gadolinium retention. The human data on the association between GBCAs and adverse fetal outcomes are limited and inconclusive (see Data). In animal reproduction studies, gadobenate dimeglumine has been shown to be teratogenic in rabbits following repeated intravenous administration during organogenesis at doses up to 6 times the recommended human dose. There were no adverse developmental effects observed in rats with intravenous administration of gadobenate dimeglumine during organogenesis at doses up to three times the recommended human dose (see Data). Because of the potential risks of gadolinium to the fetus, use MultiHance only if imaging is essential during pregnancy and cannot be delayed. The estimated background risk of major birth defects and miscarriage for the indicated population is unknown. All pregnancies have a background risk of birth defect, loss, or other adverse outcomes. In the U.S. general population, the estimated background risk of major birth defects and miscarriage in clinically recognized pregnancies is 2 to 4% and is 15 to 20%, respectively. Data *Human Data* Contrast enhancement is visualized in the human placenta and fetal tissues after maternal GBCA administration. Cohort studies and case reports on exposure to GBCAs during pregnancy have not reported a clear association between GBCAs and adverse effects in the exposed neonates. However, a retrospective cohort study comparing pregnant women who had a GBCA MRI to pregnant women who did not have an MRI, reported a higher occurrence of stillbirths and neonatal deaths in the group receiving GBCA MRI. Limitations of this study include a lack of comparison with non-contrast MRI and lack of information about the maternal indication for MRI. Overall, these data preclude a reliable evaluation of the potential risk of adverse fetal outcomes with the use of GBCAs in pregnancy. *Animal Data* Gadolinium Retention GBCAs administered to pregnant non-human primates (0.1 mmol/kg on gestational days 85 and 135) result in measurable gadolinium concentration in the offspring in bone, brain, skin, liver, kidney, and spleen for at least 7 months. GBCAs administered to pregnant mice (2 mmol/kg daily on gestational days 16 through 19) result in measurable gadolinium concentrations in the pups in bone, brain, kidney, liver, blood, muscle, and spleen at one month postnatal age.

Reproductive Toxicology Gadobenate dimeglumine has been shown to be teratogenic in rabbits when administered intravenously at 2 mmol/kg/day (6 times the recommended human dose based on body surface area) during organogenesis (day 6 to 18) inducing microphthalmia/small eye and/or focal retinal fold in 3 fetuses from 3 separate litters. In addition, MultiHance intravenously administered at 3 mmol/kg/day (10 times the recommended human dose based on body surface area) has been shown to increase intrauterine deaths in rabbits. There was no evidence that MultiHance induced teratogenic effects in rats at doses up to 2 mmol/kg/day (3 times the recommended human dose based on body surface area), however, rat dams exhibited no systemic toxicity at this dose. There were no adverse effects on the birth, survival, growth, development and fertility of the F1 generation at doses up to 2 mmol/kg in a rat peri- and post-natal (Segment III) study.

10 OVERDOSAGE

Clinical consequences of overdosage with MultiHance have not been reported. Treatment of an overdosage should be directed toward support of vital functions and prompt institution of symptomatic therapy. In a Phase 1 clinical study, doses up to 0.4 mmol/kg were administered to patients. MultiHance has been shown to be dialyzable (see *Clinical Pharmacology (12.3)*).

12 CLINICAL PHARMACOLOGY

12.1 Mechanism of Action Gadobenate dimeglumine is a paramagnetic agent and, as such, develops a magnetic moment when placed in a magnetic field. The large magnetic moment produced by the paramagnetic agent results in a large local magnetic field, which can enhance the relaxation rates of water protons in its vicinity leading to an increase of signal intensity (brightness) of tissue.

In magnetic resonance imaging (MRI), visualization of normal and pathological tissue depends in part on variations in the radiofrequency signal intensity that occur with 1) differences in proton density; 2) differences of the spin-lattice or longitudinal relaxation times (T1); and 3) differences in the spin-spin or transverse relaxation time (T2). When placed in a magnetic field, gadobenate dimeglumine decreases the T1 and T2 relaxation time in target tissues. At recommended doses, the effect is observed with greatest sensitivity in the T1-weighted sequences.

12.2 Pharmacodynamics Unlike other tested paramagnetic contrast agents (See Table 3), MultiHance demonstrates weak and transient interactions with serum proteins that causes slowing in the molecular tumbling dynamics, resulting in strong increases in relaxivity in solutions containing serum proteins. The improved relaxation effect can contribute to increased contrast-to-noise ratio and lesion-to-brain ratio, which may improve visualization.

TABLE 3: RELAXIVITY ($mM^{-1}s^{-1}$) OF GADOLINIUM CHELATES

	Human plasma	
	r_1	r_2
Gadobenate	9.7[1]	12.5[1]
Gadopentetate	4.9[1]	6.3[1]
Gadodiamide	5.4[1]	—
Gadoteridol	5.4[1]	—

r_1 and r_2 relaxivities indicate the efficiency in shortening T1 and T2 relaxation times, respectively.
[1] In heparinized human plasma, at 37°C.
— Not available

Disruption of the blood-brain barrier or abnormal vascularity allows enhancement by MultiHance of lesions such as neoplasms, abscesses, and infarcts. Uptake of MultiHance into hepatocytes has been demonstrated.

12.3 Pharmacokinetics Three single-dose intravenous studies were conducted in 32 healthy male subjects to assess the pharmacokinetics of gadobenate dimeglumine. The doses administered in these studies ranged from 0.005 to 0.4 mmol/kg. Upon injection, the meglumine salt is completely dissociated from the gadobenate dimeglumine complex. Thus, the pharmacokinetics is based on the assay of gadobenate ion, the MRI contrast effective ion in gadobenate dimeglumine. Data for plasma concentration and area under the curve demonstrated linear dependence on the administered dose. The pharmacokinetics of gadobenate ion following intravenous administration can be best described using a two-compartment model.

Distribution Gadobenate ion has a rapid distribution half-life (reported as mean ± SD) of 0.084 ± 0.012 to 0.605 ± 0.072 hours. Volume of distribution of the central compartment ranged from 0.074 ± 0.017 to 0.158 ± 0.038 L/kg, and estimates of volume of distribution by area ranged from 0.170 ± 0.016 to 0.282 ± 0.079 L/kg. These latter estimates are approximately equivalent to the average volume of extracellular body water in man. *In vitro* studies showed no appreciable binding of gadobenate ion to human serum proteins.

Elimination Gadobenate ion is eliminated predominately via the kidneys, with 78% to 96% of an administered dose recovered in the urine. Total plasma clearance and renal clearance estimates of gadobenate ion were similar, ranging from 0.093 ± 0.010 to 0.133 ± 0.270 L/hr/kg and 0.082 ± 0.007 to 0.104 ± 0.039 L/hr/kg, respectively. The clearance is similar to that of substances that are subject to glomerular filtration. The mean elimination half-life ranged from 1.17 ± 0.26 to 2.02 ± 0.60 hours. A small percentage of the administered dose (0.6% to 4%) is eliminated via the biliary route and recovered in feces.

Metabolism There was no detectable biotransformation of gadobenate ion. Dissociation of gadobenate ion *in vivo* has been shown to be minimal, with less than 1% of the free chelating agent being recovered alone in feces.

Pharmacokinetics in Special Populations

Renal Impairment: A single intravenous dose of 0.2 mmol/kg of MultiHance was administered to 20 subjects with impaired renal function (6 men and 3 women with moderate renal impairment [urine creatinine clearance >30 to <60 mL/min] and 5 men and 6 women with severe renal impairment [urine creatinine clearance >10 to <30 mL/min]). Mean estimates of the elimination half-life were 6.1 ± 3.0 and 9.5 ± 3.1 hours for the moderate and severe renal impairment groups, respectively as compared with 1.0 to 2.0 hours in healthy volunteers.

Hemodialysis: A single intravenous dose of 0.2 mmol/kg of MultiHance was administered to 11 subjects (5 males and 6 females) with end-stage renal disease requiring hemodialysis to determine the pharmacokinetics and dialyzability of gadobenate. Approximately 72% of the dose was recovered by hemodialysis over a 4-hour period. The mean elimination half-life on dialysis was 1.21 ± 0.29 hours as compared with 42.4 ± 24.4 hours when off dialysis.

Hepatic Impairment: A single intravenous dose of 0.1 mmol/kg of MultiHance was administered to 11 subjects (8 males and 3 females) with impaired liver function (Class B or C modified Child-Pugh Classification). Hepatic impairment had little effect on the pharmacokinetics of MultiHance with the parameters being similar to those calculated for healthy subjects.

Gender, Age, Race: A multiple regression analysis performed using pooled data from several pharmacokinetic studies found no significant effect of sex upon the pharmacokinetics of gadobenate. Clearance appeared to decrease slightly with increasing age. Since variations due to age appeared marginal, dosage adjustment for geriatric population is not recommended. Pharmacokinetic differences due to race have not been systematically studied.

Pediatric: A population pharmacokinetic analysis incorporated data from 25 healthy subjects (14 males and 11 females) and 15 subjects undergoing MR imaging of the central nervous system (7 males and 8 females) betweenages of 2 and 16 years. The subjects received a single intravenous dose of 0.1 mmol/kg of MultiHance. The geometric mean Cmax was 62.3 µg/mL (n=16) in children 2 to 5 years of age, and 64.2 µg/mL (n=24) in children older than 5 years. The geometric mean AUC 0-∞ was 77.9 µg·h/mL in children 2-5 years of age (n=16) and 82.6 µg·h/mL in children older than 5 years (n=24). The geometric mean half-life was 1.2 hours in children 2 to 5 years of age and 0.93 hours in children older than 5 years. There was no significant gender-related difference in the pharmacokinetic parameters in the pediatric patients. Over 80% of the dose was recovered in urine after 24 hours. Pharmacokinetic simulations indicate similar AUC and Cmax values for MultiHance in pediatric subjects less than 2 years when compared to those reported for adults; no age-based dose adjustment is necessary for this pediatric population.

17 PATIENT COUNSELING INFORMATION

17.1 Nephrogenic Systemic Fibrosis Instruct patients to inform their physician if they:
• have a history of kidney and/or liver disease, or • have recently received a GBCA.
GBCAs increase the risk for NSF among patients with impaired elimination of the drugs. To counsel patients at risk for NSF: • Describe the clinical manifestations of NSF • Describe procedures to screen for the detection of renal impairment.
Instruct the patients to contact their physician if they develop signs or symptoms of NSF following MultiHance administration, such as burning, itching, swelling, scaling, hardening and tightening of the skin; red or dark patches on the skin; stiffness in joints with trouble moving, bending or straightening the arms, hands, legs or feet; pain in the hip bones or ribs; or muscle weakness.

17.2 Common Adverse Reactions
Inform patients that they may experience:
• reactions along the venous injection site, such as mild and transient burning or pain or feeling of warmth or coldness at the injection site • side effects of feeling hot, nausea, and headache.

17.3 General Precautions
Instruct patients scheduled to receive MultiHance to inform their physician if they:
• are pregnant or breast feeding • have a history of renal disease, heart disease, seizure, asthma or allergic respiratory diseases • are taking any medications • have any allergies to any of the ingredients of MultiHance.

Rx only US Patent No. 4,916,246 Manufactured for Bracco Diagnostics Inc. Monroe Township, NJ 08831 By Patheon Italia S.p.A. - 03013 Ferentino (Italy) Revised October 2018 18-061418B

[1]Multicenter double-blind randomized intraindividual crossover study design of 123 patients with known or suspected brain tumors. Each patient received 0.1-mmol/kg doses of MultiHance and Gadavist in 2 identical MR imaging examinations. Contrast agents were administered by IV using manual bolus injection (n=118) or a power injector (n=4). Both agents were administered at 0.1 mmol/kg of body weight, corresponding to 0.2 mL/kg for MultiHance and 0.1 mL/kg for Gadavist. The interval between the 2 MR imaging examinations was >48 hours to avoid carryover effects but <14 days to minimize the chance of measurable disease progression or lesion evolution. All images were evaluated by 3 blinded, independent experienced radiologists who were unaffiliated with the study centers. Each reader evaluated the patient images separately and independently. Images were evaluated qualitatively for diagnostic information and scored for: 1) lesion border delineation, 2) disease extent, 3) visualization of lesion internal morphology, and 4) lesion contrast enhancement compared with surrounding normal tissue. All assessments used a 3-point scales from 1 (examination 1 superior) through 0 (examinations equal) to 1 (examination 2 superior).

Gadavist® (gadobutrol) is a registered trademark of Bayer Healthcare. **Reference:** Seidl Z, Vymazal J, Mechl M, et al. Does higher gadolinium concentration play a role in the morphologic assessment of brain tumors? Results of a multicenter intraindividual crossover comparison of gadobutrol versus gadobenate dimeglumine (the MERIT Study). *AJNR Am J Neuroradiol*. 2012 Jun-Jul;33(6):1050–1058.

AppliedRadiology® 50 YEARS
The Journal of Practical Medical Imaging and Management

Anderson Publishing, Ltd
180 Glenside Avenue,
Scotch Plains, NJ 07076
Tel: 908-301-1995
Fax: 908-301-1997
info@appliedradiology.com

PRESIDENT & CEO
Oliver Anderson

GROUP PUBLISHER
Kieran N Anderson

ASSOCIATE PUBLISHER
Cristine Funke, RT(R)

EXECUTIVE EDITOR
Joseph F Jalkiewicz

PRODUCTION
Barbara A Shopiro

CIRCULATION DIRECTOR
Cindy Cardinal

EDITORS EMERITI
Theodore E Keats, MD
Stuart E Mirvis, MD, FACR

Editorial Advisory Board

EDITOR-IN-CHIEF
Erin Simon Schwartz, MD, FACR
Perelman School of Medicine, University of Pennsylvania, The Children's Hospital of Philadelphia, Philadelphia, PA

ASSOCIATE EDITOR FOR RADIOLOGICAL CASES
Kristin K Porter, MD, PhD
The Kirklin Clinic of UAB Hospital, Birmingham, AL

ADVOCACY/GOVERNMENTAL AFFAIRS
Associate Editor
David Youmans, MD, FACR
Princeton Radiology Associates, Princeton, NJ

Seth Hardy, MD, MBA, FACR
Penn State Health, Milton S Hershey Medical Center, Hershey, PA

Ryan K Lee, MD, MBA
Einstein Healthcare Network, Philadelphia, PA

Pradnya Y Mhatre, MD, MRMD(MRSC)Emory University School of Medicine Atlanta, GA

ARTIFICIAL INTELLIGENCE
Associate Editor
Lawrence N Tanenbaum, MD, FACR
RadNet, Inc, New York, NY

Suzie Bash, MD
San Fernando Interventional Radiology, RadNet, Inc, Los Angeles, CA

Amine Korchi, MD, FMH
Imaging Center Onex–Groupe 3R, Singularity Consulting & Ventures, Geneva, Switzerland

BODY IMAGING
Elliot K Fishman, MD
Johns Hopkins Hospital, Baltimore, MD

Yasha Parikh Gupta, MD
Mount Auburn Hospital
Cambridge, MA

BREAST IMAGING
Huong Le-Petross, MD, FRCPC, FSBI
University of Texas MD Anderson Cancer Center Houston, TX

Kemi Babagbemi, MD
Weill Cornell Imaging at New York Presbyterian New York, NY

Nina S Vincoff, MD
Donald and Barbara Zucker School of Medicine at Hofstra/Northwell, Hofstra University, Hempstead, NY

CARDIOPULMONARY IMAGING
Associate Editor
Charles S White, MD
University of Maryland School of Medicine, Baltimore, MD

Jeanne B Ackman, MD
Massachusetts General Hospital, Boston, MA

Saurabh Jha, MBBS, MRCS, MS
Perelman School of Medicine, University of Pennsylvania, Philadelphia, PA

EMERGENCY RADIOLOGY
Associate Editor
Melissa Davis, MD, MBA
Emory University School of Medicine, Atlanta, GA

Vahe M Zohrabian, MD
Donald and Barbara Zucker School of Medicine at Hofstra/Northwell, Hofstra University, Hempstead, NY

ENTERPRISE IMAGING
Christine Harris, RT(R)(MR), MRSO
Jefferson University Hospitals, Philadelphia, PA

Rasu Shrestha, MD, MBA
Atrium Health, Charlotte, NC

Eliot Siegel, MD
VA Maryland Healthcare System, University of Maryland School of Medicine, Baltimore, MD

INTERVENTIONAL RADIOLOGY
Associate Editor
Jeffrey C Hellinger, MD, MBA
Lenox Hill Radiology, New York, NY

Minhaj S Khaja, MD, MBA
University of Virginia Health System, Charlottesville, VA

MEDICAL INDUSTRY
Sonia Gupta, MD
University of South Florida, Tampa, FL

Ronald B Schilling, PhD
RBS Consulting Group, Los Altos Hills, CA

MEDICAL PHYSICS
David W Jordan, PhD, FAAPM
Case Western Reserve University, Cleveland, OH

Rebecca M Marsh, PhD
University of Colorado School of Medicine, Boulder, CO

William Sensakovic, PhD
Mayo Clinic, Phoenix, Arizona

MEDICOLEGAL
Michael M Raskin, MD, MPH, JD
University Medical Center, Tamarac, FL

MUSCULOSKELETAL IMAGING
Thomas Lee Pope, Jr, MD, FACR
Envision Healthcare, Denver, CO

Jamshid Tehranzadeh, MD
University of California Medical Center, Orange, CA

NEURORADIOLOGY
Associate Editor
Wende N Gibbs, MD
Mayo Clinic, Phoenix, AZ

Blake A Johnson, MD, FACR
Center for Diagnostic Imaging, Minneapolis, MN

C Douglas Phillips, MD, FACR
Weill Cornell Medical College/ New York-Presbyterian Hospital, New York, NY

NUCLEAR MEDICINE
Wengen Chen, MD, PhD
University of Maryland Medical Center, Baltimore, MD

K Elizabeth Hawk, MS, MD, PhD
Stanford University School of Medicine, Radiology Partners, Los Angeles, CA

PEDIATRIC RADIOLOGY
Associate Editor
Alexander Towbin, MD
Cincinnati Children's Hospital Medical Center, Cincinnati, OH

Maddy Artunduaga, MD
UT Southwestern Medical Center
Dallas, TX

Michael L Francavilla, MD
Perelman School of Medicine, University of Pennsylvania, The Children's Hospital of Philadelphia, Philadelphia, PA

Marilyn J Siegel, MD, FACR
Washington University School of Medicine, Mallinckrodt Institute of Radiology, St. Louis, MO

ULTRASOUND
John P McGahan, MD, FACR
University of California, Davis, CA

©2022 Anderson Publishing, Ltd. All rights reserved. Reproduction in whole or part without written permission is strictly prohibited. USPS: 0943-180

Applied Radiology®

The Journal of Practical Medical Imaging and Management

March / April 2022
Vol 51 No 2

7 **Imaging Upper Extremity Injuries in Pediatric Athletes**
Jonathan R Wood, MD; Ghazal Shadmani, MD; Marilyn J Siegel, MD

While many sports injuries in young athletes are similar to those in adults, several are distinct. In the skeletally immature population, the weakest areas of the skeleton are the cartilaginous physes of the epiphyses and apophyses, followed by the bones and the ligaments. This activity focuses on the imaging of common acute and chronic sports-related upper-extremity injuries in pediatric athletes.

SA-CME

15 **Blind Spots in Spine Imaging**
Mougnyan Cox, MD; Linda Bagley, MD; Joseph Philip, MD; Joshua Thatcher, MD; Ike Thacker, MD; Conan Gomez; Kennith Layton, MD

Burgeoning spine imaging volumes and the sustained attention required for level-by-level-analysis of degenerative changes creates a unique environment for extraspinal findings to go undetected by a busy radiologist. In this article, we provide an image-rich guide of some common blind spots in spine imaging.

28 **Developing Breast Imaging Services in Low-Resource Settings**
Erica B Pollack, MD; Genevieve Abbey, MD; Patricia DuCharme, MSN, RN, ANP-BC; et al

In a typical breast imaging practice in a high-resource setting, the majority of cancers are diagnosed as stage 0 or stage I, with a 90% cure rate, having benefited from state-of-the-art tools for image-guided detection and diagnosis. In medically underserved regions, however, this is not the norm. This article describes the approach taken by RAD-AID International to improve worldwide access to breast care.

EDITORIAL

5 New Beginnings
Erin Simon Schwartz, MD, FACR

EYE ON AI

24 Going with the (Work)Flow in Radiology
Jonathan Balcombe, MD, and Lawrence N Tanenbaum, MD, FACR

RADIOLOGY MATTERS

33 Imaging Utilization: A Matter of Dollars and Sense
Kerri Reeves

RADIOLOGICAL CASES

36 Differentiating Focal Liver Lesions: ICC and HCC
David S Summerlin, MD; Kristin K Porter, MD, PhD

39 Dural Arteriovenous Fistula
Sherif Moawad, MD; Ahmed Farag, MD; Ahmad Kattan, MD; Mark Buehler, MD

42 Endovascular Retrieval of Transthoracic Right Atrial Catheter Fragment
Lavi Nissim, MD; David J Aria, MD; Scott Willard, MD; Alexander J Towbin, MD; Richard B Towbin, MD

45 Metastatic Neuroblastoma
Amanda L Schaaf; Richard B Towbin, MD; Carrie M. Schaefer, MD; Alexander J. Towbin, MD

WET READ

48 Hand Talkers
C Douglas Phillips, MD, FACR

SEE BONUS CASE AT APPLIEDRADIOLOGY.COM

Pulmonary Sarcomatoid Carcinoma

Fahad Gul, DO; Harris Shaikh, DO; Nicholas Mills, BS; Joseph Pulito, DO; Logan Ranzenberger, DO; Avik Patel, DO; Adeel Khalid, MD; Mohamed Jaber, MD

Applied Radiology (ISSN 0160-9963, USPS 943180) is published in print 6 times a year, January, March, May, July, September, and November, by Anderson Publishing Ltd at 180 Glenside Ave., Scotch Plains NJ 07076. Periodicals postage paid at Scotch Plains, NJ and additional mailing offices. Free subscriptions for US-based qualified radiology professionals. Subscriptions for the US and its territories and possessions: $115 per year, $225 for two years. Foreign and Canadian subscriptions $215 for one year payable in US funds, international money orders, or by credit card only. Postmaster: Please send address changes to Applied Radiology, PO Box 317, Lincolnshire, IL 60069-0317 (847-564-5942) or email AppliedRadiology@Omeda.com.

Dr Schwartz is the Editor-in-Chief of *Applied Radiology*. She is the Chief of the Division of Neuroradiology and holds the Robert A Zimmerman Chair in Pediatric Neuroradiology in the Department of Radiology at The Children's Hospital of Philadelphia. She is also an Associate Professor of Radiology, Perelman School of Medicine, University of Pennsylvania. She can be reached at *erin@appliedradiology.com.*

New Beginnings

Erin Simon Schwartz, MD, FACR

March. Marching along. On the early Roman calendar, March was the first month of the new year. Named for Mars, the Roman god of war, it contains the vernal equinox, the arrival of spring (and my birthday!). New beginnings.

At *Applied Radiology*, we have a new beginning to celebrate. We are thrilled to announce that **Yasha Parikh Gupta, MD,** has joined our body imaging section as the first radiology trainee member of our editorial board. Dr Gupta is the chief resident in the Department of Diagnostic Radiology at the Mount Auburn Hospital, Cambridge, Massachusetts. We know that Dr Gupta will be the first of many trainees to bring a unique perspective to our journal, and we look forward to the collaboration.

Unfortunately, new beginnings are often accompanied by sad endings. I am sorry to report that **Phan T Huynh, MD,** is retiring from our breast imaging section after seven years.

"Dr Phan Huynh joined us in early 2015 following the passing of Ellen Shaw de Paredes, MD, a longtime board member who spearheaded our breast imaging section," said Kieran N Anderson, Vice President & Group Publisher of Anderson Publishing. "Dr. Huynh quickly stepped in and rolled up his sleeves to help us maintain a steady stream of important review articles and case studies supporting those specializing in breast imaging. It has been an honor and a pleasure to work with Dr Huynh these last seven years, and we are incredibly grateful for the impact he's had on *Applied Radiology*." We extend our deepest gratitude for his service.

The tremendous hole that Dr Huynh leaves will be filled by not just one but two new members of our breast imaging section:

- **T Kemi Babagbemi, MD,** assistant professor of clinical radiology, Weill Cornell Medicine New York-Presbyterian Hospital-Weill Cornell Campus, New York, New York; and,
- **Huong (Carisa) T Le-Petross, MD, FRCPC, FBSI**, professor of radiology, University of Texas MD Anderson Cancer Center, Houston, Texas.

Please join me in welcoming Drs Gupta, Babagbemi, and Le-Petross to the *Applied Radiology* family.

You will see that our Global Health Imaging column has been expanded into a review article for this issue. "Developing Breast Imaging Services in the Low-Resource Setting" offers a terrific template for opportunities that radiologists and their partners can implement to improve access to much-needed breast imaging resources around the world.

Indeed, it may serve as a model for other radiology subspecialties to develop their own programs to help address healthcare inequities, which might very well turn into a new beginning for some of our underserved communities.

We know that Dr Gupta will be the first of many trainee members to bring a unique perspective to our journal, and we look forward to the collaboration.

Imaging Upper Extremity Injuries in Pediatric Athletes

Description

Pediatric upper-extremity sports injuries are common. However, the diagnosis can be challenging for radiologists who have limited experience in imaging children. Increased awareness of the imaging findings is critical in establishing the correct diagnosis and ensuring optimal patient management and outcomes. This activity is designed to educate radiologists about the radiographic findings of common acute and chronic sports injuries of the upper extremities in the pediatric population. Mechanisms of injury are also reviewed, as they impact the type of fracture that occurs. Additionally, the role of magnetic resonance imaging in complementing plain radiography is discussed.

Learning Objectives

Upon completing this activity, the reader should be able to:

- Identify acute and chronic sports-related injuries of the upper extremities in pediatric athletes;
- Recognize the causes of sports-related injuries of the upper extremities and their associated injuries; and,
- Apply appropriate selection of MRI for evaluation of sports-related injuries of the upper extremities.

Accreditation/ Designation Statement

This activity has been planned and implemented in accordance with the accreditation requirements and policies of the Accreditation Council for Continuing Medical Education (ACCME) through the joint providership of IAME and Anderson Publishing. IAME is accredited by the ACCME to provide continuing medical education for physicians. IAME designates this activity for a maximum of 1 AMA PRA Category 1 Credits™.

These credits qualify as SA-CME credits.

Authors

Jonathan R Wood, MD;
Ghazal Shadmani, MD;
Marilyn J Siegel, MD

Affiliation: Mallinckrodt Institute of Radiology, Washington University School of Medicine,St. Louis, MO (all authors).

Target Audience

- Radiologists
- Related Imaging Professionals

System Requirements

For assistance accessing this course online or printing a certificate, email CustomerService@AppliedRadiology.org.

Instructions

This activity is designed to be completed within the designated time period. To successfully earn credit, participants must complete the activity during the valid credit period. To receive SA–CME credit, you must:

1. Review this article in its entirety.
2. Visit *www.appliedradiology.org/SAM2*.
3. Log into your account or create an account (new users).
4. Complete the post-test and review the discussion and references.
5. Complete the evaluation.
6. Print your certificate.

Estimated time for completion:
1 hour

Date of release and review:
March 1, 2022
Expiration date: February 29, 2024

Disclosures

Disclosures: Neither the authors, Jonathan R Wood, MD; Ghazal Shadmani, MD; and Marilyn J Siegel, MD, nor Joseph Jalkiewicz, planner of this activity, have any relevant relationships with ineligible companies. No one else at Anderson Publishing or IAME who controlled the content of this activity has relationships with ineligible companies.

SA–CME DETAILS ON PAGE 6

Imaging Upper Extremity Injuries in Pediatric Athletes

Jonathan R Wood, MD; Ghazal Shadmani, MD; Marilyn J Siegel, MD

While many sports injuries in young athletes are similar to those in adults, several are distinct. In the skeletally immature population, the weakest areas of the skeleton are the cartilaginous physes of the epiphyses and apophyses, followed by the bones and the ligaments. As such, the cartilaginous structures are particularly prone to injury.[1-4]

Pediatric athletic injuries include acute traumatic fractures and chronic overuse injuries from repetitive stress. Acute injuries, such as those from direct blows or from falls on outstretched arms, are common among gymnasts, football players and wrestlers. Chronic or repetitive injuries are most common in sports that entail overhead movements, including baseball, football, tennis, and gymnastics.[1,3] Radiography remains the primary imaging modality for evaluating sports-related injuries of the upper extremities. Magnetic resonance imaging (MRI), however, has a role in evaluation where there is a high clinical suspicion of injury but radiographic findings are subtle or non-diagnostic. MRI can also be used to diagnose and guide management of osteochrondral lesions.

This article focuses on the imaging of common acute and chronic sports-related upper-extremity injuries in pediatric athletes.

Affiliation: Mallinckrodt Institute of Radiology, Washington University School of Medicine, St. Louis, MO

Acute and Chronic Injuries of the Shoulder

The shoulder is among the most common sites of acute injury in skeletally immature athletes; physeal fractures of the distal clavicle and the coracoid process are frequent.[1-4] Radiographic evaluation requires at least two orthogonal views, such as true anteroposterior and axillary lateral or scapular lateral views.

Salter-Harris I physeal fractures through the distal clavicle are caused by falling onto an outstretched arm or sustaining a direct blow to the shoulder. Radiographically, these fractures may appear very similar to an acromioclavicular separation. Recognizing these fractures is important because their prognosis is better than a true acromioclavicular separation, which may disrupt the acromioclavicular or coracoclavicular ligaments. Affected patients, typically younger than 13 years, present with acute lateral shoulder pain. Radiographic findings vary with the extent of periosteal disruption, which can range from a minimally displaced periosteal fragment to clavicular displacement in cases involving large tears in the periosteal sleeve.[1,4] The distal clavicular epiphysis is non-displaced and remains in anatomic alignment with the acromion (Figure 1). These fractures usually heal with minimal if any motion limitation following shoulder immobilization.[1,3]

Coracoid fractures involve the physis at the base of the coracoid process. Typically occurring in football players between 13 and 15 years old, these injuries usually result from a direct blow to the shoulder.[5] Radiographic findings include widening of the coracoid physis consistent with a Salter-Harris type I injury (Figure 2). Physeal fractures can be subtle; lateral scapular or Y views or MRI can enhance conspicuity of the physeal widening. Non-displaced fractures are managed conservatively, while displaced fractures may require surgery .

Among chronic repetitive shoulder injuries, “Little League shoulder” is the most common. The term refers to chronic valgus stress injuries in overhead throwers, most often in baseball players ages 11 to 16. Patients typically present with pain in the lateral aspect of the shoulder that worsens with throwing. Widening of the lateral aspect of the proximal

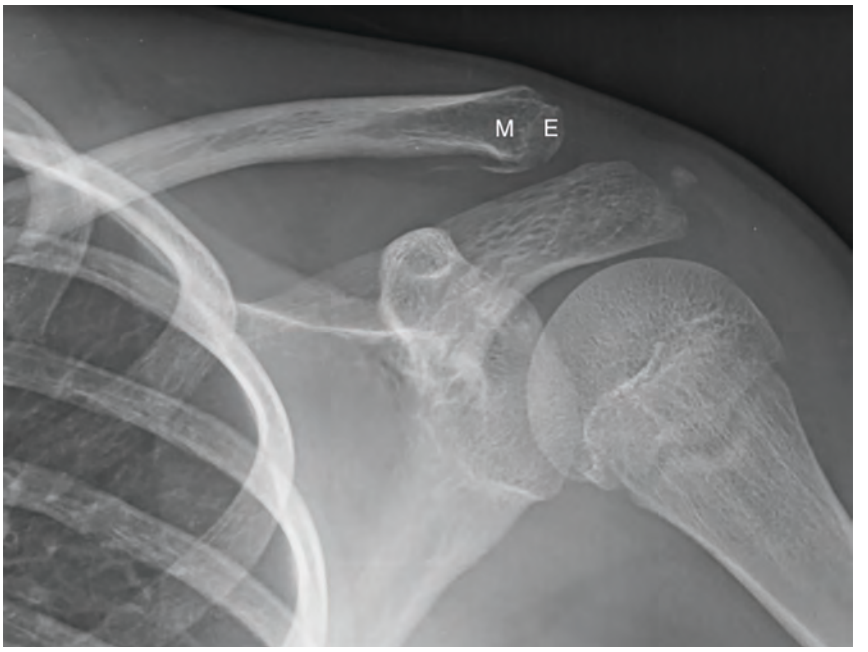

Figure 1. Distal clavicular periosteal sleeve fracture. Anteroposterior (AP) view of the left shoulder in a 15-year-old demonstrates avulsion of the inferior left distal clavicular periosteum (arrows). The metaphysis (M) and epiphysis (E) maintain a normal relationship with the acromion.

Figure 2. Coracoid base fracture in a 14-year-old with right shoulder injury. (A) Right axillary view shows widening of the coracoid physis (arrow) consistent with a Salter-Harris type I injury. (B) Comparison left axillary view shows a normal coracoid physis (curved arrow)

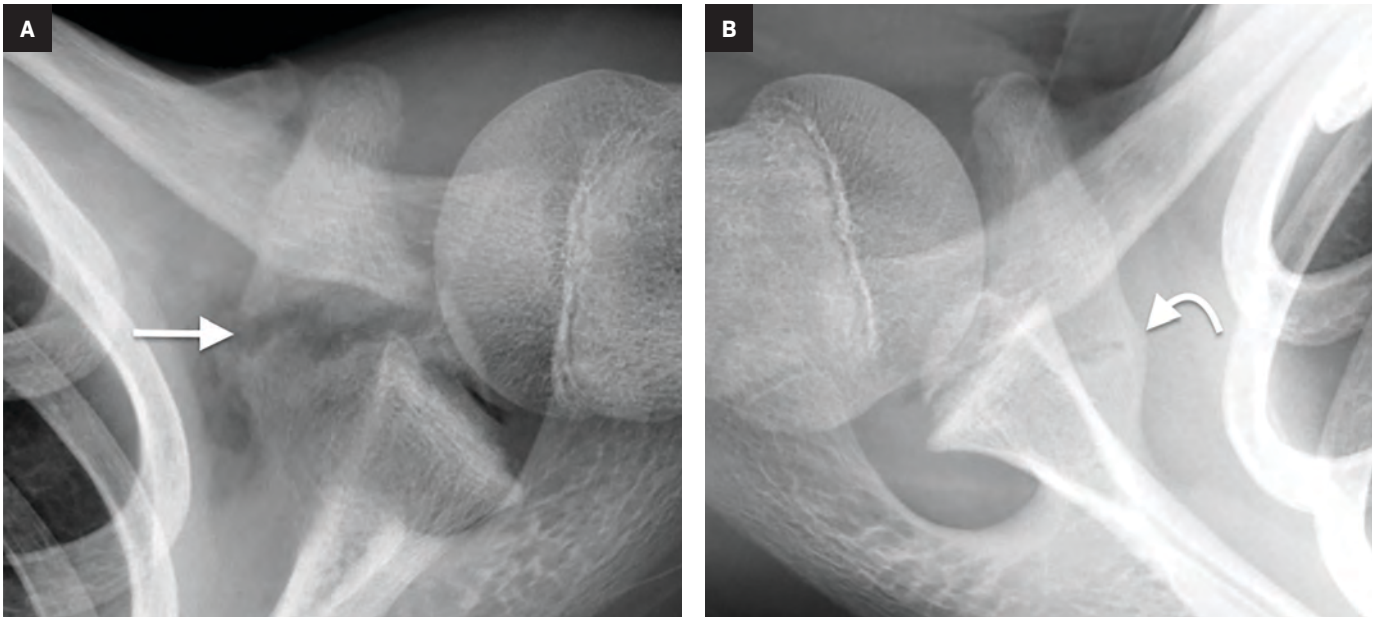

humeral physis is a characteristic radiographic finding, owing to proliferation of the physeal cartilage from chronic repetitive microtrauma (Figure 3).[2-4, 6] The injury is also frequently referred to as a chronic Salter-Harris I fracture. There may be associated metaphyseal sclerosis and cystic change. The prognosis is excellent with early treatment, which consists of temporarily discontinuing throwing. Treatment delay or noncompliance may lead to osseous bridges in the physis that can alter or arrest growth.

Acute and Chronic Injuries of the Elbow

Medial epicondyle and lateral condyle fractures are among the most common acute elbow injuries in young athletes. Two views of the elbow—anteroposterior and lateral—usually suffice for evaluation of these fractures.

Medial epicondyle fractures account for up to 20% of cases. Their mechanism of injury consists of acute valgus stress associated with forearm flexor-pronator muscle contraction, from either overhead throwing or falling on an outstretched arm.[7,8]

Patients, typically 9 to 14 years of age, present with acute pain over the medial aspect of the elbow.[7] Radiographs demonstrate a displaced medial epicondyle with physeal widening (Figure 4). The epicondyle may move into the joint space, resulting in "entrapment" (Figure 5). The entrapped medial epicondyle may be mistaken for a trochlea. Close inspection of the elbow joint is warranted if radiography does not reveal a medial epicondylar apophysis in a child older than 6 or 7 years. Minimally displaced fractures can be treated with rest and immobilization; surgery is required for severely displaced and entrapped fragments.[7]

Lateral condyle fractures usually occur in children 6 to 14 years of age and result from a varus force on an extended elbow with the forearm in supination. Radiographs show a fracture plane through the lateral condyle. They are most commonly considered Salter-Harris IV fractures, although they often appear on radiographs to be Salter-Harris II fractures. They are surgically managed when displaced by greater than 2 mm.

With respect to chronic elbow injuries, the term "Little League elbow" historically has referred to avulsion injuries of the medial epicondyle, but it has been applied more recently to describe injuries at other elbow sites.[8,9] These include the lateral articular surface (capitellum), posterior articular surface (olecranon), and trochlea.[9] Children participating in sports that entail overhead throwing are at higher risk for these injuries, several types of which are described below.

Medial Compartment Injuries

Medial epicondylar apophysitis is the most common repetitive elbow injury. The underlying mechanism is recurrent valgus stress during the acceleration phase of throwing, which leads to traction apophysitis. Patients are typically 11 to 12 years of age and

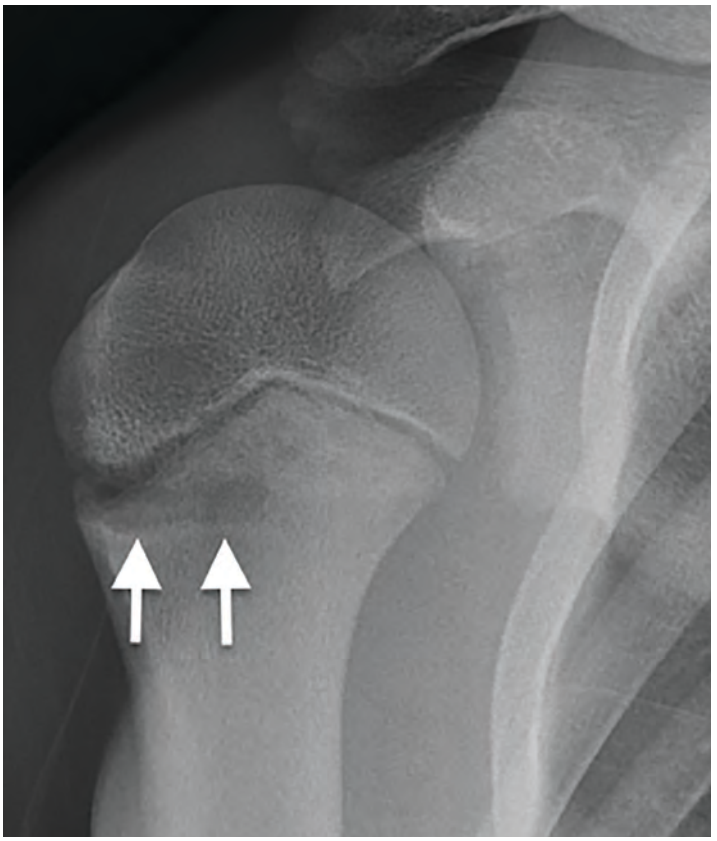

Figure 3. Little League shoulder in a 13-year-old baseball pitcher. AP view of the right shoulder shows widening of the lateral aspect of the proximal humeral physis (arrows) from chronic repetitive microfractures and stress.

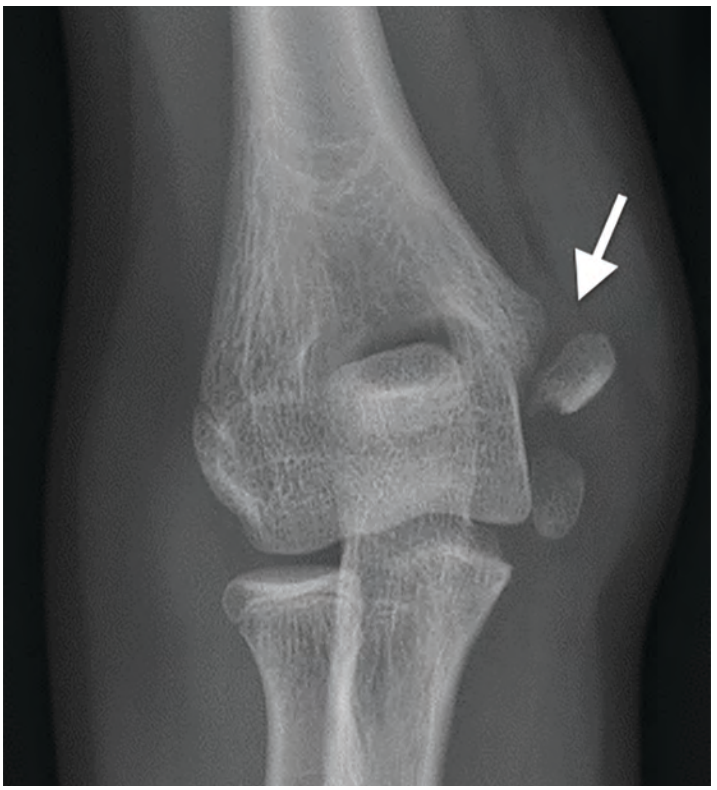

Figure 4. Acute medial epicondyle fracture in a 12-year-old injured while playing soccer. AP radiograph of the elbow shows displaced medial epicondyle avulsion with widening of the physis (arrow). There is also a separate corticated bone fragment distal to the medial epicondyle.

Figure 5. Medial epicondyle fracture with entrapment in the ulnohumeral joint in a 12-year-old injured playing soccer. (A) AP radiograph shows an absent medial epicondylar ossification center at its expected location (star) which is displaced medially within the ulnohumeral joint (arrow). There is lateral dislocation of the elbow at the radiocapitellar and ulnohumeral joints. B: Lateral radiograph obtained after attempted closed reduction and splinting demonstrates entrapment of the ossification center (star) in the ulnohumeral joint. Fracture was subsequently reduced surgically.

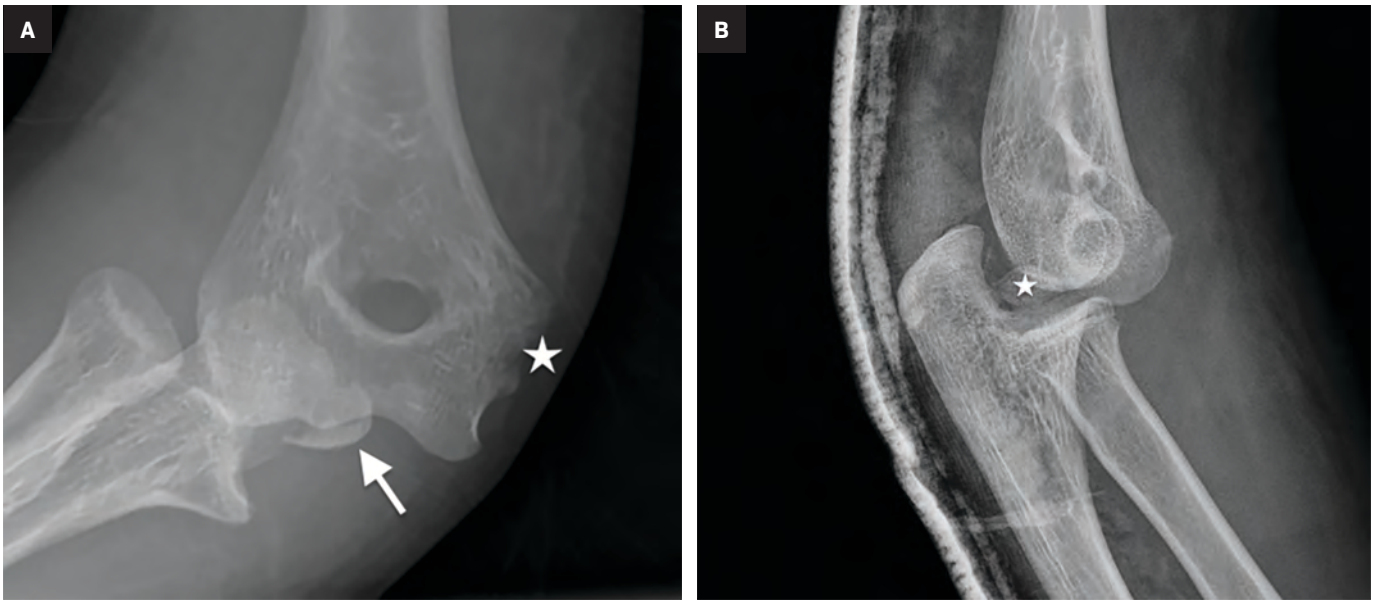

Figure 6. Medial epicondyle apophysitis in a 12-year-old. AP radiograph of the symptomatic right elbow shows subtle widening and irregularity of the medial epicondylar physis (arrow) as well as mild cortical irregularity of the adjacent apophysis.

present with medial elbow pain and tenderness. Radiographic findings include widening of the medial epicondyle physis, representing a chronic Salter-Harris I fracture from physeal microtrauma, and irregularity and sclerosis of the apophysis (Figure 6).[2,9] MRI is more sensitive than radiography for diagnosis; findings consist of physeal widening and increased signal intensity in the epicondyle apophysis, representing marrow edema.[8] Nonunion may result if the lesion is left untreated, but the prognosis is good with joint rest.

Lateral Compartment Injuries

Typically involving the capitellum, lateral compartment injuries include Panner disease and osteochondritis dessicans. They affect different age groups and generally occur in athletes engaged in overhead throwing.[1,2,10] Their mechanism of injury is repetitive lateral compressive forces on the developing capitellum. Symptoms include several weeks of pain and stiffness. Although plain radiographs may demonstrate the lesion, MRI is more sensitive in diagnosing

Figure 7. (A) Panner disease in an 8-year-old with elbow pain. AP radiograph of the elbow shows fragmentation, sclerosis, and irregularity of the capitellum (arrow). (B) Panner disease in a 12-year-old with elbow pain. Coronal fat-suppressed T2 image demonstrates bone marrow edema (star) throughout the capitellum with intact overlying articular cartilage.

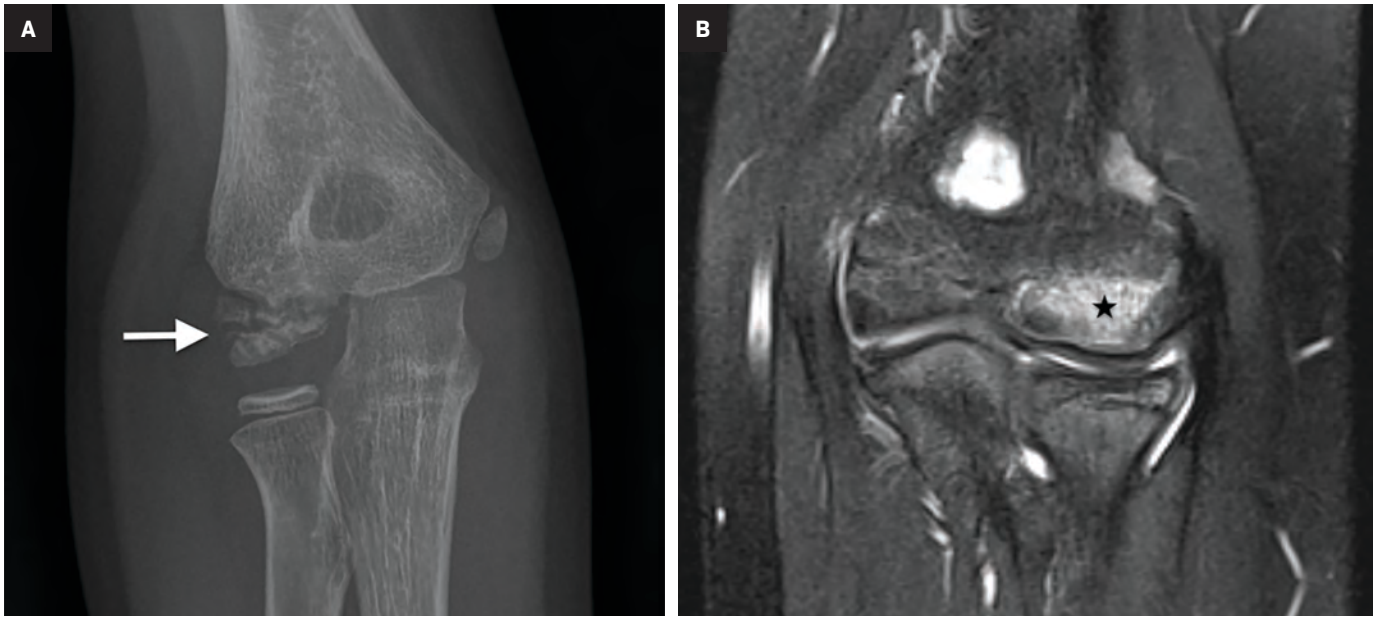

Figure 8. Capitellum osteochondritis dissecans in a 14-year-old gymnast who presented with elbow pain. (A) AP view of the elbow shows subchondral lucency and irregularity of the capitellum (arrow) consistent with an osteochondral lesion. (B) Sagittal fat-suppressed T2 image shows a region of high signal intensity within the capitellum representing marrow edema and a defect in the articular cartilage (arrow), consistent with an unstable lesion. Also noted is joint effusion.

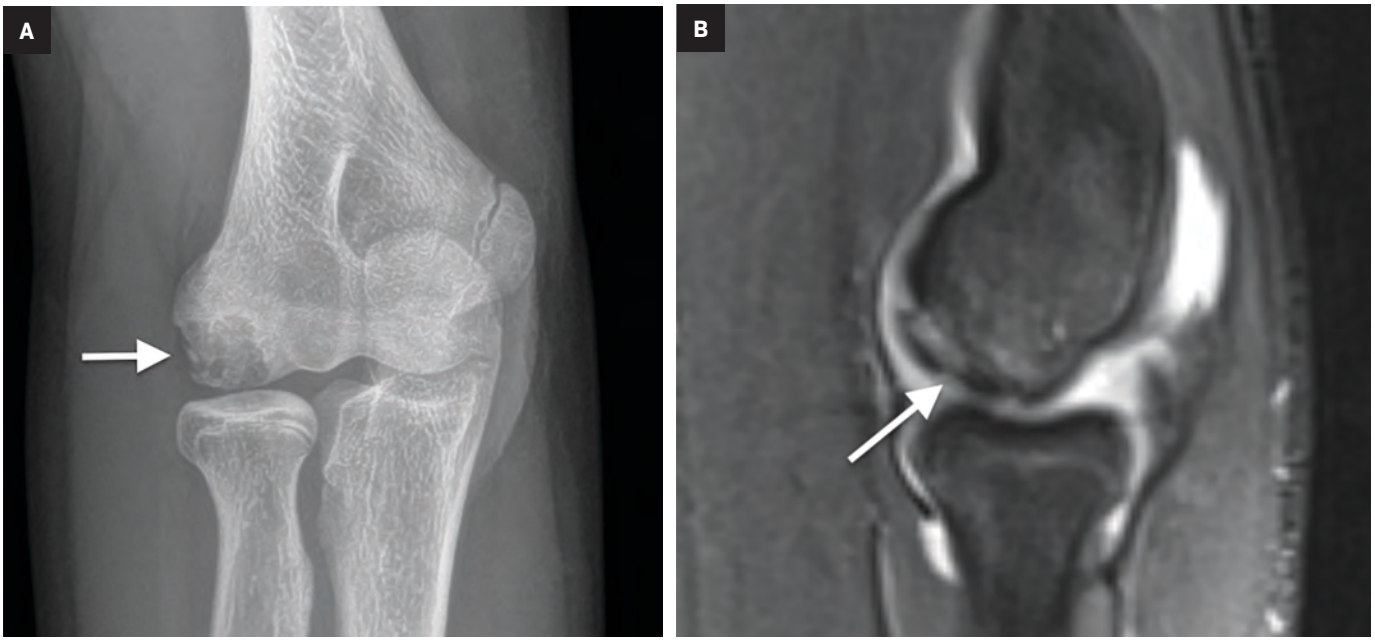

and showing their extent, which can impact management.

Panner disease is a self-limiting osteochondrosis of the capitellar ossification center. Affected athletes are typically younger than 10 years.[8] Radiographs show flattening, sclerosis, and fragmentation of the capitellar epiphysis, with involvement of the entire capitellar ossification center. MRI reveals decreased T1- and increased T2-signal intensity, representing diffuse edema (Figure 7).[8] The overlying cartilaginous surface is unaffected and osteochondral loose body formation does not occur. Treatment consists of immobilization, and the prognosis is excellent, with no residual deformity in most cases.

Osteochondritis dissecans, which typically affects patients older than 11 years, is a disorder in which a segment of articular cartilage

Figure 9. Olecranon apophysitis in a 10-year-old gymnast. (A) Lateral radiograph of right elbow shows subtle widening of the posterior physis (arrow). (B) Sagittal T2 MR image confirms the physeal widening (arrow) and shows associated edema in the apophysis (star).

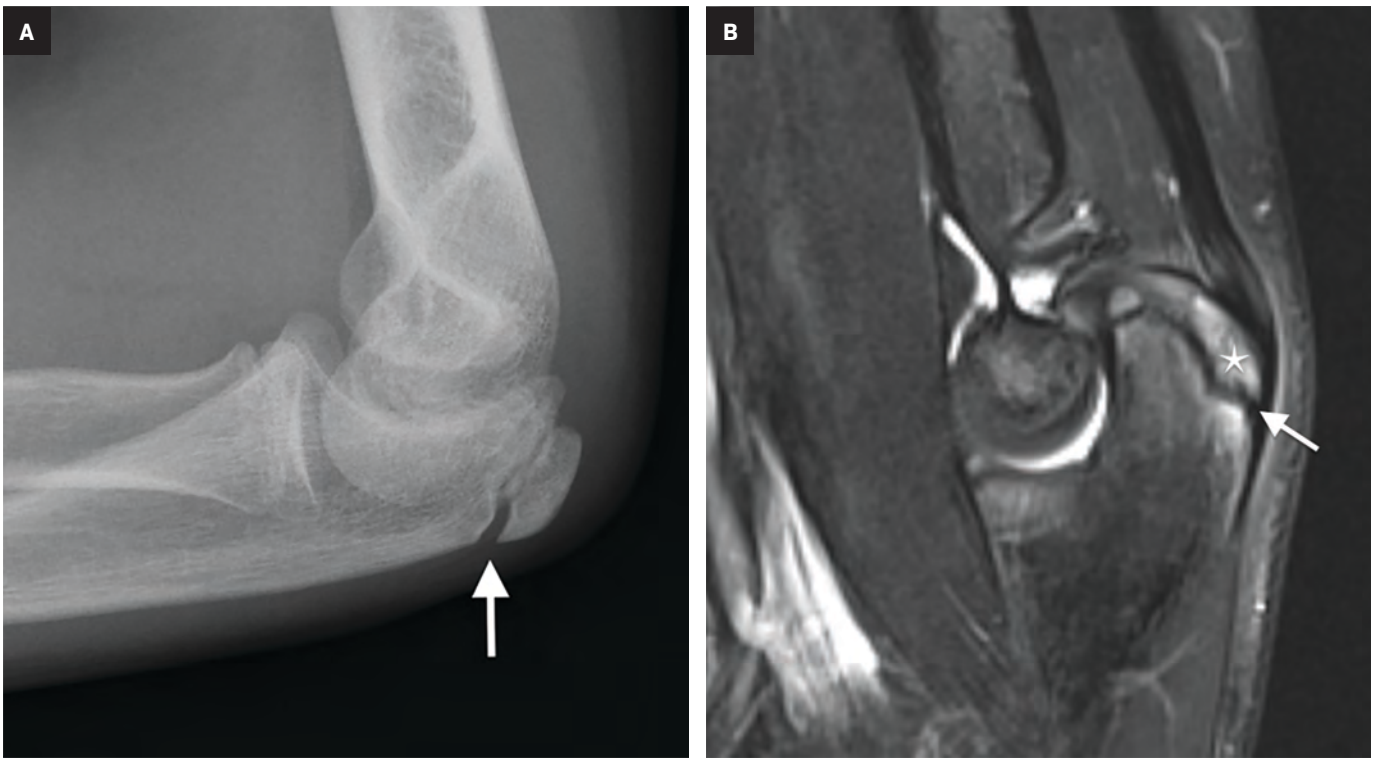

Figure 10. Fishtail deformity in a 15-year-old baseball pitcher who presented with elbow pain and limited flexion. (A) AP radiograph shows a fishtail deformity with a concave defect in the distal humerus (arrow) and elongated and tapered lateral trochlea. There is mild radial subluxation. (B) Coronal fat-suppressed T2 image confirms an elongated lateral trochlea (arrow) and concave defect of the medial trochlea (star) with associated lateral migration of the ulna, resulting in lateral subluxation of the radial head (curved arrow).

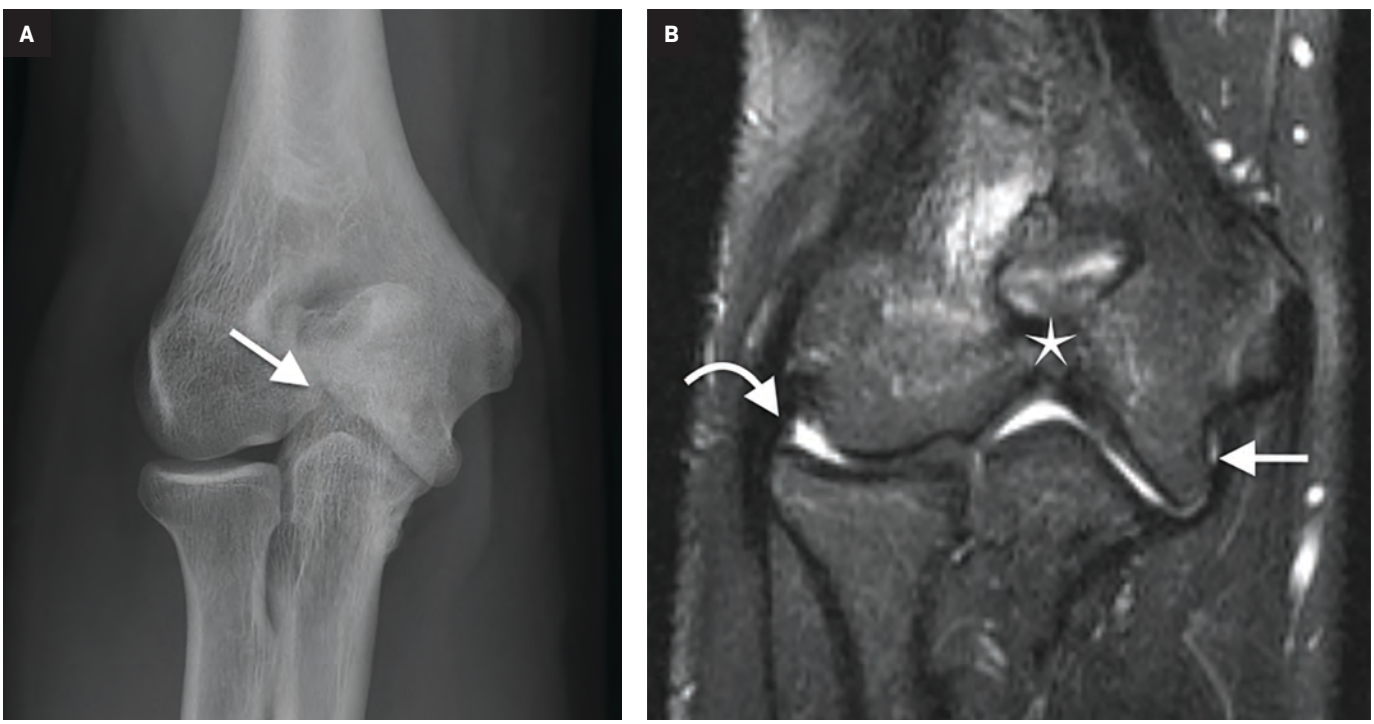

Figure 11. Scaphoid fracture. AP wrist shows a displaced fracture in the scaphoid waist.

Figure 12. Gymnast wrist in a 12-year-old. AP radiograph shows lateral widening and irregularity of the distal radial physis (arrow).

separates from the subchondral bone.[1,2,10] Unlike Panner disease, which involves the entire capitellar epiphysis, this lesion is usually localized to the anterolateral aspect of the ossifying epiphysis. Radiographic findings range from capitellar lucency and flattening in early disease, to capitellar fragmentation and loose bodies in late disease. MRI is the study of choice for confirming the diagnosis and differentiating between stable and unstable lesions. Both types show low T1 and variable T2 subchondral signal intensity. Findings of instability include a rim of high T2 signal intensity between the lesion and the subchondral bone, changes in the overlying cartilage, subchondral bone disruption, and intraarticular bodies(Figure 8).[8] Stable lesions are managed with elbow rest, while unstable lesions may require arthroscopic intervention.[2,8,10]

Posterior Compartment Injuries

Stress injuries of the posterior elbow are relatively uncommon; they usually result from repetitive contraction of the triceps tendon during overhead throwing, leading to traction apophysitis of the olecranon. Radiographic findings are similar to those of medial epicondyle apophysitis and include physeal widening and sclerosis of the olecranon apophysis. MRI findings include physeal widening and abnormally high signal in the olecranon apophysis, representing periphyseal edema (Figure 9). There may also be associated edema in the triceps tendon. The prognosis is good with rest and suspension of throwing.

Trochlear Injuries

Trochlear injuries, typically seen in adolescents, result from overhead throwing motion. They include osteochondritis dissecans and fishtail deformity of the distal humerus, both of which can present with chronic elbow pain and limited motion.[8,11] Radiographic findings of osteochondritis dissecans mimic those of capitellar osteochondritis and include subchondral lucency, sclerosis and fragmentation in the lateral aspect of the trochlea, and loose body formation.[8,11] Lesion stability can be assessed with MRI, and they can be treated similarly to capitellar osteochondritis.

Fishtail deformity of the distal humerus, a late complication of distal humeral fractures, is uncommon. This injury is thought to result from post-traumatic avascular necrosis of the trochlear cartilage.[12] Clinical findings include limited motion, stiffness, and pain related to associated synovitis, osteoarthritis, loose bodies, and cubitus valgus deformity.

Radiographs show a wedge-shaped or concave defect in the distal humerus with elongation and underdevelopment of the lateral trochlea, giving rise to a fishtail or chevron-like deformity (Figure 10). Additional findings include changes of osteoarthritis (joint space narrowing, osteophyte formation, and subchondral cystic changes), migration of the ulna, and radial subluxation.[12] MR imaging can

be useful to determine the extent of osseous and cartilaginous abnormalities (Figure 10). Treatment includes rest and arthroscopic debridement.

Acute and Chronic Injuries of the Wrist and Fingers

Buckle, complete, and Salter-Harris fractures of the distal radial metaphysis are common acute wrist fractures in pediatric athletes. They typically occur from a fall on a hyperextended wrist; skaters and soccer players are at a higher risk for these injuries. Distal radial fractures typically heal with immobilization. The scaphoid is the most commonly injured carpal bone.[2] Mechanisms of injury include a direct blow or a fall on an outstretched hand. Fractures occur most frequently in the scaphoid waist and less often in the proximal or distal poles (Figure 11).[13] Casting results in a 90% union rate.

Stress injuries of the distal radial physis, often referred to as "gymnast wrist," are common chronic injuries among gymnasts and weightlifters between 12 and 14 years of age. The mechanism of injury is repetitive trauma to the distal radius in wrist extension.[1] Radiographs show distal radial physeal widening, corresponding to a Salter-Harris I fracture, and associated metaphyseal irregularity and sclerosis (Figure 12). Prognosis is good with immobilization, but continued repetitive stress may cause bridging or a bony bar and premature closure of the distal radial physis, resulting in relative ulnar lengthening. MR imaging is preferred for evaluating physeal bridging or a bony bar.

Repetitive phalangeal flexion and extension in rock climbing can cause Salter-Harris II or III fractures of the bases of the middle phalanges of the third or fourth digits.[1,4]

Conclusion

Sports injuries in young athletes typically involve the cartilaginous physes of the shoulder, elbow, and wrist, which are the weakest parts of the musculoskeletal system. Conventional radiography is the modality of choice for diagnosing most of these injuries, but MRI can be valuable in diagnosing subtle lesions and assessing signs of instability in osteochondral defects.

References

1) Delgado J, Jaramillo D, Chauvin NA. Imaging the injured pediatric athlete: upper extremity. *Radiographics*. 2016; 36:1672–1687.

2) Emery KH. Imaging of sports injuries of the upper extremity in children. *Clin Sports Med*. 2006; 25:543–568.

3) Lomasney LM, Lim-Dunham JE, Cappello T, Annes J. Imaging of the pediatric athlete: use and overuse. *Radiol Clin North Am*. 2013; 51:215–226.

4) Paz DA, Chang GH, Yetto MJ, et al. Upper extremity overuse injuries in pediatric athletes: clinical presentation, imaging findings and treatment. *Clin Imaging*. 2015; 39:954-964.

5) Cross GWV, Reilly P, Khanna M. Salter-Harris Type I coracoid process fracture in a rugby playing adolescent. *BJR Case Rep*. 2018:20180011.

6) Carson WG, Gasser SI. Little Leaguer's Shoulder. A report of 23 cases. *Am J Sports Med*. 1998;26:575–580.

7) Gottschalk HP, Eisner E, Hosalkar HS. Medial epicondyle fractures in the pediatric population. *J Am Acad Orthop Surg*. 2012;20:223–232.

8) Wong TT, Lin DJ, Ayyala RS, Kazam JK. Elbow injuries in pediatric overhead athletes. *AJR*. 2017: 209:849-859.S

9) Dwek JR, Chung CB. A systematic method for evaluation of pediatric sports injuries of the elbow. *Pediatr Radiol*. 2013;43:120–128.

10) Van Bergen CJA, Van den Ende KIM, Brinke BT, Eygendaal D. Osteochondritis dissecans of the capitellum in adolescents. *WJO*. 2016;7:102-108

11) Marshall KW, Marshall DL, Busch MT, Williams JP. Osteochondral lesions of the humeral trochlea in the young athlete. *Skeletal Radiol*. 2009;38:479–941.

12) Narayanhan S Shailam R, Grottkau BE, Nimkin K. Fishtail deformity – a delayed complication of distal humeral fractures in children. *Pediatr Radiol*. 2015; 45:814-819.

13) Gholson JJ, Bae DS, Zurakowski D, Waters PM. Scaphoid fractures in children and adolescents: contemporary injury patterns and factors influencing time to union. *J Bone Joint Surg AM*. 2011; 93:1210–1219.

Blind Spots in Spine Imaging

Mougnyan Cox, MD; Linda Bagley, MD; Joseph Philip, MD; Joshua Thatcher, MD; Ike Thacker, MD; Conan Gomez; Kennith Layton, MD

Spine-imaging volumes are increasing, paralleling the rising number of aging Americans seeking care for back and neck pain.[1] The most common reason for nontraumatic outpatient spine imaging remains osteoarthritis, which is more common in older patients.[2] In addition, the sustained attention required for level-by-level-analysis of degenerative changes creates a unique environment for extraspinal findings to go undetected by a busy radiologist.

Anecdotally, the potential for diagnostic error is affected by several factors, including the complexity of the diagnostic imaging study, the presence of one or more abnormalities, the expertise of the interpreting physician, the number and type of interruptions, and even the timing of interpretation (early versus late into a work shift). For example, at least one study has shown that errors are more likely to be made in the last two hours of a long shift.[3] Multiple studies in radiology have also found that detection errors are more common than interpretive errors.[4-6] This is especially relevant to spine imaging, where differential diagnoses for perceived abnormalities tend to be less complex than those for brain imaging. Occasionally, an extraspinal finding may be more serious than the original study indication, making detection even more important. In this article, we provide guide to some common "blind spots" in spinal imaging.

Affiliations: Baylor University Medical Center, Dallas, Texas (Drs Cox, Philip, Thatcher, Thacker, Gomez, Layton); Hospital of the University of Pennsylvania, Philadelphia, Pennsylvania (Dr Bagley). Disclosures: None

The Importance of Scout Images

Any interpretation of an imaging study should begin with a careful review of the scout or localizer images, which have been shown to include diagnostic information not included elsewhere in the imaging study.[7] Radiologists have been sued for missing information on scout images that went unidentified on the initial interpretation.[8,9] Scout images may demonstrate important pathology not included on the cross-sectional computed tomography (CT) or magnetic resonance images (MRI) (Figure 1).

A typical scout tomogram/localizer for a cervical spine exam will often provide at least one view of a portion of the lungs, heart, clavicles, and humeri. Occasionally, lung pathology or mediastinal masses may be visible on the scout tomogram but not present on the cross-sectional CT images. Similarly, a fracture (pathologic or otherwise) or other lesion of the humerus may be visible only on the scout tomogram. The lungs and posterior mediastinum also feature prominently in images of the thoracic spine.

The lumbar spine scout tomogram is particularly challenging because it usually provides an anteroposterior view of both hips. Patients with back pain and spinal degenerative changes also frequently have hip pathology, some of which may be severe (Figure 2). Even a cursory review of the hips on lumbar scout tomograms is occasionally high yield. Incorporating a review of the scout and localizer images into the interpretive process will make detection of such abnormalities more likely.

Vascular Abnormalities

Vascular abnormalities can be a significant source of morbidity and mortality; some can be mitigated or even prevented by early detection and treatment. One of the most common serious abnormalities on a cervical spine study is dissection of the vertebral artery. It is not uncommon for patients with a vertebral artery dissection to present with neck pain, a frequent complaint in patients with musculoskeletal disorders of the neck. The dissection may be pre-existing and exacerbated by chiropractic manipulation,[10] or it potentially may

Figure 1. Two elderly patients who had fallen. Scout CT tomogram (A) of the cervical spine shows acute fracture of the right humeral neck (arrow). Scout CT tomogram (B) of the cervical spine shows a right shoulder dislocation (arrow). Both images illustrate how sizeable lung masses and humeral osseous tumors may also be missed if scout tomograms are not reviewed.

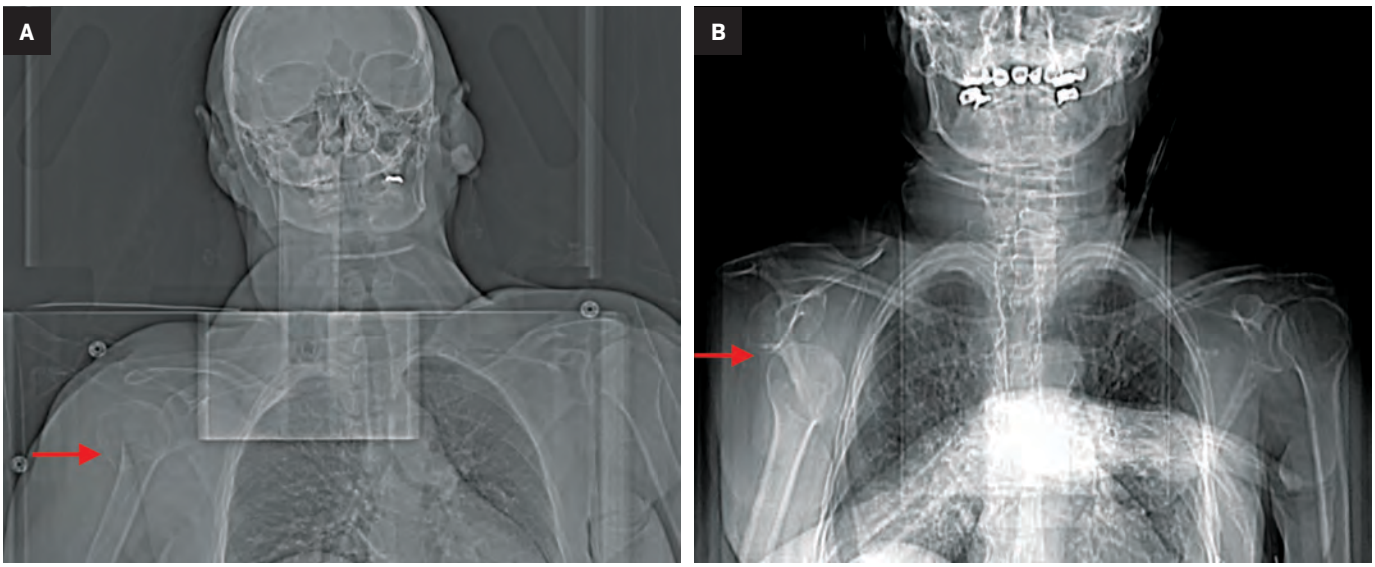

Figure 2. Hip pathology. Scout CT tomogram (A) of the lumbar spine shows a right hip fracture (arrow) in an elderly patient with back pain and prior vertebral augmentation. Scout CT tomogram (B) of the lumbar spine shows advanced degenerative changes and avascular necrosis of the left femoral head (arrow) in a middle-aged patient with low back pain.

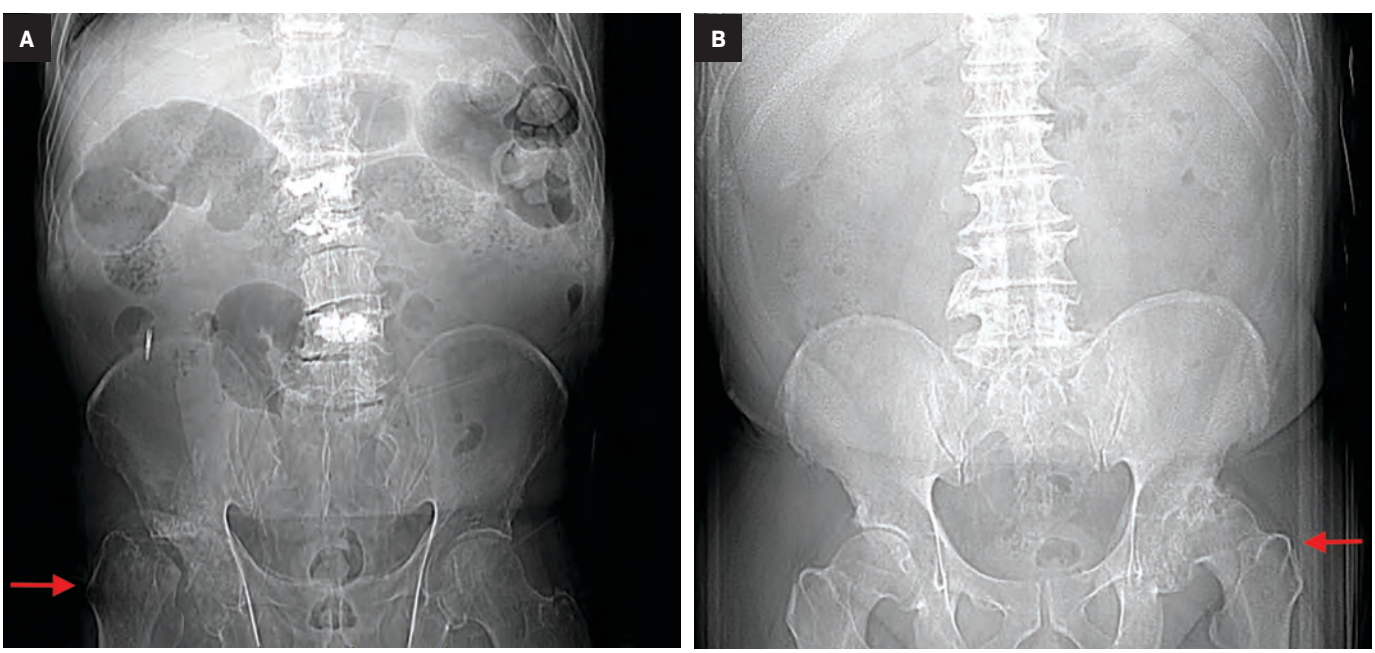

be the inciting event in patients with vascular fragility syndromes such as fibromuscular dysplasia.

Abnormal vertebral artery flow void on MRI can be a clue to, but not diagnostic of, a vertebral artery dissection (Figure 3), as the artery may be congenitally small or chronically occluded. Posterior circulation infarctions seen at the edge of the field of view on sagittal T2 images of the cervical spine increase the likelihood that the vertebral artery abnormality is real. Protocols with T1 images may also show hyperintense T1 signal from subacute intraluminal thrombus. Vertebral artery dissections are an important cause of neck pain, particularly in younger patients.[11] Early treatment with antithrombotic therapy may promote healing and prevent thromboembolism and posterior circulation ischemia/infarction. Anatomic variants that are not inherently dangerous may become important to recognize prior to surgery or other intervention

Figure 3. Middle-aged patient with neck pain. Axial T2 image (A) shows loss of the expected right vertebral artery flow void with central T2 hyperintensity in the larger of the two lumens (arrow). Subsequent computed tomography angiogram of the neck (B) confirms a right vertebral artery dissection and near-occlusion of the larger lumen (arrow).

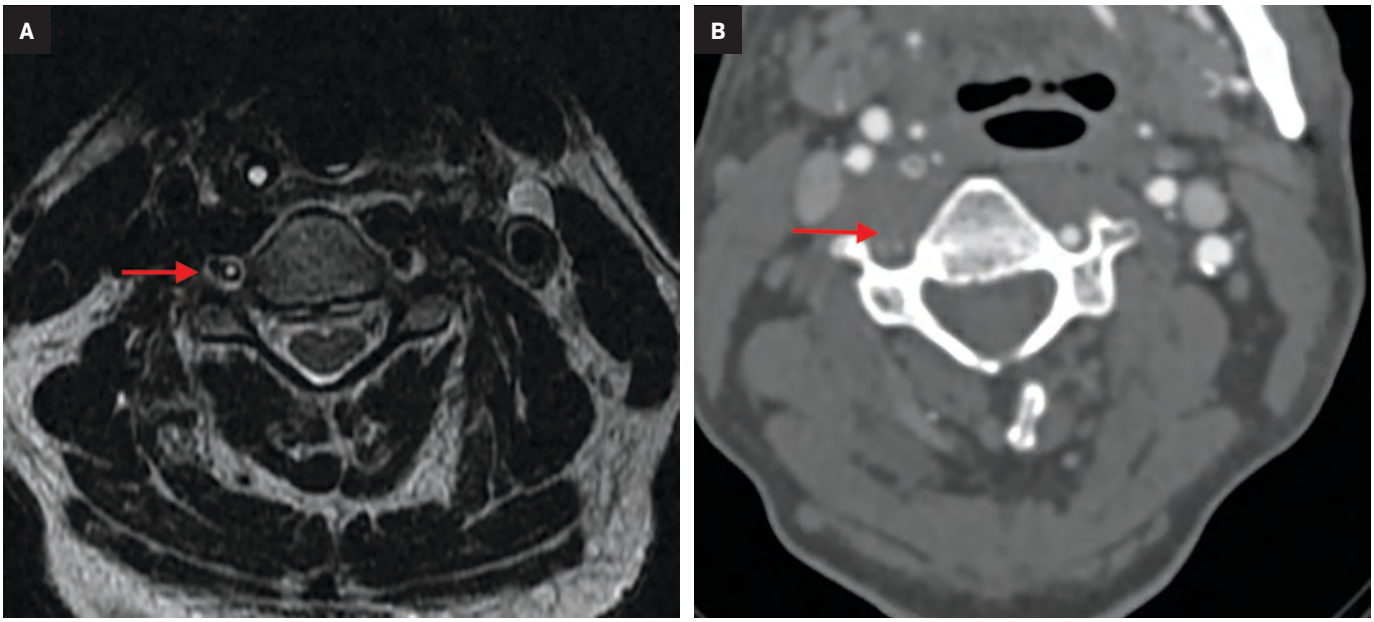

Figure 4. Older patient with neck pain. Sagittal T2 image (A) shows spondylosis with marked canal stenosis, spinal cord impingement, and spinal cord signal abnormality (arrow). Axial noncontrast CT (B) demonstrates medial deviation of the dominant left vertebral artery at the level of anticipated decompression surgery with corresponding enlarged vascular groove (arrow). Calling attention to this preoperatively may reduce the chance of vertebral artery injury. Catheter angiography (C) confirms focal tortuosity of the left vertebral artery (arrow).

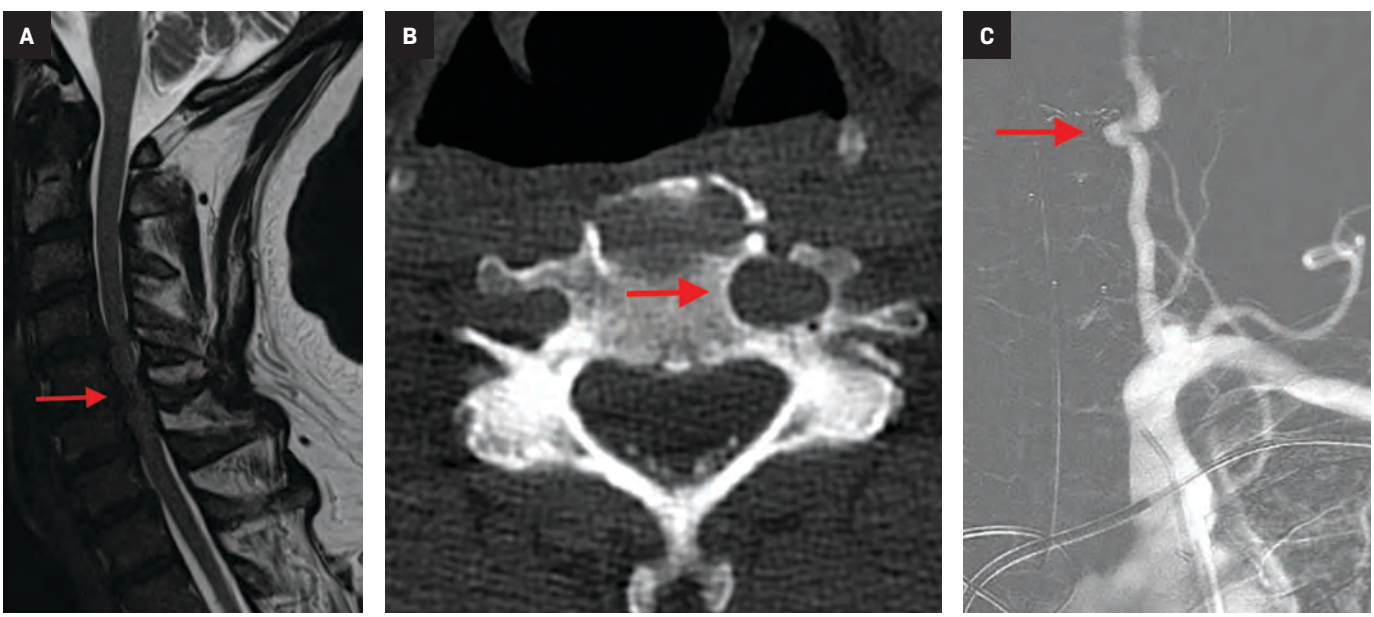

that may place the artery at risk for injury (Figure 4).

Abnormalities of the aorta are a primary concern when imaging the thoracolumbar spine. Mycotic aneurysms and thoracic aorta dissections may coexist where destructive discitis-osteomyelitis dominates clinical and imaging findings (Figure 5). Abdominal aortic and aorto-iliac aneurysms and stenoses are not uncommon in patients over age 65, particularly those with a smoking history, and they may be first discovered at spine imaging.[11] Aorto-iliac occlusion or insufficiency may also present with lower-extremity weakness and urinary incontinence and/or retention, clinically mimicking a compressive myelopathy (Figure 6). Owing to the substantial morbidity associated with undiagnosed abnormalities of the vessel, the thoracoabdominal aorta should be included on

Figure 5. Middle-aged patient with discitis-osteomyelitis and an infected abdominal aortic aneurysm. Sagittal T1 image (A) shows abnormal marrow signal and destruction of the L3-L4 disc space and adjoining endplates (arrow), with a focal bulge of the abdominal aorta immediately adjacent to the area of signal abnormality. Contrast-enhanced CT of the abdomen and pelvis (B) showed a focal irregular abdominal aortic aneurysm with a 'draped' appearance of the bulging region (arrow).

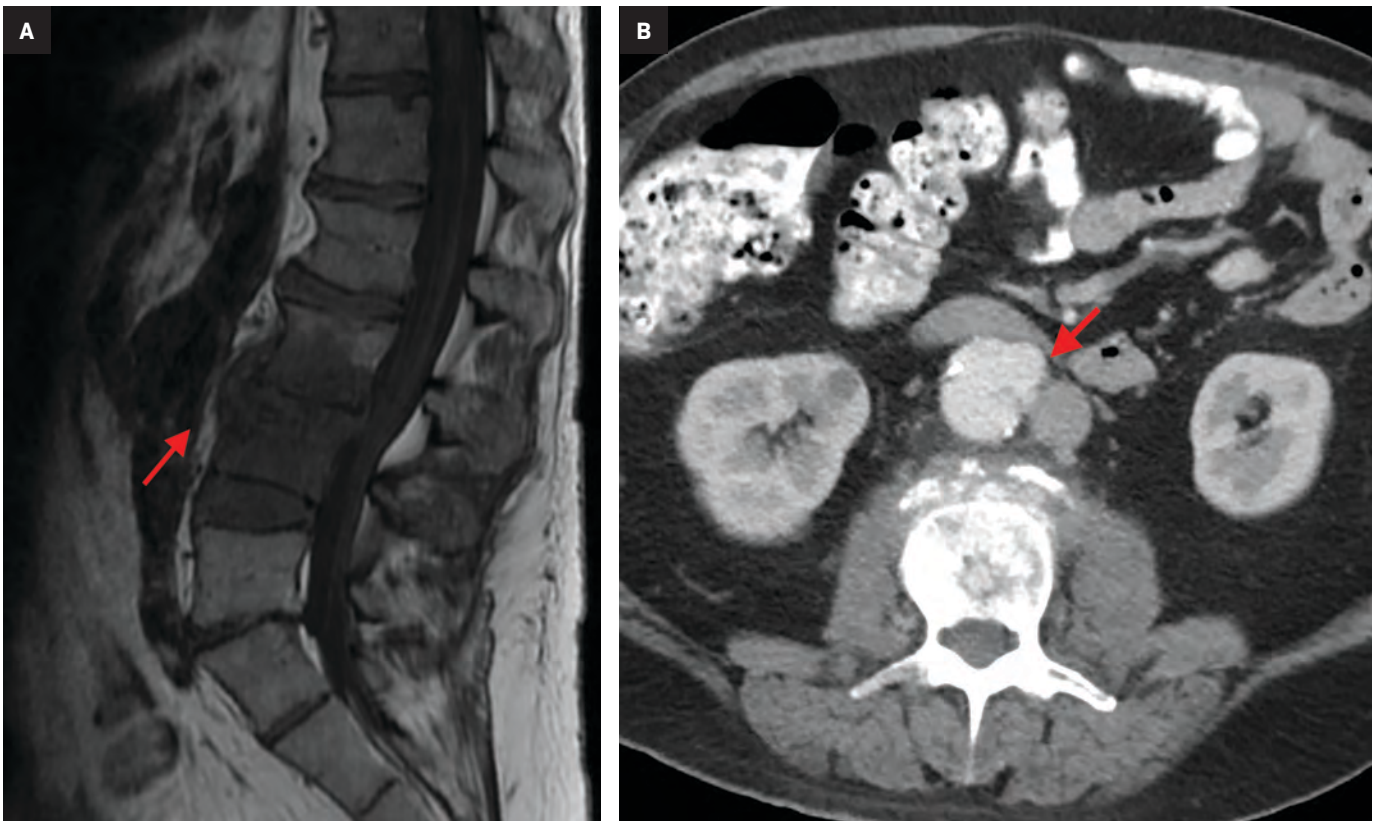

Figure 6. Elderly patient with back pain and lower-extremity weakness. Axial T2 image (A) of the lumbar spine shows loss of the expected flow void in the aorta (arrow). Subsequent CT angiogram of the abdomen and pelvis (B) confirms aortic occlusion (arrow).

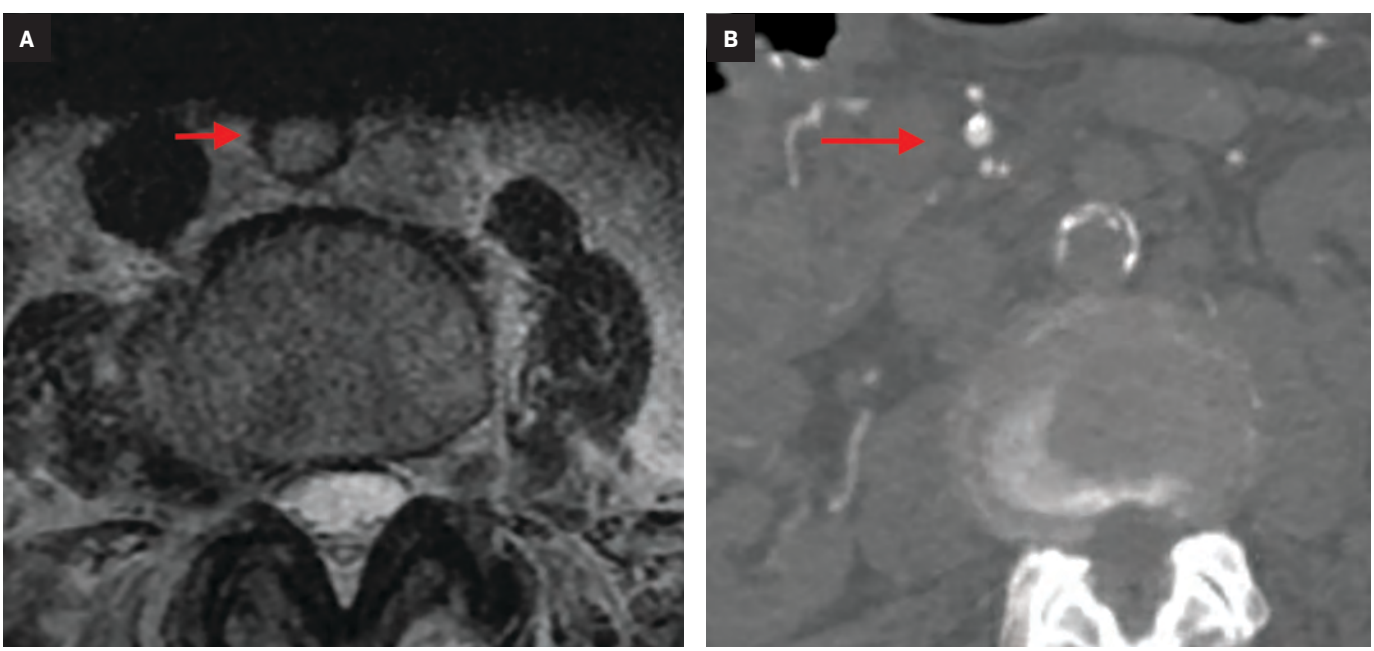

Figure 7. Contrast-enhanced CT of the lumbar spine performed emergently for back pain and concern for cauda equina syndrome shows infiltrative soft tissue encasing the celiac axis and its branches, with invasion of the adjacent left adrenal gland (arrow). Subsequent diagnosis was pancreatic malignancy.

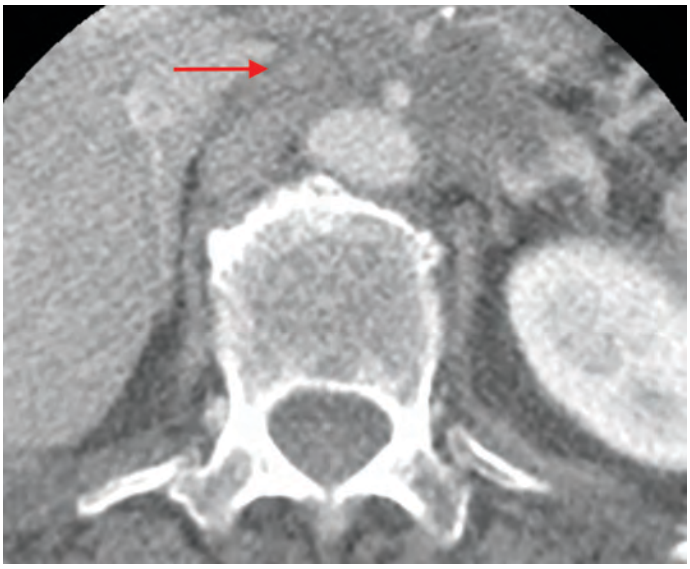

Figure 8. Middle-aged patient with neck pain. Axial T2 gradient echo image demonstrates a right oropharyngeal mass (arrow) suspicious for carcinoma.

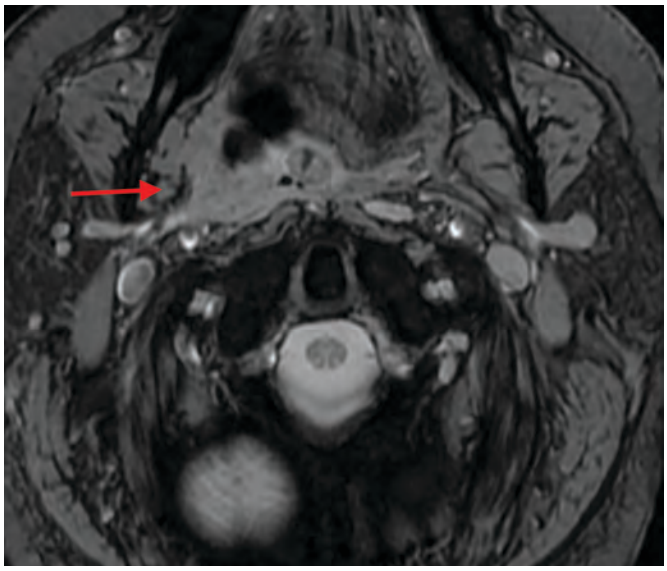

Figure 9. Older patient with back pain and bacteremia. Contrast-enhanced CT of the thoracic spine does not show any concerning osseous findings but does show abnormal thickening and edema of the esophagus (arrow). Subsequent endoscopy confirmed esophagitis and mucosal ulcerations.

Figure 10. Axial T2 (A) lumbar MRI performed for back pain shows a heterogeneous mass in the left kidney (arrow).

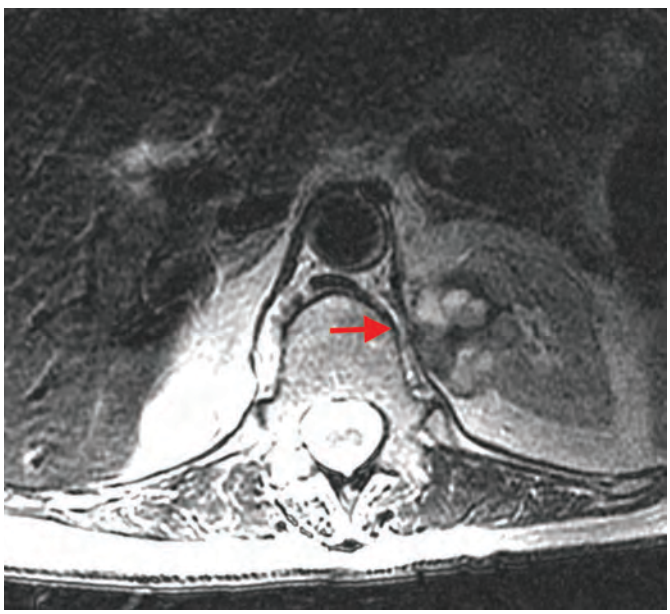

the checklist of all spine studies and considered equal in importance to any spondylosis (Figure 7).

Soft-tissue Lesions

Aside from the spinal cord and canal, other critical structures such as the nasopharynx, oropharynx, and cervical lymph nodes are frequently visualized in cervical spine imaging, even in the presence of saturation bands (Figure 8). Most mildly enlarged lymph nodes in younger patients are reactive, but they assume greater importance in patients over age 40. Sagittal MRI may also reveal portions of the posterior fossa and even the sella turcica and cavernous sinuses. Thyroid nodules and masses are also commonly demonstrated. When reviewing thoracolumbar images, radiologists should look out for lung tumors and nodules. Small layering

Figure 11. Middle-aged patient with mid-back pain. Axial T2 image (A) of the thoracic spine shows a round flow void contiguous with the distal splenic artery, suspicious for a splenic artery aneurysm (arrow), which is confirmed by contrast-enhanced CT (B) of the abdomen.

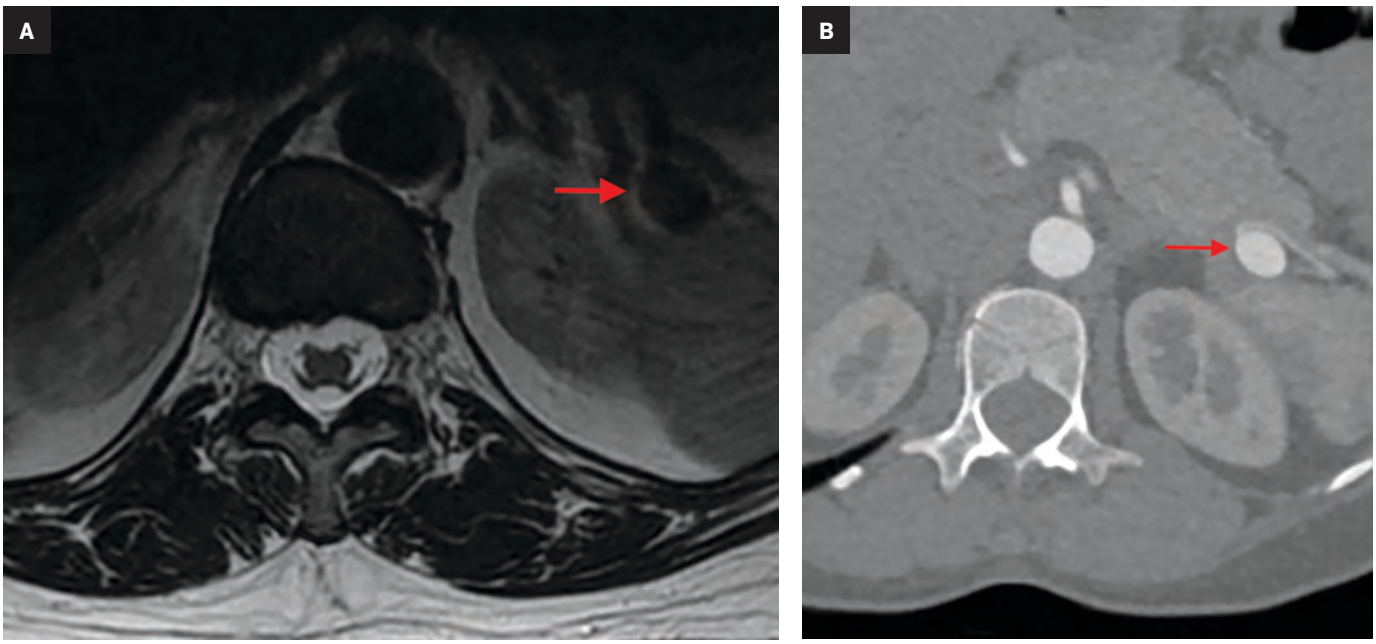

Figure 12. Elderly patient with neck pain. Sagittal T1 image (A) shows abnormal marrow signal in the clivus (arrow). The patient was otherwise asymptomatic. Subsequent CT (B) confirmed a large lytic lesion in the clivus (arrow). Upon further questioning, patient reported a history of a pituitary tumor resection and radiation therapy. Post-treatment changes were favored with imaging surveillance recommended.

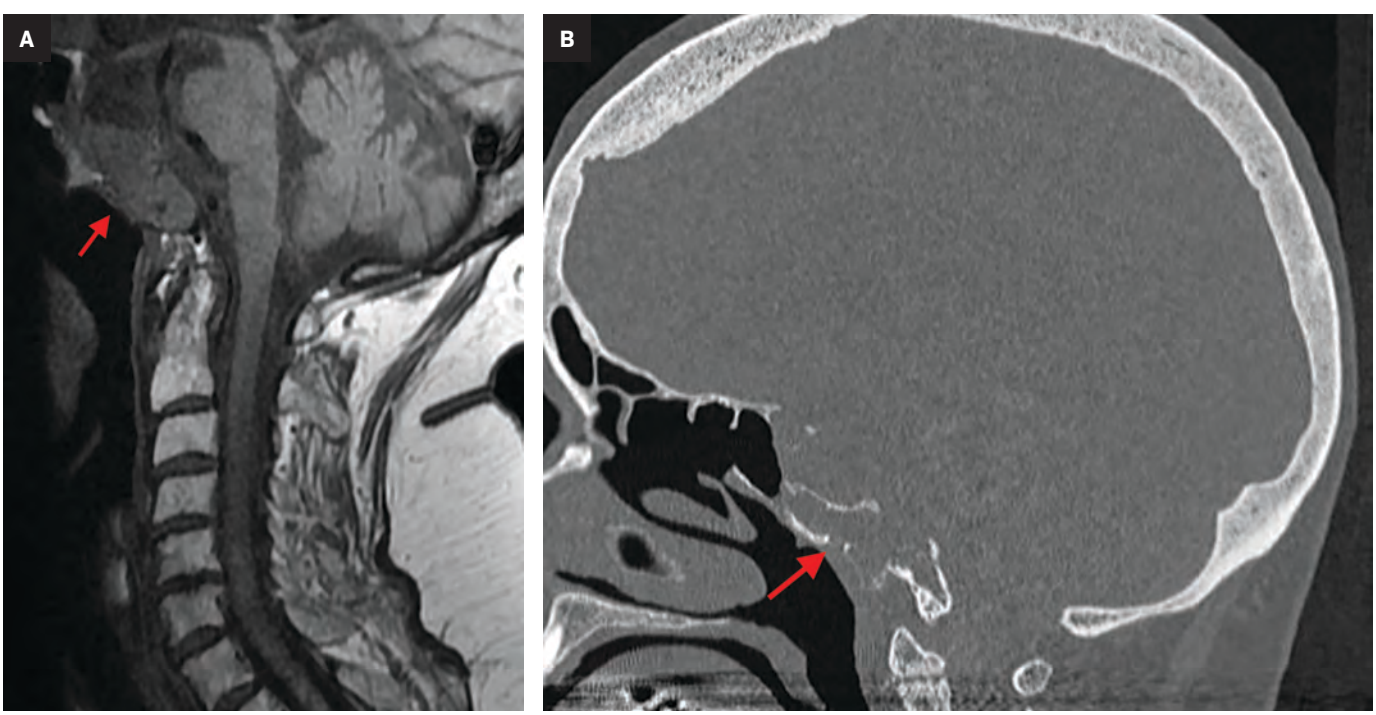

pleural effusions are common, as are esophageal abnormalities that may be a source of pain (Figure 9).

Lumbar spine imaging is often performed to evaluate for low back pain; a careful, level-by-level review of the images for spinal canal and bilateral foraminal and subarticular and lateral recess stenoses can be tedious. However, after a detailed review and report of degenerative changes, an equally careful review for extraspinal findings can be fruitful, especially in older patients. Renal tumors may present with back pain (Figure 10), as may pancreatic, peri-pancreatic (Figure 11), and gall bladder abnormalities. Simple hepatic and renal

cysts are common, and they must be reported when they demonstrate concerning features.

Edge-of-Film Findings

A common subtype of perceptive radiologic error is the so-called "edge-of-film" finding, which has persisted long enough to generate a category of its own. Abnormalities at the edges of the film are more likely to be missed than those at the center. The brain and skull base are at the superior edge of cervical spine films, while the great neck vessels and airway course along the anterior margin (Figure 12). In the lumbar spine, the conus medullaris appears at the superior edge, with the sacrum appearing inferiorly and the lower gastrointestinal tract or genitourinary structures appearing anteriorly.

Figure 13. Lower thoracic canal stenosis. Sagittal T2 of the lumbar spine in an elderly patient with an edge-of-film severe lower thoracic canal stenosis (arrow).



Figure 14. Adolescent with low back pain and bilateral L4 pars interarticularis defects on lumbar MRI. Sagittal T2 image (A) shows abnormal signal in the conus medullaris just at the edge of the image (arrow). Subsequent thoracic spine MRI (B) recommended by the interpreting neuroradiologist shows an extensive syrinx in the thoracic spinal cord (arrow). Brain MRI (C) shows an asymptomatic Chiari I deformity (arrow). Images courtesy of Adam Blanchard, MD, American Radiology Associates, Dallas, Texas.

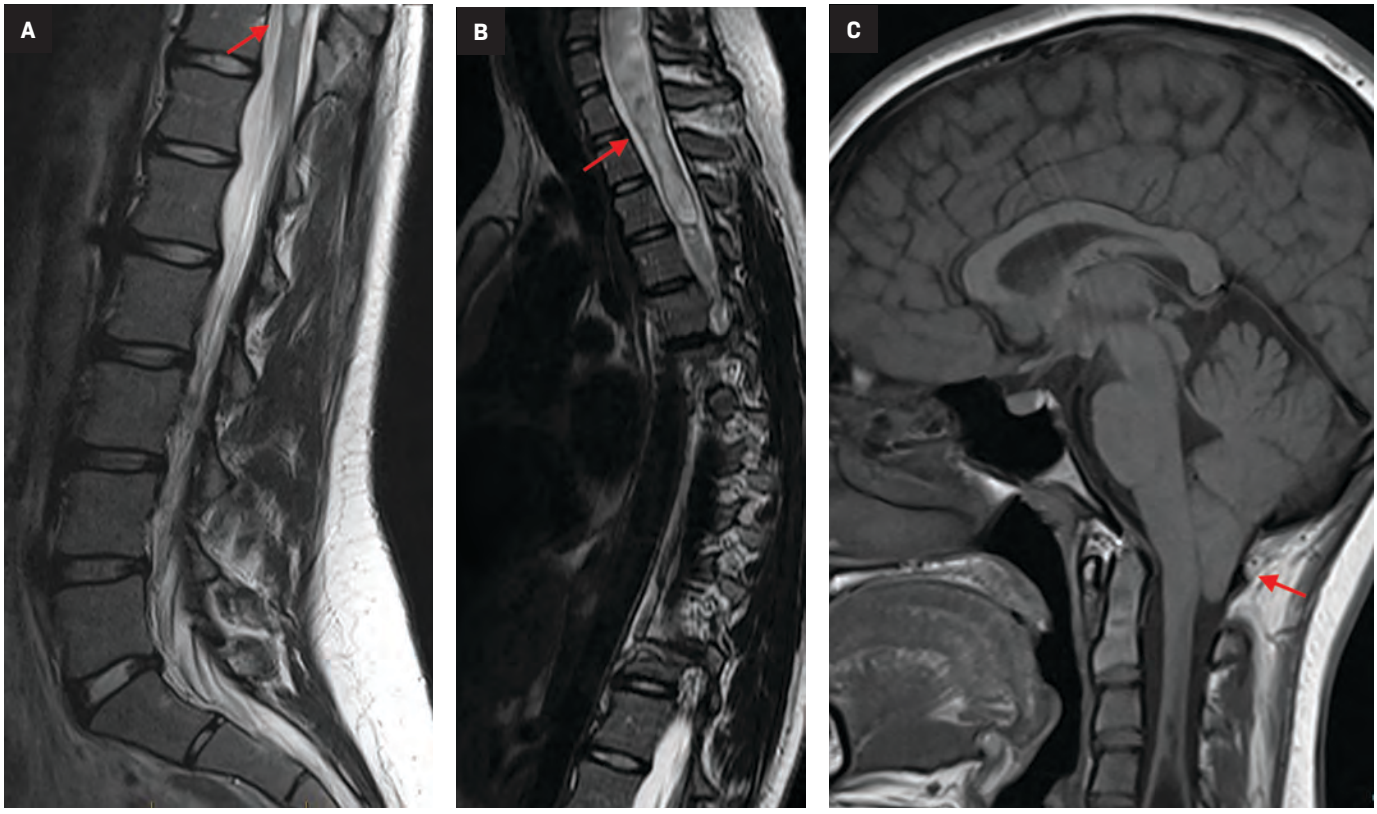

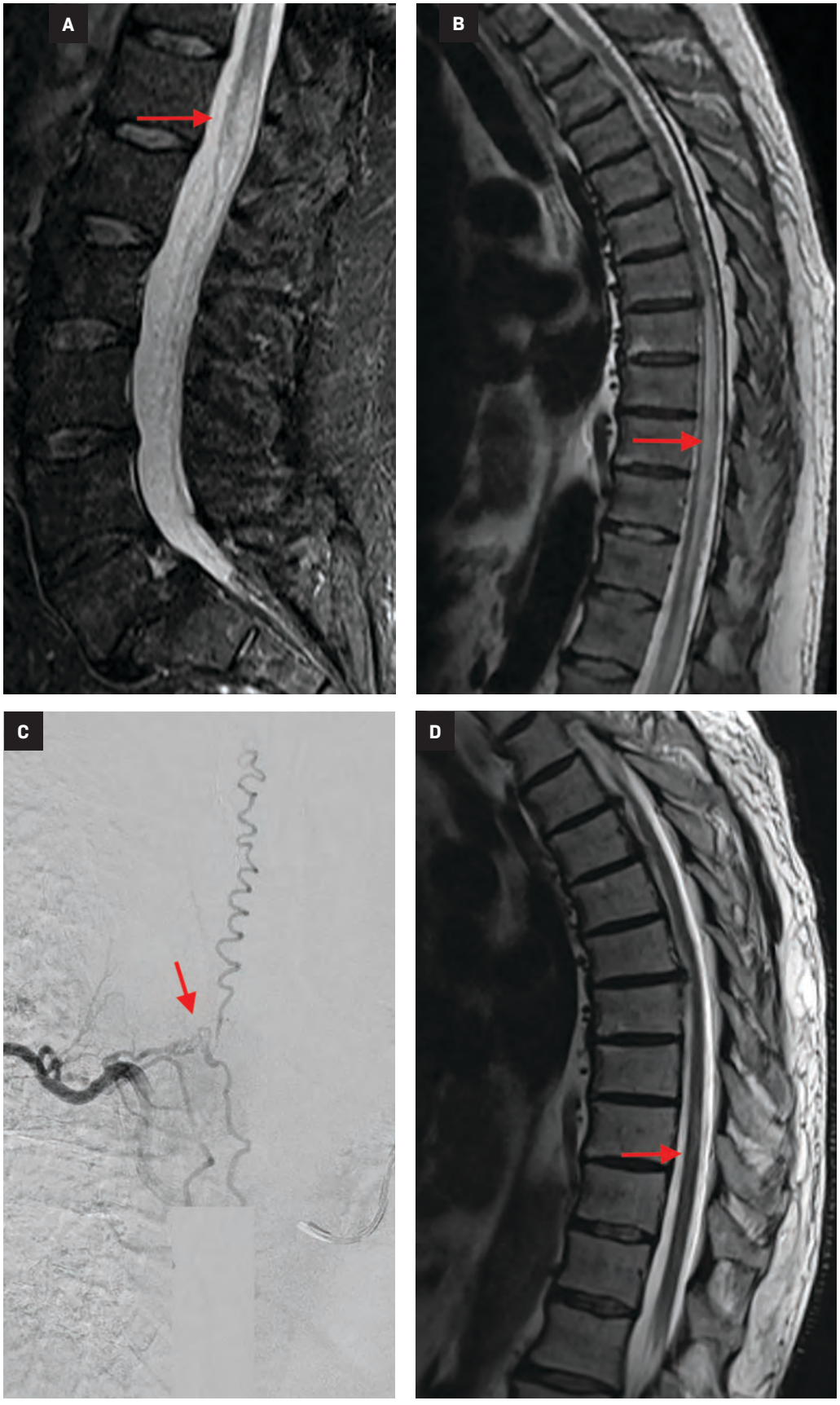

Figure 15. Middle-aged patient with low back pain and progressive weakness. Sagittal STIR (A) lumbar MRI shows abnormal signal in the conus medullaris (arrow). Based on this finding, a thoracic MRI (B) shows abnormal T2 signal (arrow) in the thoracic spinal cord and subtle abnormal vascularity along the dorsal surface of the cord. These findings were suspicious for a spinal vascular malformation. Spinal angiography (C) confirmed a spinal dural arteriovenous fistula (arrow). Thoracic spine MRI (D) several months after embolization showed substantial interval improvement in spinal cord edema (arrow) and abnormal vascularity.

Figure 16. Older patient with persistent back pain after lumbar surgery. Axial T1 image (A) shows abnormally low T1 marrow signal through the sacral alae, suspicious for bilateral sacral insufficiency fractures (arrows). Fractures are confirmed on follow-up noncontrast CT of the pelvis (B).

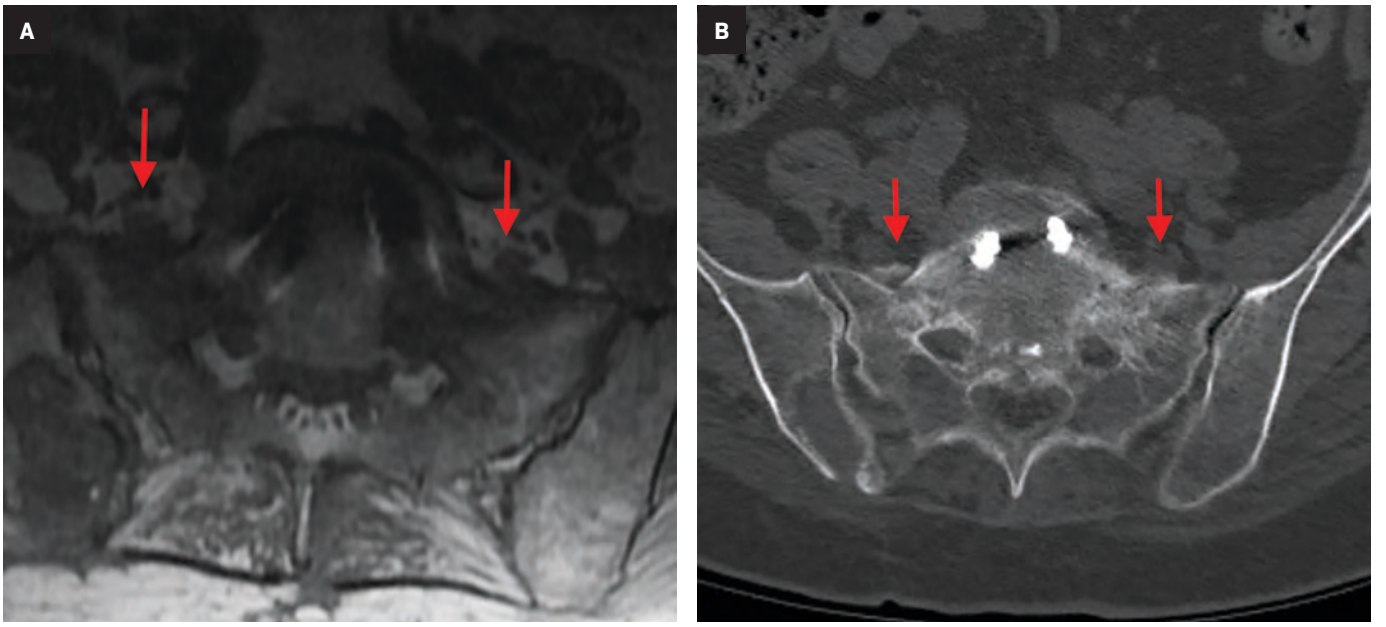

While not extraspinal, abnormal signal intensity in the conus medullaris sometimes goes undetected on lumbar spine studies, resulting in callbacks for additional contrast imaging of the cervical and thoracic spine (Figures 13-15). Other subtle findings may include prominent vessels in cases of dural arteriovenous fistulae (Figure 13). The most common important sacral abnormalities that may be missed are nondisplaced fractures (Figure 16), which can be subtle in older and osteopenic patients.

Conclusion

Extraspinal abnormalities are common in spine imaging, particularly in older patients. Thoroughly searching scout/localizer sequences, vascular structures, extraspinal soft tissues, and edges of the film for these potentially serious entities is important for both trainees and the seasoned radiologists as they interpret cross-sectional spine images to provide optimal patient care.

References:

1) Freburger JK, Holmes GM, Agans RP, et al. The rising prevalence of chronic low back pain. *Arch Intern Med*. 2009;169(3):251-258. doi:10.1001/archinternmed.2008.543.

2) Chou D, Samartzis D, Bellabarba C, et al. Degenerative magnetic resonance imaging changes in patients with chronic low back pain: a systematic review. *Spine (Phila Pa 1976)*. 2011;36(21 Suppl):S43-S53. doi:10.1097/BRS.0b013e31822ef700.

3) Ruutiainen AT, Durand DJ, Scanlon MH, Itri JN. Increased error rates in preliminary reports issued by radiology residents working more than 10 consecutive hours overnight. *Acad Radiol*. 2013;20(3):305-311. doi:10.1016/j.acra.2012.09.028.

4) Itri JN, Tappouni RR, McEachern RO, Pesch AJ, Patel SH. Fundamentals of diagnostic error in imaging. *Radiographics*. 2018;38(6):1845-1865. doi:10.1148/rg.2018180021.

5) Bruno MA, Walker EA, Abujudeh HH. Understanding and Confronting Our Mistakes: The epidemiology of error in radiology and strategies for error reduction. *Radiographics*. 2015;35(6):1668-1676. doi:10.1148/rg.2015150023.

6) Patel SH, Stanton CL, Miller SG, Patrie JT, Itri JN, Shepherd TM. Risk factors for perceptual-versus-interpretative errors in diagnostic neuroradiology. *AJNR Am J Neuroradiol*. 2019;40(8):1252-1256. doi:10.3174/ajnr.A6125.

7) Johnson PT, Scott WW, Gayler BW, Lewin JS, Fishman EK. The CT scout view: does it need to be routinely reviewed as part of the CT interpretation? *AJR Am J Roentgenol*. 2014;202(6):1256-1263. doi:10.2214/AJR.13.10545.

8) Daffner RH. Reviewing CT scout images: Observations of an expert witness. *AJR Am J Roentgenol*. 2015;205(3):589-591. doi:10.2214/AJR.15.14405.

9) Berlin L. Reviewing the CT scout view: medicolegal and ethical considerations. *AJR Am J Roentgenol*. 2014;202(6):1264-1266. doi:10.2214/AJR.12.10444.

10) Smith WS, Johnston SC, Skalabrin EJ, Weaver M, Azari P, Albers GW, Gress DR. Spinal manipulative therapy is an independent risk factor for vertebral artery dissection. *Neurology*. 2003 May 13;60(9):1424-8.

11) Silbert PL, Mokri B, Schievink WI. Headache and neck pain in spontaneous internal carotid and vertebral artery dissections. *Neurology*. 1995;45(8):1517-1522. doi:10.1212/wnl.45.8.1517.

12) Brinjikji W, Nasr DM, Morris JM, Rabinstein AA, Lanzino G. Clinical outcomes of patients with delayed diagnosis of spinal dural arteriovenous fistulas. *AJNR Am J Neuroradiol*. 2016;37(2):380-386. doi:10.3174/ajnr.A4504.

Going with the (Work)Flow in Radiology

Jonathan Balcombe, MD and Lawrence N Tanenbaum, MD, FACR

Affiliation: Dr. Balcombe is section head of CT and patient safety, Assuta Medical Centres, Israel and chief medical officer of Imedis AI. Dr Tanenbaum is vice president and chief technology officer at RadNet, Inc., New York, New York. He is a member of the Editorial Advisory Board of *Applied Radiology*.

Early expectations that AI-empowered computers would one day render radiologists obsolete have proved premature and far from becoming reality. Instead, many of the myriad AI-powered applications on the imaging market today target just one or two stages of the radiology workflow, albeit with impressive performance and results.

The Radiology Workflow

But before we get into discussing them, it's worth briefly reviewing the workflow followed by virtually every radiology enterprise—private and hospital based—around the world. It begins when a referring health care professional requests a study based on their clinical interaction with a patient. A payer then approves the study, which is then protocolled by a radiologist, performed by a technologist, and finally returned to the radiologist for interpretation. The report is conveyed to the referring health care professional. Ideally billed accurately and completely, the study may or may not be audited by the payer for quality and compliance.

Each step in this straightforward journey is vulnerable to error or suboptimal decision making or execution. Current AI-driven offerings typically impact one of these steps; the underlying AI algorithms that power them are based mostly on computer vision (CV) analysis or natural language processing (NLP).

Hospital-based sub-specialists such as neurosurgeons or urologists are familiar enough with the range of studies most commonly utilized to answer their clinical questions. In contrast, family physicians and other generalists may not have the radiologic knowledge required to select the optimal modality to evaluate a particular clinical syndrome.

An AI technology that can flag apparent discrepancies between the clinical question and the requested study can improve diagnostic yield; thereby improving patient care and reducing the expense associated with incorrect utilization. A product that can perform this task would require NLP, which could evaluate not only the study request, but also the patient history and clinical findings, to determine whether the requested study and/or protocol are appropriate to the case.

Artificial intelligence has a budding role within our imaging devices. Correct patient positioning at the center of the CT bore, a task that busy technologists sometimes fail to perfect, ensures optimal radiation dose and image quality. One study comparing manual positioning with AI-assisted automatic patient positioning using a GE Revolution Maxima showed a 16% reduction in dose, along with shorter duration and improved image signal-to-noise ratio for the AI-assisted method.[1]

AI-driven tools can also automatically set the range for an imaging exam to prevent over- and under-scanning. Patient motion or misalignment of the field of view resulting in exclusion of part of a key organ can render a CT or X-ray series non-diagnostic. A harried technologist might miss this problem, but an algorithm can monitor and prompt consideration of a repeat acquisition.

To cite another example, metal-containing implants cause artifacts on CT and MR images. Rather than relying solely on completeness of the patient history or alertness of the technologist, scanners can employ AI tools to detect implanted metal on scout/localizer images and then automatically implement metal-artifact reduction sequences for MRI and reconstruction algorithms for CT.

Guerbet
Digital Solutions

Got DACS?

Dose Archiving and Communications System

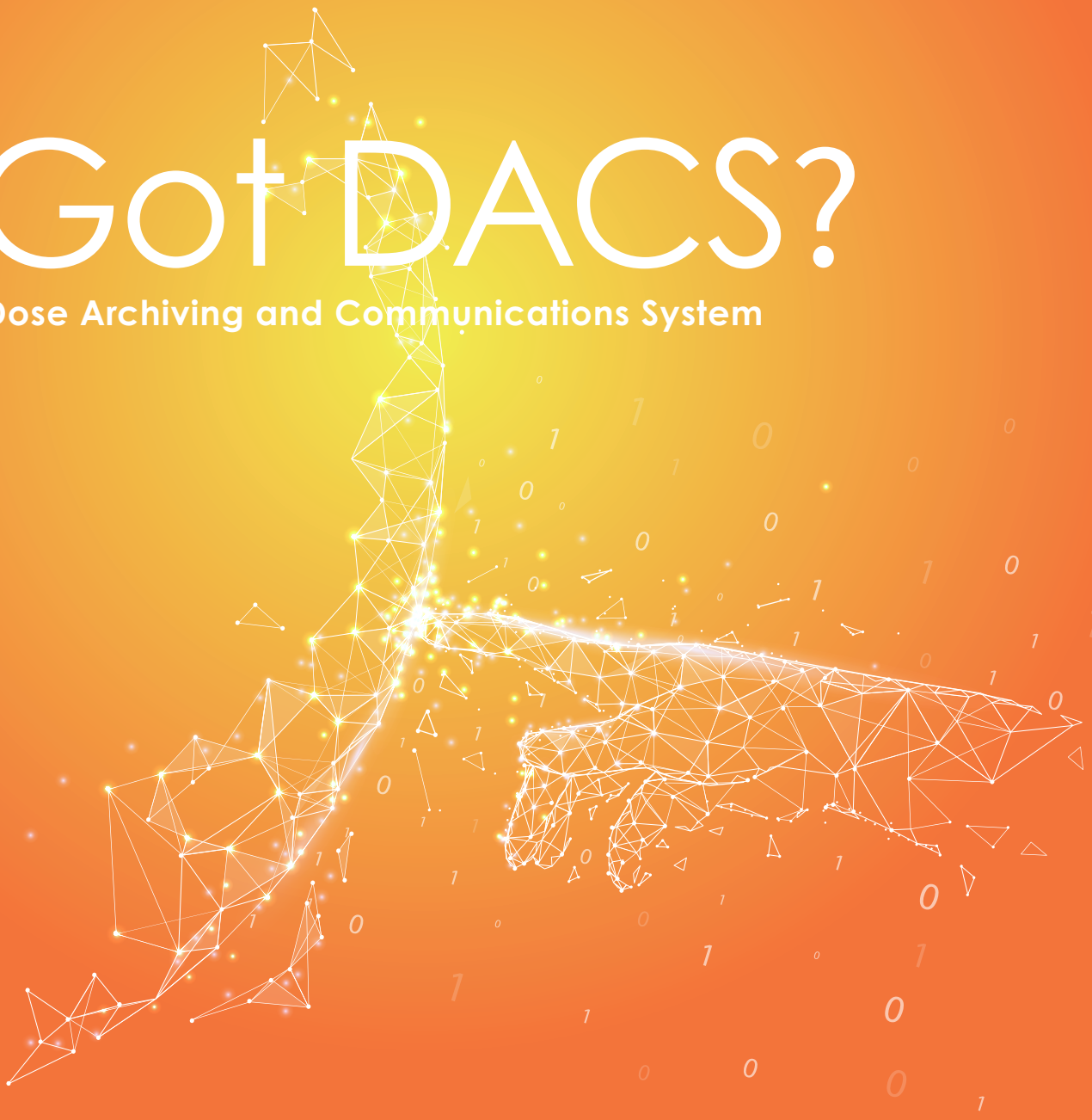

Dose&Care® is a state-of-the-art patient X-ray dose management solution to aid monitoring of patient radiation exposure. Contrast&Care® is an easy-to-use, injection data-management solution that integrates with existing medical platforms.

Both enable imaging centers to collect, archive and share information. Discover how Guerbet Digital Solutions can help you stay a step ahead.

Dose&Care® **Contrast**&Care®

©2021 Guerbet LLC
GU03210026

Upon completion of a study, the images are sent to a PACS for interpretation. Studies are usually prioritized according to origin or urgency; for example, studies ordered by the emergency department are marked for immediate reading. Inevitably, however, some studies with acute findings end up languishing on a worklist. Several computer vision products on the market are designed to evaluate for hemorrhage, stroke, aortic dissection, pulmonary embolism, and other clinically urgent findings and prioritize positive studies for prompt interpretation.

Additionally, in the setting of acute stroke, notifications to the referring team can be automated, minimizing the time to intervention. A clinical trial of one ischemic stroke-detection product demonstrated a 22-minute time savings in transferring patients from a primary stroke center to a comprehensive stroke center, and an 89-minute time savings between patient arrival at the primary center to the start of the interventional procedure.[2]

Many other commercially available image-analysis algorithms, including those from DeepHealth, Curemetrix, Kheiron, AIDOC, Gleamer, and Qure.AI, can evaluate for specific lesions such as pulmonary nodules, pneumonia, breast cancer, and fracture. Some incorporate the ability to evaluate prior studies (eg, for lung nodule growth) or attempt to characterize the aggressiveness of a lesion (lung nodule malignancy score).

However, image analysis algorithms (eg, for pulmonary nodule detection) present challenges. The combination of true and false positive flags can lead to "alert fatigue." For the radiologist, who will detect the majority of these findings without AI assistance, most alerts prove either unnecessary or false. As a result, few radiologists put these products to use.

By leveraging a combination of computer vision image analysis and NLP of the radiologist's report, one dual AI algorithm (DualiQ, Imedis AI) attempts to call attention only to actionable, unreported findings like pulmonary nodules, dilated aortas, and liver and pancreatic lesions, and to prevent alerts for findings already noted. This tool has been shown to lead to a 13% increase in detection of actionable findings with minimal unnecessary alerts.[3] Alternatively, the application can curate selected, high-yield exams for retrospective quality assurance (QA), outperforming the low rate of discrepancies found in typical, randomized QA processes.[4]

Natural language processing may garner less public attention than computer vision analysis, but a plethora of NLP products are becoming available to help maximize the effectiveness of radiology reports. Among the capabilities of these products are the ability to:

1. Detect laterality concordance errors between the report body and impression;
2. Automatically generate the report impression;
3. Detect reported actionable findings and generate evidence-based recommendations (eg, follow- up CT study for a 7mm pulmonary nodule);
4. Convey follow-up recommendations to clinicians and/or verify scheduling of follow-up scans;
5. Detect billing errors, including discrepancies among the study performed and the reported study description, the absence of clinical history, etc.; and,
6. Check report compliance with Merit-based Incentive Payment System measures.

Grand visions of AI superseding the role of radiologists have faded. Instead, a collection of AI products is developing to aid the efficiency, accuracy, or timeliness of the radiology workflow. Many boast impressive reductions in time to treatment, radiation dose, missed actionable findings, and improved implementation of radiologist recommendations. The fragmentary nature of the market makes deploying AI solutions across the enterprise difficult for radiology departments. However, the AI market for radiology remains in its infancy. In its maturation lies the promise of a future in which a single integration can enable application of multiple solutions.

References

1) Gang Y, Chen X, Li H, *et al.* A comparison between manual and artificial intelligence–based automatic positioning in CT imaging for COVID-19 patients. *Eur Radiol. 2021;*31: 6049–6058. https://doi.org/10.1007/s00330-020-07629-4.

2) Hassan AE, Ringheanu VM, Rabah RR, Preston L, Tekle WG, Qureshi AI. Early experience utilizing artificial intelligence shows significant reduction in transfer times and length of stay in a hub and spoke model. *Interv Neuroradiol.* 2020 Oct;26(5):615-622. doi: 10.1177/1591019920953055. Epub 2020 Aug 26. PMID: 32847449; PMCID: PMC7645178.

3) Yen A, Pfeffer Y, Blumenfeld A, Balcombe JN, Berland LL, Tanenbaum L, Kligerman SJ. Use of a dual artificial intelligence platform to detect unreported lung nodules. *J Comput Assist Tomogr.* 2021 Mar-Apr 01;45(2):318-322. doi: 10.1097/RCT.0000000000001118. PMID: 33273162.

4) Itri JN, Donithan A, Patel SH. Random versus nonrandom peer review: a case for more meaningful peer review. *J Am Coll Radiol.* 2018 Jul;15(7):1045-1052. doi: 10.1016/j.jacr.2018.03.054. Epub 2018 May 25. PMID: 29807816.

HARD DATA. HUMAN INSIGHTS.

A surface-level view of your patient isn't sufficient.

In today's healthcare world, you need to look deeper into the data – developing diagnosis based on the full picture.

With IBM Watson Imaging Patient Synopsis, our cloud-based solution – we're extracting all relevant EHR data into a single-view summary. So Radiologists can get the clinical context they need to make intelligently informed care decisions. All in a matter of seconds.

– Extract information from clinical reports
– Find the true "reason for exam" behind the imaging order
– Automatically load the patient summary in context
– Set up and receive automated reports

Guerbet Digital Solutions guerbet-us.com

©2021 Guerbet Group

GU12201247

Developing Breast Imaging Services in Low-Resource Settings

Erica B Pollack, MD; Genevieve Abbey, MD; Patricia DuCharme, MSN, RN, ANP-BC; Melissa A Durand, MD; Ameena Elahi, MPA, RT(R), CIIP; Mai A Elezaby, MD; Amina Farooq, MD; Tatiana Kelil, MD; Michael Jin, MD; Anne-Marie Lugossy, MPH, RT(R); Victoria L Mango, MD; Olive Peart, MS, RT(R)(M); Debra Poelhuis, MS, RT(R)(M); Karen Sacker, RT(R)(M); Alan Schweitzer, MEE; Jamie T Surratt, MD; Monica Vazquez RT(M); Mary Wetherall, RN, MSN, HN-BC; John R Scheel, MD, PhD, MPH; Daniel J Mollura, MD

As radiologists and radiology professionals, we find it hard to fathom healthcare without the critical medical imaging routinely utilized in the United States. In a typical breast imaging practice in a high-resource setting, the majority of cancers are diagnosed as stage 0 or stage I, with a 90% cure rate, having benefited from state-of-the-art tools for image-guided detection and diagnosis.[1-4] In medically underserved regions, however, this is not the norm.

Breast cancer is the leading cause of cancer death for women worldwide, and its incidence continues to increase, particularly in low- and middle-income countries (LMICs).[3]

There is relatively higher mortality from breast cancer in LMICs compared to high-income countries (HICs), which may be due to differences in tumor biology, limited awareness about breast cancer on the part of patients or healthcare providers, and lack of access to screening, diagnostic, and treatment services.[1,5-8] Without structured screening programs or easily accessible imaging and intervention, breast cancer in LMICs is more commonly diagnosed at a late stage (stage III or IV) compared to HICs.[3] While early-stage breast cancer is largely curable with appropriate surgical, oncologic, and radiation therapy, late-stage breast cancer has a much higher morbidity and mortality rate.[4,9] Furthermore, late-stage breast cancer requires more advanced therapies, which are difficult to come by in the low-resource setting.

RAD-AID International is a non-profit organization that works to increase access to imaging services worldwide, with programs in 40 countries supporting 91 healthcare facilities. The Breast Imaging section of RAD-AID coordinates with local partners to improve access to breast care in LMICs as well as in medically underserved communities in HICs. The organization's overarching strategy is to reduce breast cancer mortality in low-resource settings by downstaging disease through earlier detection. While its goals are to improve access to high-quality imaging and image-guided procedures, we recognize that early diagnosis is effective only if it is linked to early treatment. We collaborate with partner organizations and members that work across the continuum of care to ensure that women with cancer have access to treatment and post-treatment surveillance. To achieve earlier detection for larger populations, RAD-AID also supports community outreach, navigation, and patient education.

The RAD-AID Approach

RAD-AID consistently adheres to a set of guiding principles. First, we always partner with a local healthcare institution or organization that has identified breast cancer care as a priority. We rely on our partner's knowledge of local culture and local healthcare resources, their relationships with other potential local, regional, and national stakeholders, and their enthusiasm for program building.

Once we identify a partner, we follow a systematic approach to assessment, planning, implementation,

Affiliations: RAD-AID International, Chevy Chase, MD (Drs Abbey, Surratt, Mollura; Mses DuCharme, Lugossy, Poelhuis, Sacker, Vazquez; Mr Schweitzer); University of of Colorado School of Medicine, Aurora, CO (Dr Pollack); Yale University School of Medicine, New Haven, Connecticut (Dr Durand); Penn Medicine, Philadelphia, Pennsylvania (Ms Elahi); University of Wisconsin School of Medicine and Public Health, Madison, Wisconsin (Dr Elezaby); Stony Brook University Hospital, Stony Brook, NY (Drs Farook, Jin); University of California San Francisco, San Francisco, California (Dr Kelil); Memorial Sloan Kettering Cancer Center, New York, NY (Dr Mango); Fortis College, Landover, Maryland (Ms Peart); NEPA Community Health Care, Montrose, Pennsylvania (Ms Wetherall); University of Washington, Seattle Cancer Care Alliance, Seattle, Washington (Dr Scheel).

Figure 1. RAD-AID Breast Imaging Approach Flowchart. Each RAD-AID Breast Imaging program involves a collaborative, stepwise process of assessment, planning, implementation, and analysis. This systematic approach allows for sustainability and scalability.

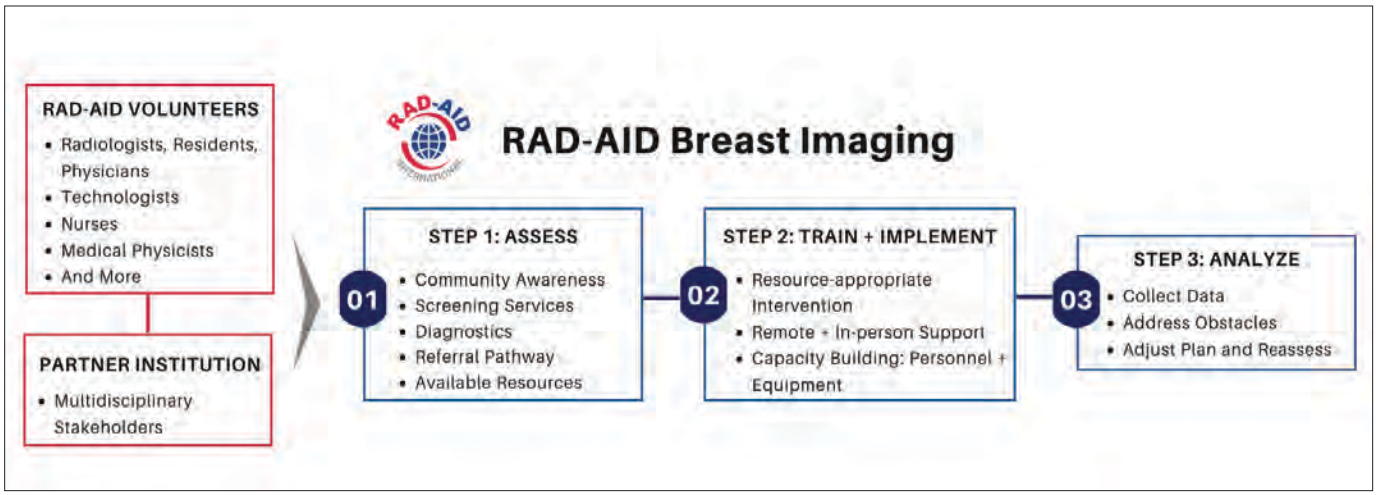

and program evaluation to develop and carry out an intervention that is uniquely tailored to the needs of our partners and the local healthcare landscape (Figure 1).[10,11] Evidence has shown that it is absolutely critical to only pursue resource-appropriate interventions. The Breast Health Global Initiative (BHGI) and the National Comprehensive Cancer Network (NCCN) have published comprehensive guidelines suggesting how resources should be allocated toward various aspects of breast cancer care depending on resource availability.[12,13] We also adhere to a phased implementation approach to build capacity gradually without overwhelming our partners.[14] Our first step of program planning, therefore, is always a thorough assessment of our target population and the local availability of screening, diagnostic services (imaging, tissue sampling, and pathology) and treatment.

Radiology-Readiness™ is RAD-AID's data collection and analysis tool, which launched in 2009. The tool received review and input and from the World Health Organization (WHO) in 2012 and has been the cornerstone of RAD-AID's official relations status with WHO since 2015. The Radiology-Readiness Assessment (RRA) collects detailed information about local healthcare assets, capabilities and radiology services at the specific prospective partner institution in order to optimize allocation of resources for high-yield clinical objectives. RAD-AID Breast Imaging has developed a breast imaging-specific RRA to collect information about available resources related to the entire spectrum of the breast health referral pathway (Figure 2). The Breast Imaging RRA allows us to identify gaps in any service that may affect a patient's cancer care, including clinical breast exams, imaging, pathology, surgery, radiation and oncologic care, and surveillance during survivorship.

When devising a strategy, we take advantage of the breadth of expertise within the RAD-AID leadership and volunteer pool to create teams of nurses, physicians, and technologists, as well as experts in quality assurance, business leadership, informatics, medical physics, and public health. Finally, we plan with an eye toward sustainability to ensure our interventions lead to lasting improvement. While we maintain long-term relationships with our partners, our goal is that the benefits of our partnerships persist even after we have stepped away from directly supporting the site. We aim to build capacity to create meaningful impacts in healthcare.

Reaching Out Through Education, Collaboration

Education and training are a major focus. We mentor institutions to develop breast imaging leaders so that those individuals may go on to increase breast cancer services locally and nationally. Our education model incorporates a holistic approach that focuses on the full continuum of care for breast health, including primary and secondary prevention, screening methods, treatment modalities, and palliative care. Our interdisciplinary teams have led combined didactic and hands-on skills training workshops to teach interventional techniques to physicians, positioning techniques to mammographers, and clinical breast exam techniques to nurses and primary healthcare workers in Ghana, Kenya, Tanzania, Ethiopia, India, Bangladesh, Peru, and Guyana.

During the COVID-19 pandemic, we adapted to restricted travel conditions by shifting to remote teaching and leveraging an online-learning management platform of prerecorded lectures, live webinars, and ongoing

Figure 2. Outline of the RAD-AID Breast Imaging Radiology-Readiness™ Assessment. Thorough assessment of the target population and available services are necessary to appropriately allocate resources and ensure that all interventions are high-impact.

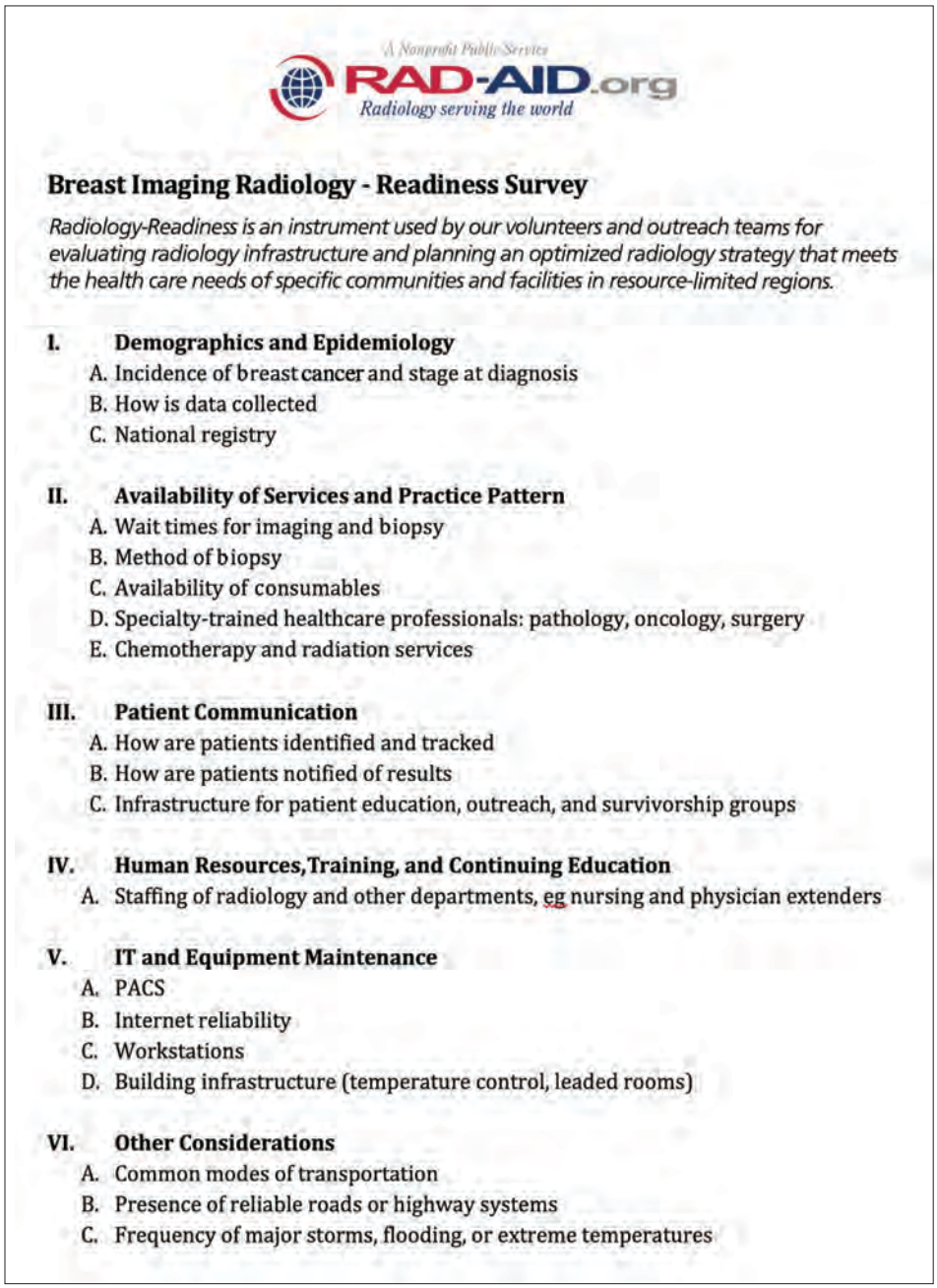

A Nonprofit Public Service
RAD-AID.org
Radiology serving the world

Breast Imaging Radiology - Readiness Survey

Radiology-Readiness is an instrument used by our volunteers and outreach teams for evaluating radiology infrastructure and planning an optimized radiology strategy that meets the health care needs of specific communities and facilities in resource-limited regions.

I. Demographics and Epidemiology
- A. Incidence of breast cancer and stage at diagnosis
- B. How is data collected
- C. National registry

II. Availability of Services and Practice Pattern
- A. Wait times for imaging and biopsy
- B. Method of biopsy
- C. Availability of consumables
- D. Specialty-trained healthcare professionals: pathology, oncology, surgery
- E. Chemotherapy and radiation services

III. Patient Communication
- A. How are patients identified and tracked
- B. How are patients notified of results
- C. Infrastructure for patient education, outreach, and survivorship groups

IV. Human Resources, Training, and Continuing Education
- A. Staffing of radiology and other departments, eg nursing and physician extenders

V. IT and Equipment Maintenance
- A. PACS
- B. Internet reliability
- C. Workstations
- D. Building infrastructure (temperature control, leaded rooms)

VI. Other Considerations
- A. Common modes of transportation
- B. Presence of reliable roads or highway systems
- C. Frequency of major storms, flooding, or extreme temperatures

regular virtual classrooms with readout sessions of recent cases. For sites where RAD-AID has donated Picture Archiving and Communication Systems (PACS) – Guyana, Nigeria, and Laos, for example – image-sharing for case consultations and real-time clinical teaching have also been implemented.

To augment breast care resources in LMICs, supporting in-country training programs for radiologists who need specialized breast imaging education is vital. RAD-AID is helping to create breast imaging fellowships in Ethiopia, Kenya, and Ghana. Such fellowships require longitudinal relationships through multiple stages of education program planning, including curriculum development and approval, faculty and trainee recruitment, program implementation, and collection of competency metrics.

In LMICs and HICs, breast imaging outreach can be flexibly implemented to suit local contexts via mobile or fixed-site small clinics, tertiary care institutions, or a combination thereof. RAD-AID is supporting care models across these contexts, including mobile mammography in India, Morocco, and the United States; camp clinics in India, Jordan, Kenya, and the United States; a primary care clinic in Peru; and tertiary care sites in Ethiopia, Ghana, Guyana, Indonesia, and Kenya.

While mammography is the mainstay of breast imaging in high-resource regions with large-scale screening programs, it is not a feasible option everywhere. We have found that breast ultrasound is often more easily implemented in early detection programs. For example, in Cusco, Peru, our assessment identified breast health for indigent women as a critical gap in the local healthcare landscape. In partnership with Cervicusco, a non-profit organization that provides cervical cancer services, and the Instituto Nacional de Enfermedades Neoplásicas (INEN, the National Cancer Hospital of Peru), we have taught breast ultrasound to healthcare providers already skilled at performing body ultrasound with an efficient, systematic approach.[15,16] In keeping with the BHGI and NCCN guidelines, we focus on ultrasound as a diagnostic tool in these regions. There is also evidence that ultrasound may be a useful screening tool in areas where mammography is unfeasible.[17]

In the United States, RAD-AID launched a longitudinal collaboration with the Black Women's Health Imperative (BWHI), National Alliance of Hispanic Health, and Hologic Inc.'s Project Health Equality to bring

awareness to and address long-standing healthcare disparities that affect women of color.[18] In this initiative, we collaborate with and support primary care centers that are already serving medically underserved women of color as well as tertiary centers interested in improving access to specialty care for women who need it most.

Our partner sites are primarily Federally Qualified Health Centers (FQHCs), primary care providers partially funded by the federal government for the purpose of reducing health inequities.[19] Creating access to screening at the point of primary care is one successful strategy implemented by our FQHC partners.[20] The approach at each institution is tailored to best meet the needs of the specific target population. Despite the varied tactics, patient navigation and strengthening of the referral pathway are critical components to address the social determinants of health.[21,22]

Artificial Intelligence Initiatives

We have implemented breast radiology artificial intelligence (AI) tools that provide real-time educational feedback for physicians and technologists. The RAD-AID AI model, called Teach-Try-Use, integrates education, infrastructure, and gradual implementations of AI to locally validate and support AI in low-resource health institutions.[23] This effort has been supported by several pro-bono contributions of breast imaging AI software integrated with RAD-AID's educational initiatives, such as Koios and Densitas. The coupling of AI with radiology education for breast health outreach has been particularly valuable while in-person education had been halted during the pandemic.[24]

The Koios Decision Support for Breast system uses machine learning to improve accuracy of breast lesion assessment on ultrasound.[25] We expect this tool to help general radiologists and non-radiology providers in Guyana, Kenya, and Peru triage breast ultrasound cases so that suspicious lesions are diagnosed quickly and valuable resources are not wasted on typically benign lesions. Densitas® qualityAI™ uses machine learning to provide mammography technologists with real-time feedback on positioning and other critical quality control metrics.[26] This has been implemented in Guyana, where mammography is a relatively newly available modality, and continuing education for mammography technologists is not easily available, particularly during the pandemic.

In our preliminary pilot of breast imaging AI using Densitas in Guyana, seven mammography technologists received AI-based quality feedback on over 380 radiology exams. This resulted in approximately 20-point improvements in posterior breast tissue inclusion in screening exams over a ten-week period from October to December 2020. High-quality mammograms are critical for accurate interpretation and early detection of breast cancer. Since the success of any AI tool in a specific setting depends on the applicability of the database from which its algorithms are trained, we anticipate that implementation of AI in the low-resource setting will lead to continued development of AI tools that are able to serve patients everywhere.[24,27]

Future Directions and Goals

As the pandemic continues in 2022 — placing disproportionate burden on healthcare systems in low-resource settings — we will continue to focus on remote education and support. We aim to develop and expand our breast health curriculum to include the important role of patient navigation.

In the United States, we plan to scale our model of care to other sites and engage policy makers to change healthcare delivery to poor communities. On a larger scale, we plan to carefully move forward with responsible implementation of AI tools that can increase efficiency and capacity, including diligent ongoing analysis and monitoring to ensure that it is able to serve the needs of diverse populations.

We hope that in time we are able to effect change that brings needed resources to breast cancer care globally with a focus on early detection. To that end, the RAD-AID Breast Imaging team eagerly welcomes new volunteers with expertise in any aspect of breast cancer care who are interested in promoting high-quality care to underserved patients.

Participation can include donating educational materials, leading live, web-based workshops, rendering over-read opinions on day-to-day cases, working with our physics and quality teams to ensure appropriate standards, trouble-shooting equipment issues via web videoconferencing, or collaborating with our informatics team to coordinate PACS and AI implementation.

We seek partnerships with creative and enthusiastic healthcare providers dedicated to improving the health of women worldwide.

References

1) WHO. https://seer.cancer.gov/statfacts/html/breast.html. Accessed January 5, 2022.

2) Duggan C, Trapani D, Ilbawi AM, et al. National health system characteristics, breast cancer stage at diagnosis, and breast cancer mortality: a population-based analysis. *Lancet Oncol.* 2021;22(11):1632-1642.

3) World Health O. WHO report on cancer: setting priorities, investing wisely and providing care for all. Geneva: World Health Organization; 2020.

4) DeSantis CE, Ma J, Gaudet MM, et al. Breast cancer statistics, 2019. *CA Cancer J Clin.* 2019;69(6):438-451.

5) Sung H, Ferlay J, Siegel RL, et al. Global Cancer Statistics 2020: GLOBOCAN estimates of incidence and mortality worldwide for 36 cancers in 185 countries. *CA Cancer J Clin.* 2021;71(3):209-249.

6) DeSantis CE, Bray F, Ferlay J, Lortet-Tieulent J, Anderson BO, Jemal A. International variation in female breast cancer incidence and mortality rates. *Cancer Epidemiol Biomarkers Prev.* 2015;24(10):1495-1506.

7) Ginsburg O, Bray F, Coleman MP, et al. The global burden of women's cancers: a grand challenge in global health. *The Lancet.* 2017;389(10071):847-860.

8) Galukande M, Kiguli-Malwadde E. Rethinking breast cancer screening strategies in resource-limited settings. *Afr Health Sci.* 2010;10(1):89-92.

9) Society. AC. Cancer Facts & Figures 2021. In: Society AC, ed. Atlanta, GA2021.

10) RAD-AID International. https://rad-aid.org/resource-center/radiology-readiness. Accessed January 5, 2022.

11) Mollura DJ, Azene EM, Starikovsky A, et al. White Paper Report of the RAD-AID Conference on International Radiology for Developing Countries: identifying challenges, opportunities, and strategies for imaging services in the developing world. *J Am Coll Radiol.* 2010;7(7):495-500.

12) Yip CH, Smith RA, Anderson BO, et al. Guideline implementation for breast healthcare in low- and middle-income countries: early detection resource allocation. *Cancer.* 2008;113(8 Suppl):2244-2256.

13) Jazieh AR, McClure JS, Carlson RW. Implementation Framework for NCCN Guidelines. *J Natl Compr Canc Netw.* 2017;15(10):1180-1185.

14) Ginsburg O, Yip CH, Brooks A, et al. Breast cancer early detection: A phased approach to implementation. *Cancer.* 2020;126 Suppl 10(Suppl 10):2379-2393.

15) Aklilu S, Bain C, Bansil P, et al. Evaluation of diagnostic ultrasound use in a breast cancer detection strategy in Northern Peru. *PLoS One.* 2021;16(6):e0252902.

16) González Moreno IM, Trejo-Falcón J, Matsumoto MM, et al. Radiology volunteers to support a breast cancer screening program in Peru: description of the project, preliminary results, and impressions. *Radiologia (Engl Ed).* 2021.

17) Sood R, Rositch AF, Shakoor D, et al. Ultrasound for breast cancer detection globally: A systematic review and meta-analysis. *J Glob Oncol.* 2019;5:1-17.

18) Hologic. https://www.hologic.com/ProjectHealthEquality Accessed January 31, 2022.

19) Health Center Program: Impact and Growth. Health Resources & Services Administration. Published 2021. Updated August 2021. Accessed February 2, 2022.

20) Kim CS, Vanture S, Cho M, Klapperich CM, Wang C, Huang FW. Awareness, interest, and preferences of primary care providers in using point-of-care cancer screening technology. *PLOS ONE.* 2016;11(1):e0145215.

21) Brown J, Kaufman RE, Ariail M, Williams DL. Assessing patient navigation as a tool to address equity in cancer early detection. *Transl Cancer Res.* 2019:S421-S430.

22) Roland KB, Milliken EL, Rohan EA, et al. Use of community health workers and patient navigators to improve canceroOutcomes among patients served by federally qualified health centers: a systematic literature review. *Health Equity.* 2017;1(1):61-76.

23) International R-A. RAD-AID Artificial Intelligence. In:2021.

24) Mollura DJ, Culp MP, Pollack E, et al. Artificial intelligence in low- and middle-income countries: innovating global health radiology. *Radiology.* 2020;297(3):513-520.

25) Mango VL, Sun M, Wynn RT, Ha R. Should we ignore, follow, or biopsy? Impact of artificial intelligence decision support on breast ultrasound lesion assessment. *AJR Am J Roentgenol.* 2020;214(6):1445-1452.

26) Densitas. The Opportunity to Improve Mammography Quality with Automated, Machine Learning Software. In: Densitas Inc.; 2018.

27) Alami H, Rivard L, Lehoux P, et al. Artificial intelligence in health care: laying the foundation for responsible, sustainable, and inclusive innovation in low- and middle-income countries. *Globalization and Health.* 2020;16(1):52.

Imaging Utilization: A Matter of Dollars and Sense

Kerri Reeves

Kerri Reeves is a contributing editor based in Ambler, PA.

In January, United Healthcare announced that, beginning July 1, the insurer will offer members in select markets lower out-of-pocket costs for undergoing imaging at hospitals and imaging clinics that meet certain quality and efficiency thresholds as determined by the payer.[1,2]

It is just the latest example of how commercial insurance plans are more closely examining imaging costs and utilization and steering their members toward providers who they deem to deliver the highest-quality care at the lowest cost.

Indeed, United's announcement demonstrates a more aggressive approach to reining in the costs of imaging like those of any other procedure, test, and treatment, says Gregory Nicola, MD, FACR, a radiologist with the Hackensack (NJ) Radiology Group, and chair of American College of Radiology's (ACR) commission on economics.

"In the commercial payer world, it's creeping into contractual language that the health system will not be eligible for or receive shared savings if they don't start controlling imaging costs and utilization," Dr Nicola says.

And while United's plan rightly warrants some concern, it also gives radiologists an opportunity to demonstrate leadership with respect to imaging quality and utilization matters, says Rebecca Smith-Bindman, MD, a radiologist at University of California San Francisco and director of the Radiology Outcomes Research Laboratory.

"It's important to realize that unless we as radiologists demonstrate the value of what we do—how much we can add to the efficient diagnosis and management of patients—there's going to be a lot more scrutiny in terms of the value and what we add. We can add tremendously to patient care but not if we do any test irrespective of its value, or if we just recommend additional testing when clearly it's not needed. Consider the nonsensical follow-up of many incidental findings we know are meaningless," she says.

"It makes sense to talk to administrators about what tools radiologists can implement and that they can support [management] with the knowledge to make efficiency changes," Dr Nicola agrees, noting that insurance companies increasingly are looking at his own radiology practice's metrics with regard to imaging utilization.

A Change in Payer Attitudes Toward Imaging

Historically, imaging has enjoyed a reputation as a go-to specialty for diagnosis among patients and providers. From the patient's perspective, more imaging typically means "better care," while from the provider's side, imaging can provide definitive answers in cases of uncertainty, observes Dr Smith-Bindman. She also notes that, even in the absence of benefit, many providers gravitate toward extra imaging "just in case" to ward off potential malpractice liability, or even simply to reassure patients.

"Imaging really is adored. Patients love it and want it, and ordering physicians share that strong demand," Dr Smith-Bindman says. But increasingly

"It's important to realize that unless we as radiologists demonstrate the value of what we do—how much we can add to the efficient diagnosis and management of patients—there's going to be a lot more scrutiny in terms of the value and what we add.

Rebecca Smith-Bindman, MD

it is seen to generate false positive diagnoses that lead to cascades of testing, and over-diagnoses that lead to ongoing escalation of health care costs, she adds.

Commercial payers are enacting efforts to curb costs associated with imaging utilization, shining a light on a lack of hard evidence that the benefits of any given imaging study will both outweigh its risks and improve patient outcomes.

As a result, imaging has some catching up to do. Dr Nicola contends that, with the exception of CT for lung cancer and mammography for breast cancer, a concerted effort largely hasn't been made to quantitatively study or compare various modalities' impacts on patient care and outcomes with each other or with other diagnostic tools.

As an example, he cites the use of CT for follow-up of incidental findings. Recommendations are based on evidence-based guidelines, but rigorous longitudinal outcome studies isolating the benefit of the imaging exam are difficult to achieve.

"There hasn't been much robust data comparing the pre- and post-CT eras," Dr Nicola says. "Radiology's impact on healthcare is often difficult to study because it was so rapidly and widely adopted that comparison studies were an afterthought."

But it is not as simple as saying we know radiology has obvious value, Etta Pisano, MD, adjunct professor of radiology at the University of Pennsylvania, explains.

"We know that tomosynthesis finds more [breast cancers] but is it saving more lives?" says Dr Pisano, a breast imaging specialist who is leading a study to determine if tomosynthesis reduces progression of advanced cancers. "When we find more things, we think we're saving more lives, but this may not always be true."

Greater access to large data sets—and accompanying artificial intelligence (AI) applications to analyze them—can help determine appropriate imaging utilization and help move the specialty's transition to value-based care, she says.

"The more detailed, real-world data we have, the more likely we are to develop models that will allow us to individualize care. We'd be doing something better for patients in the screening domain, the diagnostic domain, and the treatment domain," Dr Pisano says.

"There's a need for clear understanding of what imaging is appropriate and what is not appropriate."

Dr Smith-Bindman adds that, just as most treatment decisions around medications are based on randomized controlled trials that provide evidence for the efficacy of a given medication, imaging use must be evaluated the same way.

"If you're going to publish a study advocating use of a new imaging test, you need meaningful evidence that should undergo the same exact scrutiny we require for other medical interventions," she says. Dr Smith-Bindman pointed to her own randomized trial comparing ultrasonography with CT imaging on the outcomes of patients with suspected kidney stones.[3] "We can and should generate the same level of evidence for what we do, and this would go a long way toward both defining appropriate imaging pathways and demonstrating our meaningful impact on patient outcomes," she adds.

The same is true with respect to balancing the potential harm of a given imaging test against its potential benefits. Acknowledging the potential benefits of imaging to find disease early on, Dr Smith-Bindman cautions that benefits must also be balanced against false-positive and false-negative findings, as well as radiation dose.

Appropriate Use Criteria

As of Jan. 1, 2023, appropriate use criteria built into qualified clinical decision support mechanisms will be federally mandated as part of the federal Protecting Access to Medicare Act. Dr Nicola expects that the benchmarking of clinicians' decision support via registries will become more

common, as will ongoing retrospective analyses of clinicians' ordering of imaging studies.

"There are certain system changes we can make to better control utilization," Dr Nicola says. "We have definitive use cases in the literature, especially through R-SCAN initiatives, showing how systems can reduce unnecessary imaging.

"In my own personal use, they have been beneficial," he adds. He notes, however,; that an imaging appropriateness score is one variable among many that factor into whether an imaging study is ultimately ordered for a patient. Collaborating on imaging utilization initiatives is an excellent opportunity for radiologists to engage with referring colleagues as part of the healthcare team.

A lack of formal training in imaging utilization across all phases of medical education could be at fault for low incorporation of ACR appropriateness criteria in radiology practices, according to a recent study[4] in *Current Problems in Diagnostic Radiology*. Researchers found that nearly 20% of medical students weren't familiar with the ACR imaging guidelines.

Other experts, including Dr Smith-Bindman, cite a lack of evidence supporting the appropriateness criteria for their lack of widespread adoption.[5]

It's also worth noting, Dr Nicola says, that issues related to imaging utilization extend beyond efficacy and patient outcomes. While radiologists can play the role of "arbiter of appropriateness," he says, "the fact is, imaging brings in income. The incentives [of our current system] are not aligned to control imaging utilization."

Underutilization Is Also Important

Beyond high-visibility issues like overutilization, Dr Nicola says, providers must also be careful not to overlook the significance of imaging underutilization, particularly as it relates to screening among low-income, at-risk populations.

"The two most robust screening programs we have in radiology are for breast and lung cancer," he says. "For socioeconomic reasons, we see many patients not being exposed to these studies, which means we're missing opportunities to detect cancers at an earlier, more treatable stage."

"Health equity is a real concern … as are the financial implications of late-detected cancers for the entire healthcare system," he says.

A Promising Future for Imaging Providers and Patients

Issues of imaging utilization likely will prompt debate among providers, payers, and government officials for some time to come. Indeed, areas for improvements in utilization, cost, and appropriateness remain. But most experts anticipate a future of data-supported radiologic decision-making to yield optimal outcomes at lower cost.

"Clinical radiology research always seems to focus on accuracy: can we find the disease rather than what happens to the patient because of it. It's my hope that studies, moving forward, will address how patients are improved in terms of their outcomes using imaging tests," Dr Smith-Bindman says.

That promises benefits for patients and providers alike. "At the core of value-based care, financial incentives are tied directly to patient outcomes and improvements in population health," Dr Nicola says. "As we evolve in that direction, the need for more outcomes data will no longer be aspirational, but intrinsic to how healthcare is provided in the future."

References

1) https://www.uhcprovider.com/en/reports-quality-programs/designated-diagnostic-provider/designated-diagnostic-provider-imaging.html. Accessed February 17, 2022.

2) https://www.healthimaging.com/topics/healthcare-economics/unitedhealthcare-program-low-cost-imaging-centers. Accessed February 17, 2022.

3) https://www.nejm.org/doi/pdf/10.1056/nejmoa1404446. Accessed February 17, 2022.

4) https://www.sciencedirect.com/science/article/abs/pii/S0363018822000093. Accessed February 17, 2022.

5) https://jamanetwork.com/journals/jamainternalmedicine/article-abstract/2477123. Accessed February 17, 2022.

Differentiating Focal Liver Lesions: ICC and HCC

David S Summerlin, MD; Kristin K Porter, MD, PhD

Case Summary

Case 1: A middle-aged adult presented with a history of generalized pruritus followed by development of jaundice one to two weeks after pruritus onset. Laboratory evaluation revealed elevated aspartate aminotransferase (AST), alanine aminotransferase (ALT), alkaline phosphatase (ALP), and total bilirubin.

Case 2: An elderly adult with a history of cirrhosis and mildly elevated liver enzymes presented for evaluation of indeterminate liver lesion identified on routine screening examination.

Imaging Findings

Contrast-enhanced magnetic resonance imaging (CEMRI) of the liver was performed in both cases. In case 1, imaging with an intracellular contrast agent revealed a large mass centered in the left hepatic lobe demonstrating arterial peripheral hyperenhancement with centripetal fill-in on transitional and hepatobiliary phase imaging. In case 2, imaging with an extracellular contrast agent demonstrated a lesion in the inferior right hepatic lobe with non-rim arterial hyperenhancement with central washout and rim enhancement on the portal venous phase.

Affiliation: University of Alabama at Birmingham, Birmingham, Alabama.

Diagnosis

Case 1: Intrahepatic cholangiocarcinoma (ICC)

Case 2: Hepatocellular carcinoma (HCC)

Discussion

While ultrasound remains the primary screening modality for hepatic malignancy, CEMRI of the liver is a valuable and complementary tool in evaluating indeterminate liver lesions. Differentiating hepatic lesions in cirrhosis can be challenging, both in part because of altered physiology within the cirrhotic liver, as well as a lack of unique, diagnostic features of various lesions— specifically intrahepatic cholangiocarcinoma (ICC) versus hepatocellular carcinoma (HCC), or combined tumor HCC-CC. There is also significant overlap in patient populations, as cirrhosis is associated with an increased risk of HCC. However, many factors that predispose a patient to cirrhosis are also associated with increased risk of ICC, including viral hepatitis and heavy alcohol use.

MRI contrast agents in hepatic imaging can be broadly divided into either extracellular or intracellular. Extracellular agents allow not only assessment of vascular flow kinetics but also vascular permeability. Iodinated contrast in computed tomography (CT) acts similarly physiologically and provides similar diagnostic information in liver imaging; however, its use may be limited in cases of renal dysfunction.

Intracellular contrast agents in hepatic imaging. meanwhile, distribute into the vascular and extravascular spaces during the arterial and delayed dynamic phases, and then progressively distribute into the hepatocytes and bile ducts during the hepatobiliary phase.

Intracellular contrast agents are often helpful in characterizing liver lesions based on the presence or absence of intralesional hepatocytes, as approximately 50% of the contrast is taken up by functioning hepatocytes and excreted into the biliary system.[1] However, as functioning hepatocytes are required for uptake of intracellular agents, patients with cirrhosis can have reduced uptake, resulting in reduced lesion conspicuity.[2] Cholestasis can also impact uptake and excretion of intracellular agents, also decreasing lesion conspicuity.

Marked fibrosis and iron overload conditions may result in heterogeneous parenchymal enhancement in the hepatobiliary phase. This reduces

background contrast and lesion detectability, particularly in poorly marginated lesions such as infiltrative HCC. In addition, confluent fibrosis can be misidentified as HCC, since both HCC and confluent fibrosis appear hypointense on the hepatobiliary phase.

In contrast to their extracellular counterparts, intracellular agents do not have a conventional delayed vascular phase. Instead, a transitional phase overlaps with the portal venous and hepatobiliary phases. Intralesional signal intensity on the transitional phase is not well understood and has not been sufficiently characterized, potentially leading to misinterpretation.

As such, lesion washout should only be evaluated on the portal venous phase when an intracellular contrast agent is used. Background liver enhancement on the transitional phase also limits sensitivity to capsular enhancement. Additionally, in the arterial phase, intracellular agents have been found to demonstrate weak arterial hyperenhancement at approved doses and may also result in a relatively high frequency of artifact related to transient dyspnea.[3]

Despite the limitations of intracellular agents in HCC, studies have demonstrated that adding a hepatobiliary phase can improve per-lesion sensitivity for HCC diagnosis by 6%-15%. Unequivocal HCC diagnosis with an extracellular contrast agent requires arterial hyperenhancement with washout or capsule appearance; however, up to 40% of HCC lesions may not be arterially hyper-enhancing. Only lesions with significant neoangiogenesis will demonstrate arterial hyperenhancement with extracellular contrast agents, potentially limiting early HCC detection.

Additionally, poorly differentiated and infiltrative HCC may also demonstrate weak arterial hyperenhancement. For example, small, indeterminate, arterially enhancing nodules are suspicious for malignancy (HCC vs ICC) if, after excluding a hemangioma, the lesion remains hypointense on the hepatobiliary phase.

An intracellular agent can also help differentiate HCC from hypervascular pseudolesions such as focal perfusion alterations, since pseudolesions enhance similarly to background liver on hepatobiliary phase while HCC is typically hypointense. Although HCC is typically hypointense on hepatobiliary phase, a small subset of moderately and well-differentiated HCC may be isointense or hyperintense on hepatobiliary phase, leading to potential diagnostic confusion. In addition to the diagnostic utility of a hepatobiliary contrast agent, research suggests that intracellular agents may also provide important prognostic information regarding tumor biology, including tumor grade and microvascular invasion.[3]

Prior studies have demonstrated no unique imaging findings to either HCC or ICC; however, several significant imaging features are statistically more likely to be seen in HCC versus ICC or combined tumor HCC-CC. These include lesion washout, presence of a capsule, and intralesional fat. Features more commonly seen in ICC and combined tumors include peripheral arterial phase hyperenhancement and progressive central enhancement. LI-RADS, the liver imaging reporting and data system, incorporates several of these features into major and ancillary findings to help differentiate HCC from non-HCC malignancy.[4]

Distinguishing HCC from ICC is useful not just prognostically, but also in guiding patient management. Although pathologic confirmation with tissue sampling is often necessary, imaging plays an important supplementary role. While a solitary HCC lesion may not exclude liver transplantation in an otherwise eligible patient, a solitary ICC lesion may be considered a contraindication

Figure 1. (A) T1, fat-saturated precontrast image demonstrates a large hypointense mass centered in the left hepatic lobe. (B) T1, fat-saturated arterial phase image following intracellular contrast administration demonstrates peripheral/rim enhancement of the mass. (C) T1, fat-saturated portal venous delayed phase image following intracellular contrast administration demonstrates progressive centripetal enhancement of the mass.

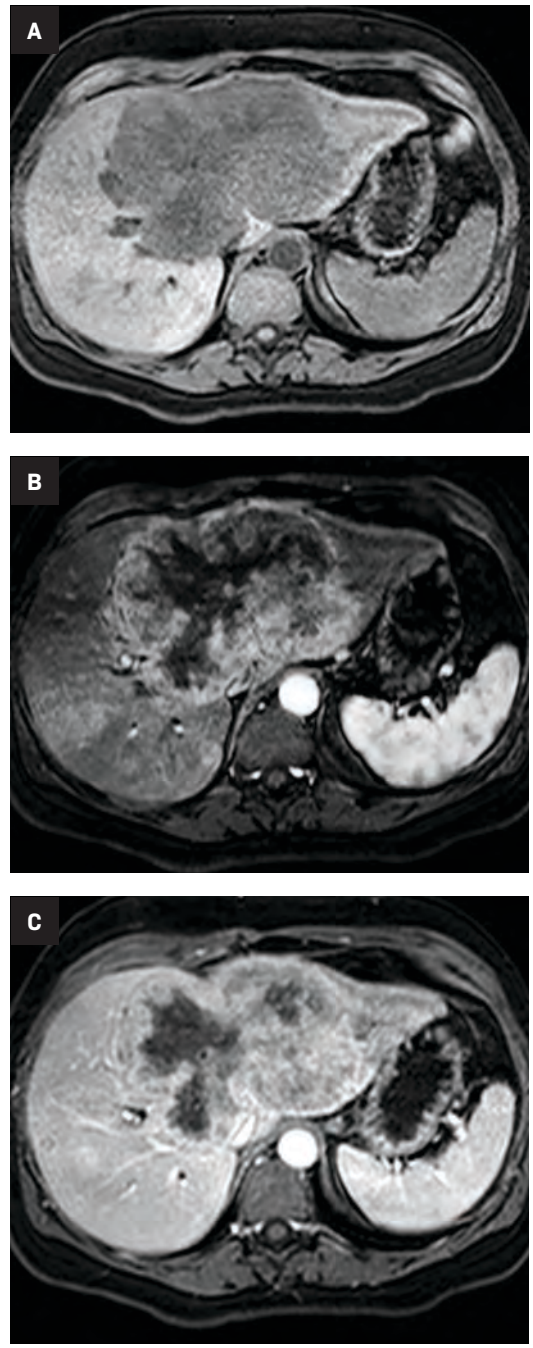

Figure 2. (A) T1, fat-saturated precontrast image demonstrates a small hypointense lesion centered in the inferior right hepatic lobe. (B) T1, fat-saturated arterial phase image following extracellular contrast administration demonstrates uniform, non-rim enhancement of the lesion. (C) T1, fat-saturated portal venous phase image following extracellular contrast administration demonstrates central washout of the lesion with an enhancing capsule.

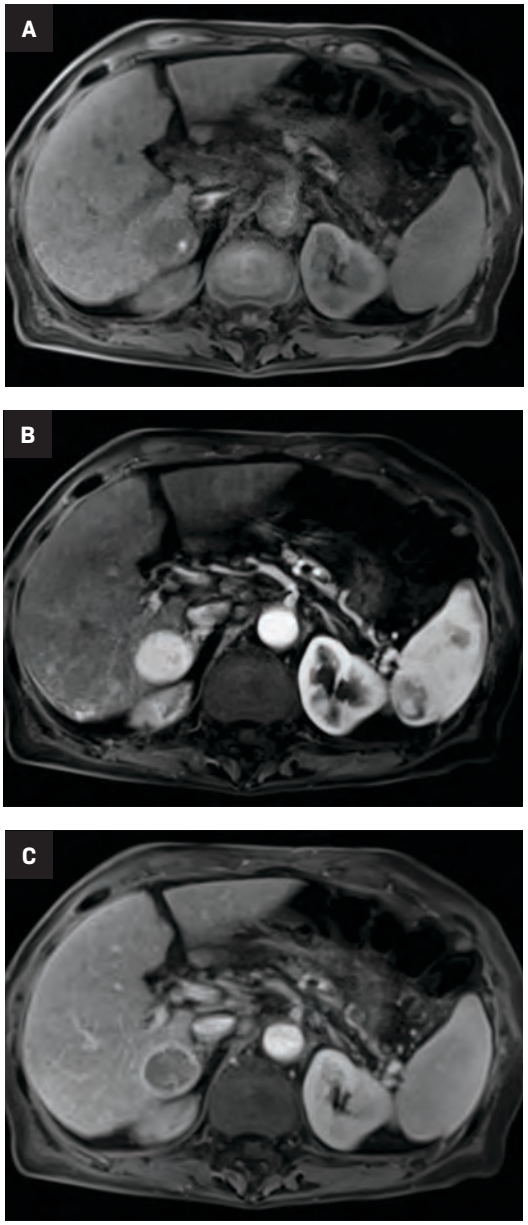

to liver transplantation. Researchers, however, have begun to question this approach, noting retrospective data that suggests early transplantation for a solitary ICC lesion up to 2 cm in size may achieve up to 70% 5-year survival.[5] Prospective trials may be needed to confirm these findings before a change in standard clinical practice is likely.

Given the importance of lesion size in guiding treatment strategies such as liver transplantation, early detection is critical. MRI or CT surveillance may be indicated in patients for whom ultrasound is limited by body habitus, steatosis, or severe parenchymal heterogeneity related to advanced cirrhosis. MRI surveillance of the liver has shown promise in the PRIUS trial, a prospective cohort study in which MRI provided significantly higher early HCC detection and fewer false positives compared to ultrasound. Given the prohibitive cost and scanning time with routine protocols, some institutions have evaluated the efficacy of an abbreviated MRI protocol and demonstrated higher sensitivity and specificity in early HCC detection.[6]

Conclusion

Contrast-enhanced MRI of the liver is an important diagnostic tool in the evaluation of indeterminate liver lesions. Though not routinely used for surveillance in high-risk patients, MRI or CT surveillance may be indicated where ultrasound is limited. Knowledge of the various gadolinium-based contrast agents and their physiologic properties and inherent limitations is important in selecting an appropriate diagnostic examination. Liver imaging is critical in guiding development of a treatment strategy for hepatic malignancy. Although pathologic confirmation with tissue sampling is usually necessary, MRI of the liver provides an opportunity for early detection of small lesions and may help differentiate HCC and ICC. Additionally, research has shown the ability to obtain potential prognostic information based on characterization of tumor biology.

References

1) Choi JY, Lee JM, Sirlin CB. CT and MR imaging diagnosis and staging of hepatocellular carcinoma: part I. Development, growth, and spread: key pathologic and imaging aspects. *Radiology*. 2014;272(3):635-654.

2) Kim SY, Wu EH, Park SH, et al. Comparison of hepatocellular carcinoma conspicuity on hepatobiliary phase images with gadoxetate disodium vs. delayed phase images with extracellular cellular contrast agent. *Abdom Radiol* (NY). 2016;41(8):1522-1531.

3) Choi JY, Lee JM, Sirlin CB. CT and MR imaging diagnosis and staging of hepatocellular carcinoma: part II. Extracellular agents, hepatobiliary agents, and ancillary imaging features. *Radiology*. 2014;273(1):30-50.

4) Tang A, Bashir MR, Corwin MT, et al. Evidence supporting LI-RADS major Features for CT- and MR imaging-based diagnosis of hepatocellular carcinoma: A systematic review. *Radiology*. 2018;286(1):29-48.

5) Mazzaferro V, Battiston C, Sposito C. Pro (with caution): Extended oncologic indications in liver transplantation. *Liver Transpl*. 2018;24(1):98-103.

6) Kanwal F, Singal AG. Surveillance for hepatocellular carcinoma: Current best practice and future direction. *Gastroenterology*. 2019;157(1):54-64.

Dural Arteriovenous Fistula

Sherif Moawad, MD; Ahmed Farag, MD; Ahmad Kattan, MD; Mark Buehler, MD

Case Summary

An adult presented to the emergency department with vertigo, headache, and a four-day history of vision changes. Previous medical history included transient ischemic attack, right internal carotid aneurysm, remote stroke, chronic sinusitis, hypertension, diabetes, and remote traumatic brain injury.

Affiliations: University of Alabama at Birmingham, Birmingham, Alabama (Drs Moawad, Farag), University of Toledo Medical Center, Toledo, Ohio (Drs Kattan, Buehler)

Imaging Findings

Computed tomography angiography (CTA) demonstrated expansion and arterial phase enhancement of the right cavernous sinus and retrograde filling of the right superior ophthalmic vein. A 3D reconstruction revealed early filling of the right sigmoid sinus on the arterial phase (Figure 1). Magnetic resonance imaging demonstrated increased T2 FLAIR signal within the right cavernous sinus (Figure 2).

Digital subtraction angiography (DSA) was negative for a carotid-cavernous fistula but demonstrated a dural arteriovenous fistula (DAVF) between the right occipital artery and right sigmoid sinus. The terminal branches of the right middle meningeal artery were also communicating with the DAVF (Figure 3). The drainage through this sinus, however, remained anterograde (Borden type I AV fistula).

Diagnosis

Dural arteriovenous fistula (DAVF)

Figure 1. Axial CTA (A) image shows contrast enhancement of the expanded right cavernous sinus (arrow). 3D reconstruction (B) shows early filling of the right sigmoid sinus during arterial phase (arrows) and the small internal carotid aneurysm (arrow head).

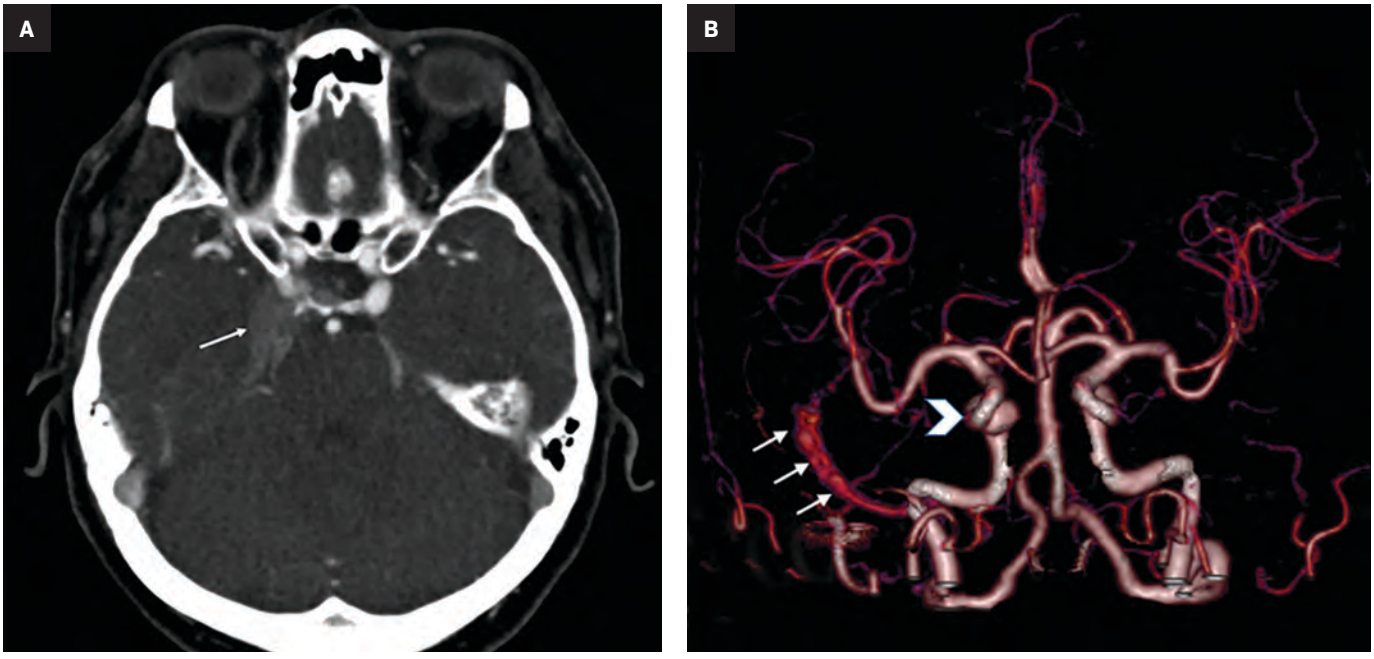

Figure 2. Noncontrast axial T2 FLAIR showing abnormally high signal in the expanded right cavernous sinus (arrow).

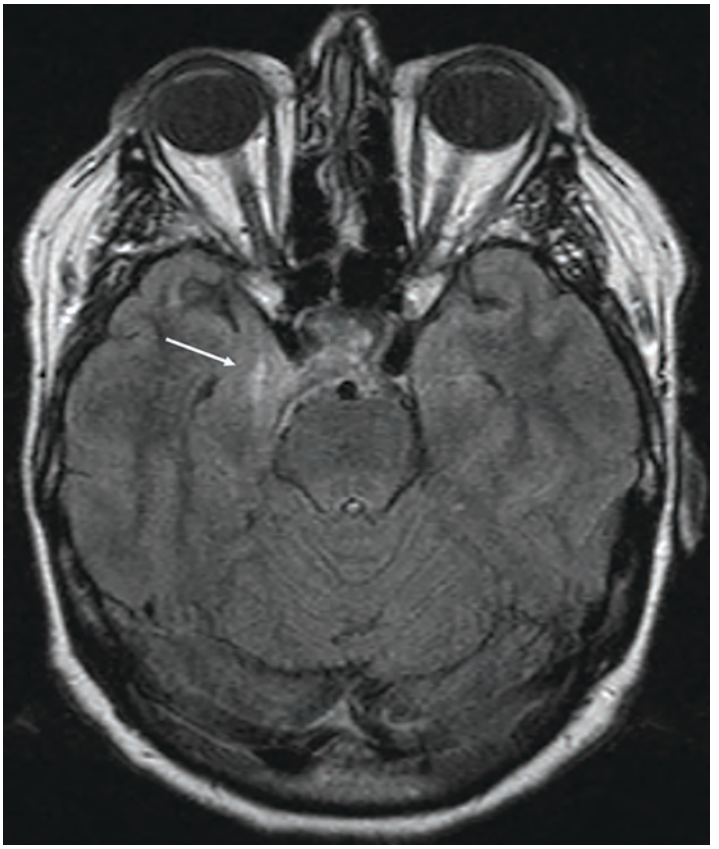

Discussion

Intracranial DAVFs are pathologic shunts occurring between the dural arteries and the venous sinuses, meningeal veins, or cortical veins; they account for 10%-15% of all intracranial malformations.[1] The transverse, sigmoid, and cavernous sinuses are common locations for most DAVFs.[2] Symptoms may include tinnitus, diplopia, ocular pain, exophthalmos, and intracranial hemorrhage. Low-grade DAVFs are usually benign, with a reported 2% rate of conversion to aggressive.[3] We present a case of DAVF which was treated with endovascular embolization and open surgery.

The severity of DAVF symptoms is determined by the venous drainage pattern. There are two classification schemes, Borden, et al, and Cognard, et al (Tables 1 and 2).[4,5] The Borden classification, more frequently used clinically, classifies lesions based on the site of venous drainage and the presence of cortical venous drainage (CVD). The Cognard classification, however, is more anatomic and imaging oriented. It is based on the

Figure 3: DSA from a right common carotid artery injection (A) shows the DAVF with arterial supply from right middle meningeal and occipital arteries (white arrows). A right 8.5 x 6.5 mm cavernous segment internal carotid artery aneurysm is also visualized (black arrow). Early-arterial phase (B) shows filling of the sigmoid sinus through right occipital artery feeding branch (dotted circle).

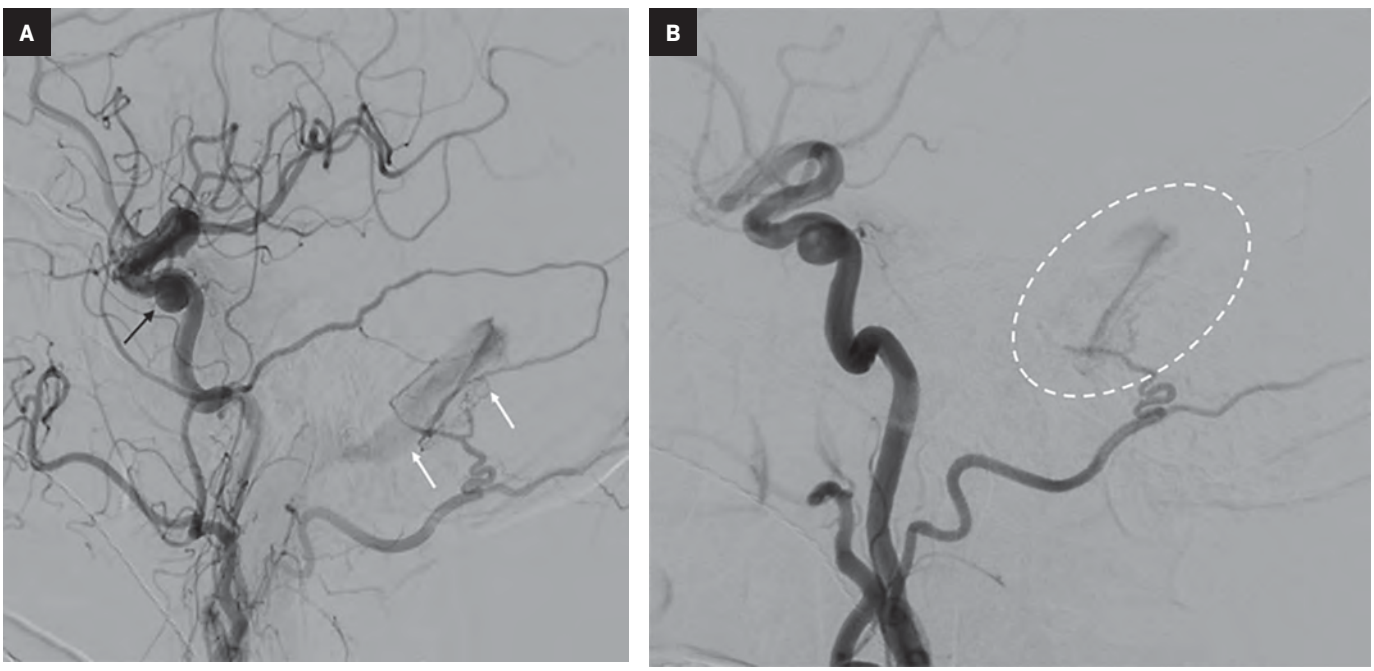

Table 1: Borden Classification of DAVF

TYPE	DESCRIPTION
I "Benign"	Drainage into dural venous sinus or meningeal vein
II	Drainage into dural venous sinus and cortical venous drainage
III	Direct drainage into a cortical vein

Table 2: Cognard Classification of DAVF

TYPE	VENOUS DRAINAGE
I	Anterograde sinus drainage
II a	Retrograde sinus drainage
II b	Retrograde CVR
II a+b	Retrograde sinus drainage and CVR
III	CVR only without venous ectasia
IV	CVR only with venous ectasia
V	Spinal venous drainage

direction of dural sinus drainage, presence of CVD, and venous outflow architecture. In both classifications, the lack of CVD is associated with a benign course and an extremely low risk of intracranial hemorrhage.[6] DAVF has a dynamic nature and can convert into a more aggressive type or undergo spontaneous resolution.[7] A change in symptoms requires reevaluation, as it may reflect exacerbation of the venous drainage pattern. Further subdivision of aggressive types in both classifications into symptomatic and asymptomatic improves the accuracy of risk stratification, as demonstrated by Zipfel, et al.[6] The study revealed a significant difference in the annual hemorrhage risk between symptomatic and asymptomatic subtypes of 7.4% and 1.5%, respectively.[6] DAVF are initially evaluated with noncontrast CT and MRI. Any suspicious dilated vessels, venous pouches, or vascular enhancement should be further evaluated with CTA or MRA.[1] Four-dimensional (4D) CTA using a can accurately diagnose, classify, and assist in treatment planning for DAVF. A recent preliminary study showed an accuracy rate of 85.7% using 4D CTA to detect DAVF feeding arteries.[8] However, DSA remains the most accurate method for DAVF detection and classification.

Endovascular therapy is the mainstay of treatment. Nevertheless, surgery, stereotactic radiosurgery, or combined approaches may be alternatives in cases of failed endovascular therapy, as in this case. Owing to a sharp turn at its origin, the occipital artery was not accessible endovascularly. The aim of endovascular treatment is to completely eliminate the arteriovenous shunt to prevent recruitment of collaterals and persistent risk of hemorrhage.[9] Surgical options include direct intraoperative embolization of meningeal arteries or veins, dural resection, venous sinus packing, and skeletonization of the dural sinus with disconnection of the dural arterial supply. A combined approach employing presurgical arterial embolization is reported 100% efficient in DAVF ablation. However, mortality and morbidity risks remain considerable (>10%).[10]

Conclusion

Dural arteriovenous fistulas are uncommon; CTA is effective for diagnosis and follow-up. Three-dimensional reconstructions offer a dynamic look at the fistula and its feeding arteries. However, it remains less sensitive than DSA. Endovascular embolization is the gold standard for DAVF treatment. Surgery is considered in cases where endovascular approaches have failed or are not feasible.

References

1) Kwon BJ, Han MH, Kang HS, et al. MR imaging findings of intracranial dural arteriovenous fistulas: relations with venous drainage patterns. *Am J Neuroradiol.* 2005;26: 2500–2507.

2) Kirsch M, Liebig T, Kuhne D, et al. Endovascular management of dural arteriovenous fistulas of the transverse and sigmoid sinus in 150 patients. *Neuroradiology.* 2009; 51:477–483.

3) Satomi J, van Dijk JM, Terbrugge KG, et al. Benign cranial dural arteriovenous fistulas: outcome of conservative management based on the natural history of the lesion. *J Neurosurg.* 2002;97:767–770.

4) Borden JA, Wu JK, Shucart WA. A proposed classification for spinal and cranial dural arteriovenous fistulous malformations and implications for treatment. *J Neurosurg.* 1995;82:166–179.

5) Cognard C, Gobin YP, Pierot L, et al. Cerebral dural arteriovenous fistulas: clinical and angiographic correlation with a revised classification of venous drainage. *Radiology* 1995;194:671–680.

6) Zipfel GJ, Shah MN, Refai D, et al. Cranial dural arteriovenous fistulas: modification of angiographic classification scales based on new natural history data. *Neurosurg Focus.* 2009;26:E14.

7) Luciani A, Houdart E, Mounayer C, et al. Spontaneous closure of dural arteriovenous fistulas: report of three cases and review of the literature. *Am J Neuroradiol.* 2001;22:992–996.

8) Tian B, Xu B, Lu J, et al. Four-dimensional computed tomography angiographic evaluation of cranial dural arteriovenous fistula before and after embolization. *Eur J Radiol.* 2015;84;1144-1149.

9) Mironov A. Selective transvenous embolization of dural fistulas without occlusion of the dural sinus. *Am J Neuroradiol.* 1998;19:389-391.

10) Kakarla UK, Deshmukh VR, Zabramski JM, et al. Surgical treatment of high-risk intracranial dural arteriovenous fistulae: clinical outcomes and avoidance of complications. *Neurosurgery.* 2007;61:447–459.

Endovascular Retrieval of Transthoracic Right Atrial Catheter Fragment

Lavi Nissim, MD; David J Aria, MD; Scott Willard, MD; Alexander J Towbin, MD; Richard B Towbin, MD

Case Summary

An infant with Trisomy 21 underwent surgical repair of a large membranous ventricular septal defect (VSD). During surgery, the anesthesiologist noted difficulty intubating beyond the cricoid cartilage. Ultimately, intubation was performed using a 3.0 mm endotracheal tube without inflating the cuff. Postoperatively, the hospital course was complicated by a chylous pericardial effusion and multiple episodes of respiratory failure requiring bronchoscopy-assisted intubation. At the time of bronchoscopy, a tracheal ring was identified and subsequently treated with a tracheoplasty.

While the patient was on cardiopulmonary bypass, a 5-French dual lumen transthoracic right atrial catheter was placed. The catheter was secured with a purse-string prolene suture at the right atrial insertion site, as well as a silk suture at the skin exit site. Seven weeks later, the catheter was removed at the bedside. It was immediately noted the catheter had fractured and a long, retained catheter fragment was seen on a post procedural chest radiograph (Figure 1). The retained fragment was subsequently removed with a fluoroscopically guided endovascular snare (Figure 2).

Affiliations: Department of Radiology at Phoenix Children's Hospital, Phoenix, AZ (Drs Nissim, Aria, Willard, R Towbin); Department of Radiology, Children's Hospital Medical Center, University of Cincinnati College of Medicine, Cincinnati, Ohio (Dr A Towbin).

Imaging Findings

A postoperative chest radiograph demonstrated a right atrial catheter with its tip coursing into the common hepatic vein. On a chest radiograph performed after catheter removal, a residual catheter fragment was seen with its tip in the inferior vena cava (Figure 1). Endovascular retrieval with a loop-snare device was successfully performed (Figure 2). Post-retrieval venography demonstrated no extravasation or vascular injury.

Diagnosis

Retained fragment of a transthoracic right atrial catheter. Differential diagnosis includes right atrial pacing wire, migration of peripherally inserted central catheter fragment into right atrium.

Discussion

Children requiring long-term central venous access present a challenge for clinicians, who must weigh concerns of complications such as venous thrombosis, infection, and catheter malfunction. In addition, in children with congenital heart abnormalities, the need for venous access must be balanced with the necessity for venous conservation for drug therapy and laboratory studies, and to preserve options for future corrective surgery, such as a superior vena cava to pulmonary artery (Glenn) shunt.[1,2] Alternatives to upper- or lower-extremity venous access have been well described in the literature. They include transhepatic access, trans-lumbar access, and direct puncture into the brachiocephalic, intercostal, or other collateral veins.[3]

Though far less frequent, direct insertion of a central venous catheter into the right atrium is an attractive option in patients undergoing thoracic surgical procedures, especially those with limited central venous access. Venous conservation is especially important in children who require long-term parenteral nutrition or who are candidates for organ transplant.[4,5]

Figure 1. (A) Portable chest radiograph demonstrating transthoracic right atrial catheter, tip in the inferior vena cava (IVC, arrow). (B) Portable chest radiograph performed after catheter removal shows a retained catheter fragment coursing from right atrium into the IVC (arrow).

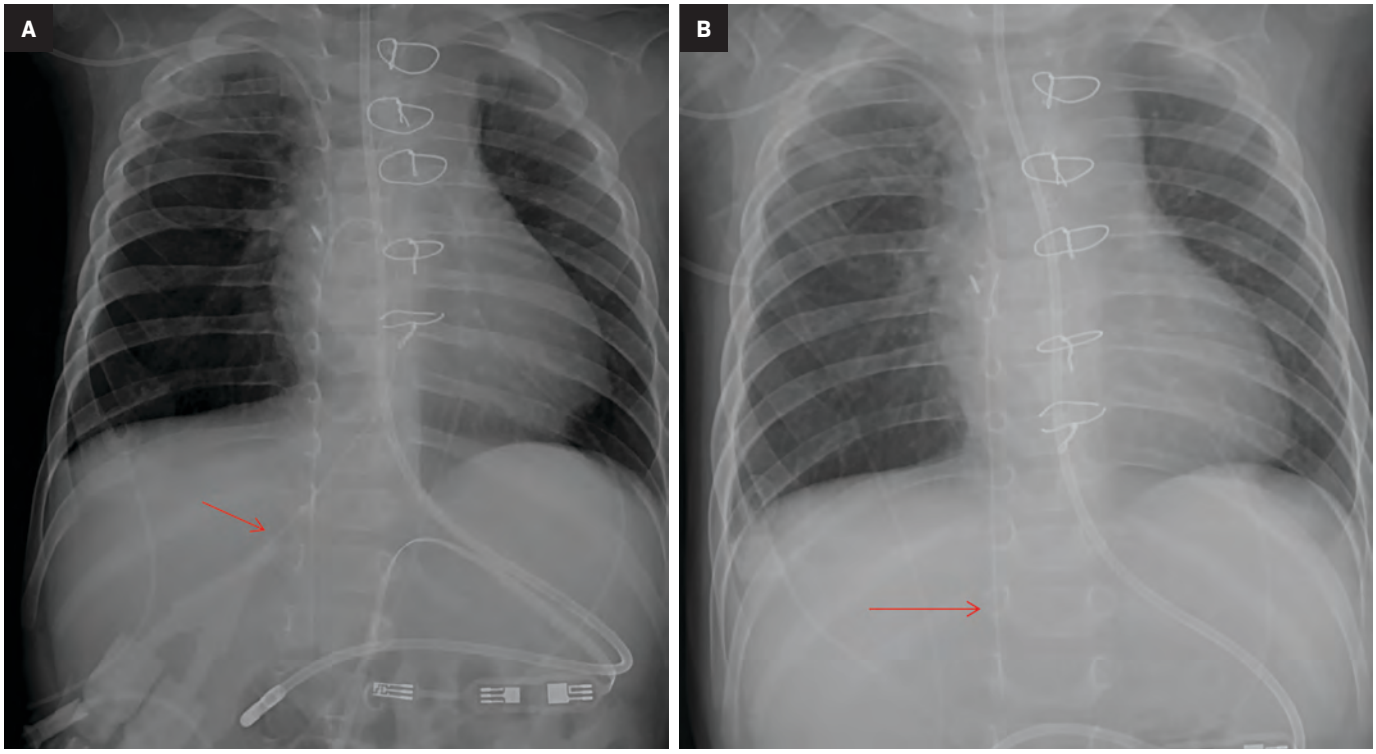

Initial experience with direct catheter placement into the right atrium was reported approximately 40 years ago.[6] In our institution, intracardiac catheters are placed only at the time of open-heart surgery and are secured to the right atrium with a purse-string suture and to the skin using a non-absorbable suture. Catheters are removed at the bedside using gentle traction, without specific methodology to prevent bleeding or catheter fracture.

Several studies have examined the feasibility and safety of transthoracic intracardiac catheters. A large series evaluating placement of 523 such catheters in 351 patients found a high rate of bleeding (36.7%) with catheter removal, including hemodynamic compromise in 2.6% of patients.[7] Another large study evaluated 1404 intracardiac central catheters inserted in 1118 patients. Of these, 8 patients (0.6%) required intervention for life-threatening bleeding, 6 because of line migration and 2 after catheter removal.[8] Kumar, et al, found that catheter migration was less likely with patients

Figure 2. Endovascular loop-snare retrieval of the catheter fragment using right femoral approach.

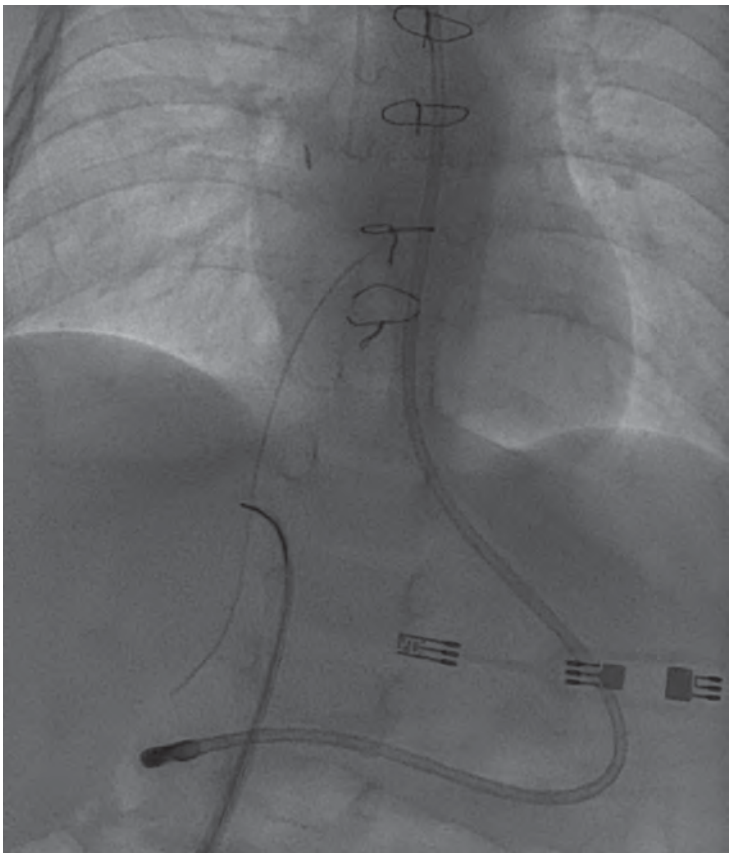

having upper transthoracic insertion (above suprasternal notch) as opposed to lower insertion (inserted below diaphragm).[9]

Conclusion

Long-term central venous access in infants for drug infusion or parenteral nutrition, or in those with chronic conditions may require alternatives to routine extremity venous access. Direct intracardiac catheter insertion has been described, particularly via transthoracic approach, as an alternative for access in these patients. While RA catheter use is infrequent in the general population, it is often used postoperatively in children with congenital heart disease. Studies have documented several risks associated with intracardiac catheter use, particularly development of bleeding after catheter removal and catheter fracture. Retained fragments of catheter fractures can be removed using a transvenous, fluoroscopically guided endovascular snare.

References

1) Stein ML, Quinonez LG, DiNardo JA, Brown ML. Complications of transthoracic intracardiac and central venous lines in neonates undergoing cardiac surgery. *Pediatr Cardiol*. 2019 Apr;40(4):733-737.

2) Beham K, Dave H, Kelly J, Frey B, Hug MI, Brotschi B. Transthoracic intracardiac catheters in pediatric cardiac patients: A single-center experience. *Paediatr Anaesth*. 2017 Sep;27(9):918-926.

3) Tannuri U, Tannuri AC, Maksoud JG. The second and third right posterior intercostal veins: an alternate route for central venous access with an implantable port in children. *J Pediatr Surg*. 2005 Nov;40(11):e27-30.

4) Detering SM, Lassay L, Vazquez-Jimenez JF, Schnoering H. Direct right atrial insertion of a Hickman catheter in an 11-year-old girl. *Interact Cardiovasc Thorac Surg*. 2011 Feb;12(2):321-323.

5) Birnbaum PL, Michas C, Cohen SE. Direct right atrial catheter insertion with video-assisted thoracic surgery. *Ann Thorac Surg*. 1996 Oct; 62(4):1197.

6) Oram-Smith JC, Mullen JL, Harken AH, Fitts WT Jr. Direct right atrial catheterization for total parenteral nutrition. *Surgery*. 1978 Mar;83(3):274-276.

7) Flori HR, Johnson LD, Hanley FL, Fineman JR. Transthoracic intracardiac catheters in pediatric patients recovering from congenital heart defect surgery: associated complications and outcomes. *Crit Care Med*. 2000;28(8):2997-3001.

8) Pratap H, Millar J, Butt W, d'Udekem Y. Complications of intrathoracic lines placed during cardiac surgery. *J Thorac Cardiovasc Surg*. 2015; 149(4):1212-1213.

9) Kumar TKS, Subramanian S, Tansey JB, et al. Optimum position of transthoracic intracardiac line following cardiac surgery. *Interact Cardiovasc Thorac Surg*..2017; 25(6):883-886.

Metastatic Neuroblastoma

Amanda L Schaaf; Richard B Towbin, MD; Carrie M. Schaefer, MD; Alexander J. Towbin, MD

Case Summary

A young child presented with a 2-week history of intermittent fever and a 3-day history of a right shoulder mass. They had visited a primary care physician twice in the eight days prior to hospital admission. The first visit occurred eight days prior to admission and was for fussiness, headache, neck pain, fever, right knee pain, and some difficulty ambulating. During this visit, bloodwork showed low hemoglobin (10.8 g/dL), elevated platelets (480 x 10^9/L), and LDH (400 units/L). The second visit occurred one day prior to admission and was for the right shoulder mass.

Imaging Findings

Right shoulder radiographs showed an irregular contour of the right scapula with geographic bone destruction of the scapula and acromion, periosteal new bone formation along the medial scapula and a soft tissue mass projecting superior to the right clavicle (Figure 1). Magnetic resonance imaging (MRI) of the shoulder showed abnormal marrow signal in the right scapula and proximal humerus. In addition, there was a 6.0 cm extraosseous soft tissue mass (Figure 2). Chest CT demonstrated a destructive lesion in the right scapula that correlated with the appearance of the scapula abnormalities on the radiographs and MRI. The bone changes were associated with a large, soft tissue mass along the superior and posterior borders of the scapula (Figure 3). There were also multiple pulmonary masses and a 3.8 cm left-adrenal mass containing multiple calcifications (not shown).

Affiliations: University of Arizona College of Medicine-Phoenix (Ms. Schaaf), Phoenix Children's Hospital (Drs R Towbin, Schaefer); Cincinnati Children's Hospital and Cincinnati College of Medicine (Dr A Towbin).

Histopathological Findings

Percutaneous biopsy of the right scapular mass revealed a poorly differentiated metastatic neuroblastoma with an intermediate mitosis-karyorrhexis index. Concurrent bone marrow biopsy was also positive for metastatic tumor.

Diagnosis

Metastatic neuroblastoma.

The differential diagnosis includes Ewing sarcoma, lymphoma, and undifferentiated soft-tissue sarcomas such as rhabdomyosarcoma.

Discussion

Neuroblastoma is a tumor of neural crest origin.[1] Although rare, neuroblastoma accounts for 7% of cancers and 15% of cancer death in children.[2] It is the most frequently diagnosed solid tumor in children with 95% of all diagnoses made before five years of age.[1] The early age at diagnosis suggests that prenatal factors may play a role in tumor development.[1] Several studies have identified potential parental risk factors associated with development of neuroblastoma in offspring. These potential risks include maternal alcohol consumption and/or tobacco use during pregnancy; parental occupations that include exposures to electromagnetic fields, pesticides, or hydrocarbons; and certain medications taken during pregnancy such as oral contraceptives, hormones, diuretics, or codeine.[1]

Several types of gene expression and chromosomal abnormalities have been found to play a role in the emergence of and pathogenesis of neuroblastoma.[1] The MYCN oncogene is perhaps the most important chromosomal risk factor. It is amplified in at least 20% of patients with neuroblastoma. MYCN amplification is more common in patients with Stage 4 disease and is correlated with more rapid tumor growth and worse survival rates.[3] Other genes involved in neuroblastomas are TRK, CD44, and ALK.

Neuroblastoma can occur anywhere along the sympathetic nervous system from neck to pelvis. However, 65% of tumors are abdom-

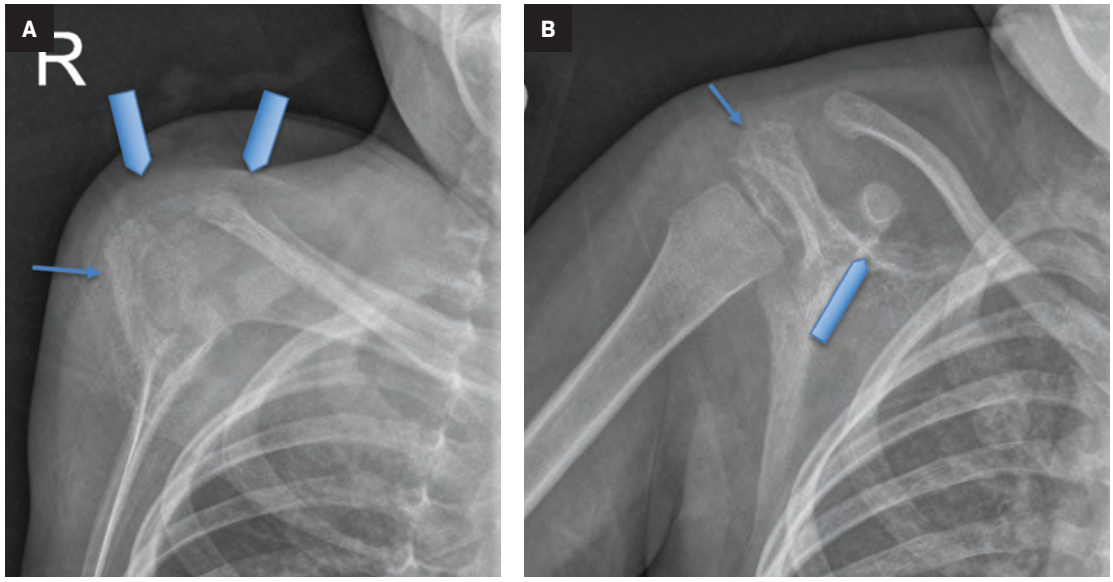

Figure 1. (A) Y-view of the right scapula shows an irregular contour of the medial aspect of the right scapula with a moth-eaten destruction (thin arrow) of the acromion and superior scapula. A soft-tissue mass (thick arrows) projects superior to the right clavicle. (B) External rotation radiograph shows a soft-tissue mass (thick arrow) and destruction (thin arrow) of the superior scapula and acromion process.

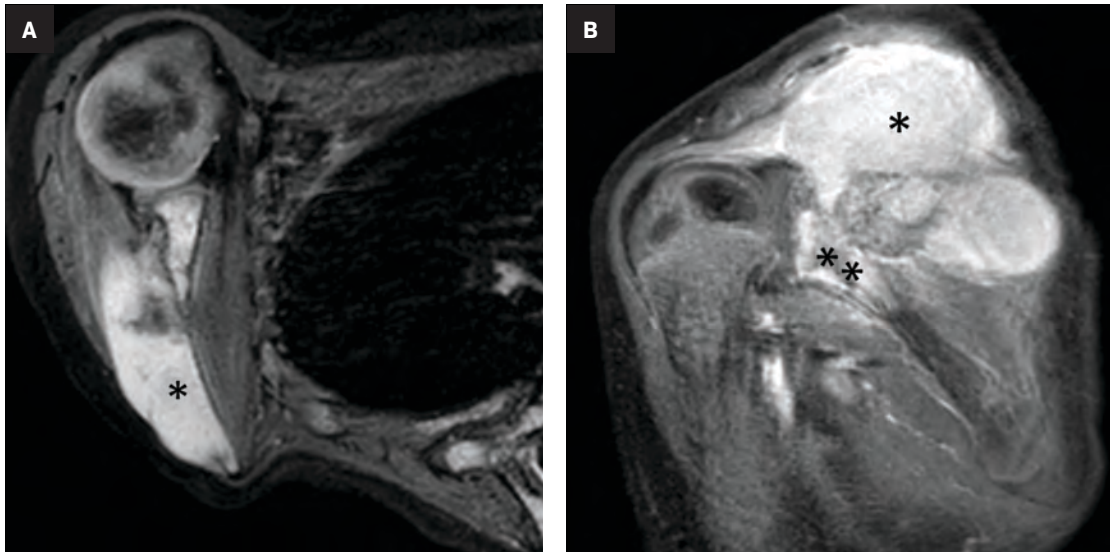

Figure 2. MR imaging of the right shoulder shows T1 hypointensity (A) and T2 hyperintensity (B) of the right scapula, as well as mottled T1 hypointensity and T2 hyperintensity of the proximal humeral shaft. Bone marrow replacement (**) in the right scapular was also observed, with a 6.0 x 5.9 x 3.2 cm extraosseous soft-tissue mass (*). Given the adrenal mass, metastatic neuroblastoma was a favored diagnosis.

inal and 46% arise from the adrenal gland. Symptoms depend on size and location of the mass. Most patients present with a palpable abdominal mass and/or abdominal distension.[3,4] Children may have symptoms related to constipation or hypertension.[3] Tumors present in the chest may cause scoliosis or airway compression.[3] Paraspinal tumors that invade the spinal canal can cause neurological symptoms and signs such as pain, motor or sensory deficits, and Horner syndrome.[3] Although rare, pulmonary metastases may occur.[5]

Metastases occur in 40% of patients.[1] Bone and bone marrow are the most frequent sites of metastasis; bone marrow represents as much as 70% of metastatic sites in patients.[1,2,4] Other common metastatic sites include the liver and regional lymph nodes.[4] The majority of metastatic neuroblastoma patients present with systemic symptoms like fever, pain, and weight loss.[3]

Imaging plays a role in identifying metastatic disease. Skeletal metastases are often first identified via I-123 metaiodobenzylguanidine (MIBG) scintigraphy. Normally, there is no uptake of the radiotracer in bone. Therefore, bones visible on the planar images of an MIBG scan confirm the presence of metastatic disease. Occasionally, children present with other bone-related symptoms, such as a limp. Radiographs obtained for this indication may show lucent metaphyseal bands, geographic lucency, or a permeative appearance of the bone. Skull metastases may cause thickening and a periosteal reaction. Because bone metastases cannot be distinguished from marrow metastases, a bone marrow biopsy is part of the standard work-up in newly diagnosed cases of neuroblastoma.

MRI is commonly used to evaluate the primary tumor, to identify image-defined risk factors, and to

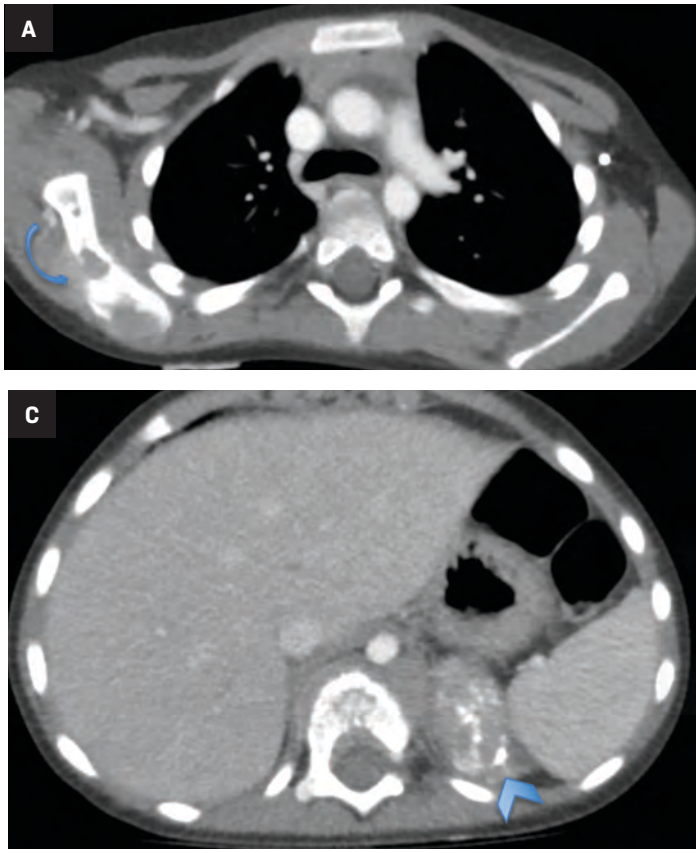

Figure 3. Axial CT of the chest (A) revealed a large destructive lesion in the right scapula, causing a moth-eaten appearance of the bone (curved arrow). (B) Coronal CT shows a large, soft-tissue mass (*) along the superior and posterior borders of the scapula. In addition, an oval-shaped soft-tissue lesion (chevron) with calcifications is present in the left suprarenal region.

determine local-regional spread of disease. While MRI can help to identify bone metastases, it is not often the primary modality for this purpose. This is because of the potential for widespread disease and the fact that bone changes lag behind functional changes. Consequently, MIBG, which allows for whole-body imaging and evaluates the functional nature of the tumor, is the preferred modality for diagnosis and follow-up of metastatic disease.

The prognosis for patients diagnosed with neuroblastoma depends on age at diagnosis, extent of disease, presence of image defined risk factors, tumor differentiations, MYCN amplification, and other chromosomal abnormalities. Patients with metastatic neuroblastoma can be stratified into low-, intermediate-, or high-risk groups.[6] Studies suggest that for low- and intermediate-risk patients, complete resection of the tumor is often unnecessary for recovery.[3] Patients of intermediate risk may receive chemotherapy to shrink their tumor before undergoing surgery.[3] For high-risk patients, treatment includes neoadjuvant chemotherapy, surgical resection, adjuvant high-dose chemotherapy, with hematopoietic stem cell rescue, and radiation therapy.[3] Low-risk patients have a 5-year event-free survival rate of 75-85%. This rate falls to 50-75% for patients with intermediate risk and less than 50% for children with high-risk disease.

Conclusion

Despite the rarity of neuroblastoma, it accounts for up to 15% of pediatric cancer fatalities.[3] Bone and bone marrow are two of the most common sites of metastasis.[3] The highly variable symptoms of neuroblastoma make diagnosis challenging, especially in patients with atypical symptoms. Although uncommon, neuroblastoma should be considered in the differential diagnosis of patients presenting with bone pain and protean systemic symptoms like fever.

References

1) Luksch R, Castellani MR, Collini P, et al. Neuroblastoma (Peripheral neuroblastic tumours). *Crit Rev Oncol Hematol.* 2016;107:163–181.

2) Chu CM, Rasalkar DD, Hu YJ et al. Clinical presentations and imaging findings of neuroblastoma beyond abdominal mass and a review of imaging algorithm. *Br J Radiol.* 2011; 84:81–91.

3) Swift CC, Eklund MJ, Kraveka JM, Alazraki AL. Updates in diagnosis, management, and treatment of neuroblastoma. *Radiographics.* 2018; 38:566–580. doi: 10.1148/rg.2018170132.

4) David R, Lamki N, Fan S, et al. The many faces of neuroblastoma. *Radiographics.* 1989; 9(5):859-882. doi:10.1148/radiographics.9.5.2678295.

5) Towbin R, Gruppo R: Pulmonary metastases in neuroblastoma. *Am J Roentgenol.* 1982; 138:75-78.

6) Cohn SL, Pearson AD, London WB, et al. The International Neuroblastoma Risk Group (INRG) Classification System: An INRG Task Force Report. *J. Clin. Oncol.* 2009;27:289–297. doi: 10.1200/JCO.2008.16.6785.

"Why do people always gesture with their hands when they talk on the telephone?"

—Jonathan Carroll

Hand Talkers

C Douglas Phillips, MD, FACR

I know you all. You're a smart bunch. You already know where this is going but you choose to keep reading. Perhaps you're interested in seeing where I go with it, maybe you have your own opinion, maybe you're working forward to the radiology angle? Or, maybe I'll just distract you with the quote. Ever think of that? That would be unfair, wouldn't it? Nope, we're going with this line of investigation.

Radiology hand talking.

As we've seen in life and famously prodded at by Seinfeld, we've got slow talkers, fast talkers, soft talkers, loud talkers, etc, etc. There are also hand talkers. Some are quite good at it; it can embellish a conversation, but it can also be a diversion, much like a magician getting you to look elsewhere while the action occurs to the side. I talk with my hands, but I would categorize myself as a somewhat limited gesturer. I use my hands more to distract you when I don't have anything particularly pithy to say instead of driving my point home with them.

I have been known to knock coffee over into a keyboard making a point on occasion, however. Not my finest day. Some people literally could not speak if their hands were tied. It's the broad, sweeping, grand gestures often involving the whole body that I'm talking about. You all know at least one person in this category. So, what if that person is a radiologist? Egads, what if it's you?

Okay, clinicians in the room gathered around your workstation? That's easy: Gesture away! Swing your arms, get up out of that chair! Entertain! Enlighten! Mystify!

But what about your radiology reports? How do you "gesture widely around the room" or "jam your finger repetitively at a lesion" in a report? I've done emojis before (and unfortunately we STILL do not have the ability to include them in our reports). But what about a gesture? Sure, there is a shrug emoji, but that's of limited utility for someone in constant motion working their arms, hands, and fingers to the rhythm of their diction. Emojis are a poor substitute for a dedicated, hardcore hand talker.

This question is more than rhetorical. I know a few serious hand talkers and I cannot look at their reports without imagining the hand motions that would accompany the text. Perhaps that's best; it's like the book that requires you to picture the events versus the movie that shows you the events — just maybe not the way you envisioned them.

In the meantime, I will continue to champion communication skills that we can all use with our current technology and wish for the day that emojis are welcome in reports. 🙂 You hand talkers are going to have to push for video reporting. Use a wide-angle lens.

Keep doing that good work. Mahalo.

Dr Phillips is a Professor of Radiology, Director of Head and Neck Imaging, at Weill Cornell Medical College, NewYork-Presbyterian Hospital, New York, NY. He is a member of the *Applied Radiology* Editorial Advisory Board.

FUJIFILM
Value from Innovation

Visionary Performance.

For the Radiologist, a quick, confident diagnosis means everything to your patient.

Persona CT delivers fast, sharp images to facilitate confident decision-making.

Be visionary.



#VisionaryCT

Persona CT

Powerful, Protective, and a Great Communicator.

MEDRAD® Intego SMART Package* Automatic Integration to ec² Software Solutions® NMIS® / BioDose®

It's the Complete Package.

Saves time, steps, stress and exposure with smart workflow integration and powerful decision support.

1. Patient information is automatically added to MEDRAD® Intego and NMIS/BioDoes software from MWL Server.
2. The F-18 FDG bulk vial information is added to MEDRAD® Intego and NMIS/Biodose Software.
3. Once the patient is infused with MEDRAD® Intego, the NumaStatus™ interface automatically updates NMIS/Biodose with the accurate patient radiopharmaceutical dose information.
4. The NumaStatus interface exports the dose report as a DICOM secondary capture to PACS and other systems.
5. Optionally the EMR, dose management and radiopharmacy systems are updated with the patient dose information.

ec² Software Solutions
Numa

Note: The workflow above requires the site to have the MEDRAD® Intego SMART Package, NMIS/Biodose with HL7/ DICOM options and NumaStatus with Intego interface option.

Learn more about MEDRAD® Intego at radiologysolutions.bayer.com
Learn more about ec² and Numa products at ec2software.com

*ec² Software Solutions NMIS / BioDose is a separate product owned by a separate company that has a secondary capture capabilities via DiCOM. This software is not integrated into Intego's software.

ec² Software Solutions, NMIS, BioDose are trademarks owned and/or registered to ec² Software Solutions LLC and are used with permission. Numa, NumaStatus are trademarks owned and/or registered to Numa LLC and are used with permission.

Bayer, the Bayer Cross, MEDRAD, MEDRAD Intego, and Intego are trademarks owned by and/or registered to Bayer in the U.S. and/or other countries. © 2021 Bayer. This material may not be reproduced displayed, modified or distributed without the express prior written consent of Bayer. Only available in the US.
PP-M-INT-US-0103-1 April 2021

MEDRAD® Intego
PET Infusion System