Lower Limb Linear Bone Scintigraphy Activity: A Case-Based Illustrative Review

Timothy McKnight, D.O.

Section Chief, Nuclear Medicine and PET/CT
Beaumont Health – Farmington Hospital, Farmington Hills, MI
Clinical Faculty, Michigan State University, College of Osteopathic Medicine, East Lansing, MI

Case Presentation

An 18-year-old lacrosse player presented with persistent bilateral lower extremity pain, for which nuclear medicine scintigraphy was performed (**Figure 1**).

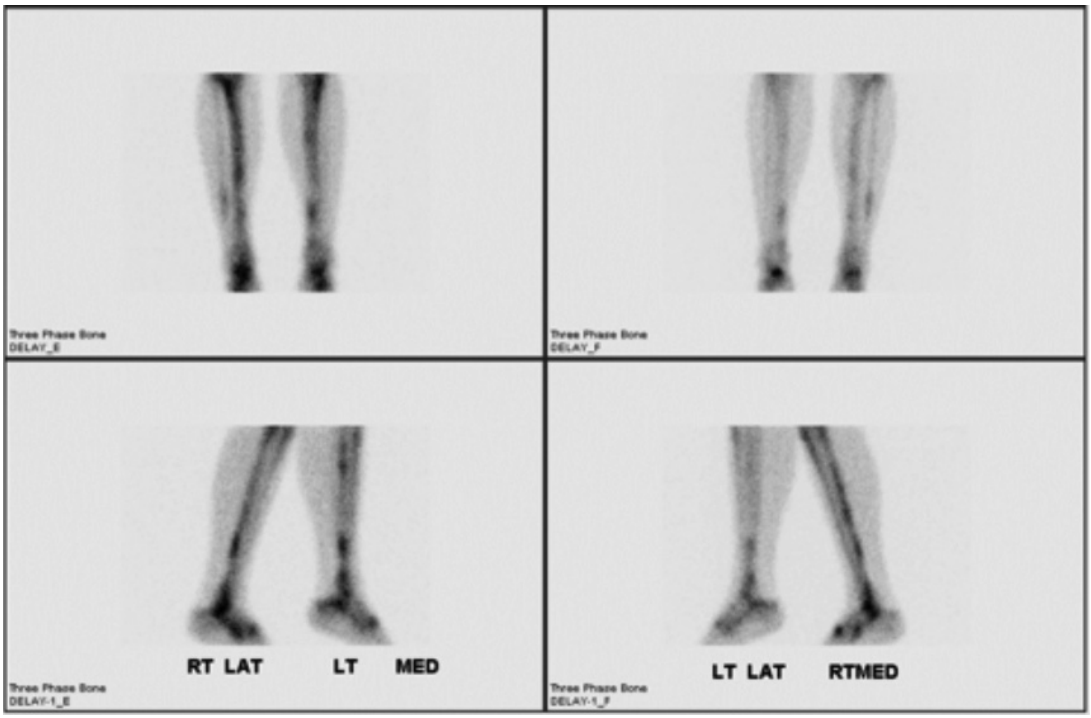

***FIGURE 1**. Tc-99m hydroxydiphosphonate (HDP) delayed anterior-posterior (AP, upper) and lateral (lower) planar images of the legs demonstrate linear patchy uptake involving the bilateral tibial posterior cortices. Perfusion and blood pool phase images (not shown) were normal.*

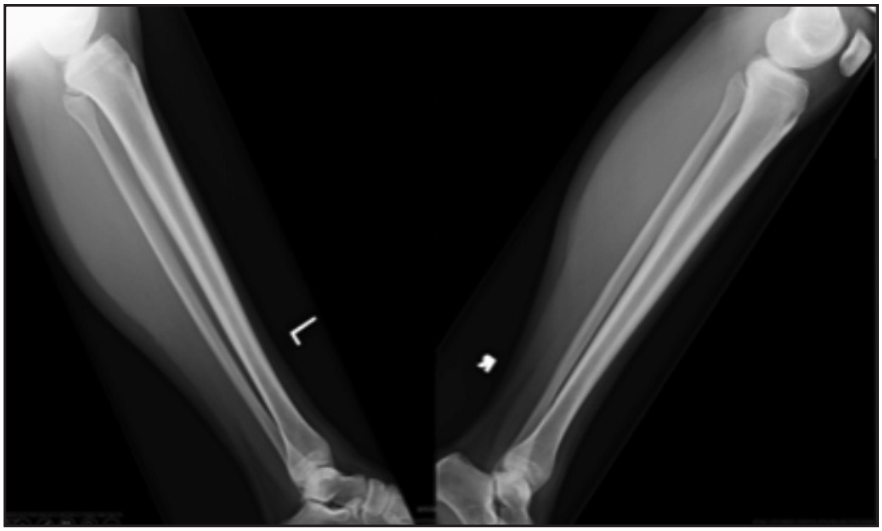

FIGURE 2. *Lateral radiographs of the tibiae/fibulae in the same patient as Figure 1 prior to bone scintigraphy demonstrate a normal appearance of the bony structures.*

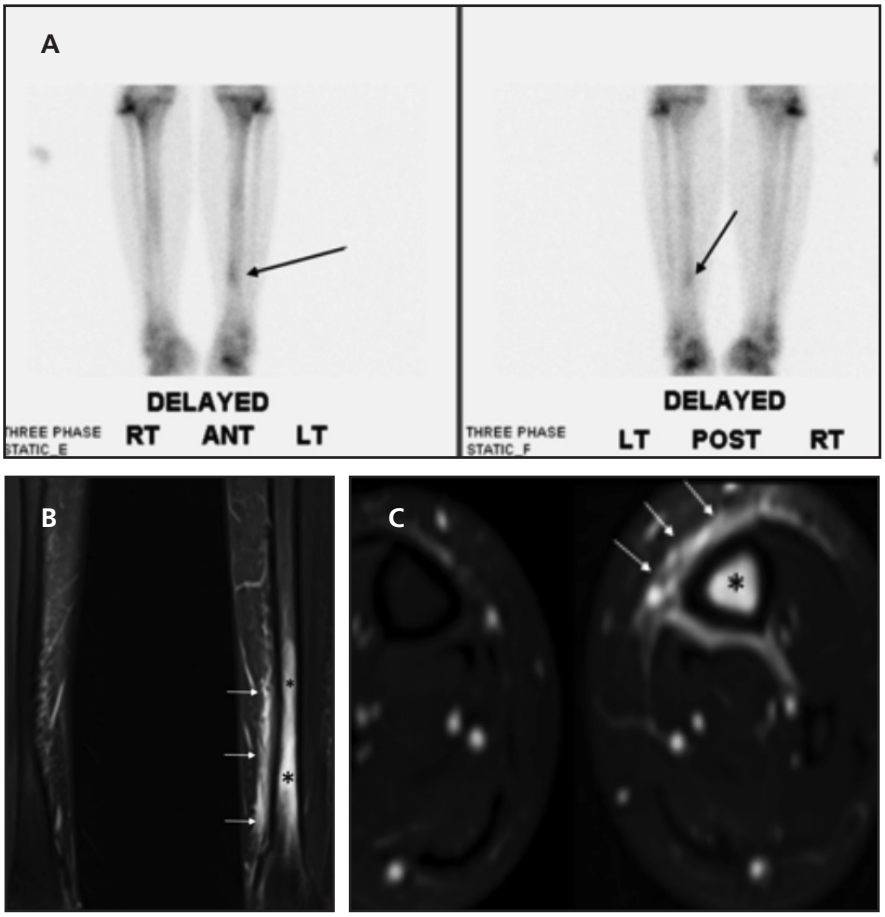

FIGURE 3. *A 15-year-old girl with recurrent left leg pain while running for a cross country team; the pain improves with rest. Tc-99m HDP delayed planar images in anterior and posterior projections (A) demonstrate faint focal linear activity in the distal left tibial shaft (arrows). Appearance is equivocal for stress fracture vs. subtle shin splints. Coronal (B) and axial (C) STIR MR images of the lower legs reveal hyperintense signal within the distal marrow space of the left tibia (*) and surrounding the cortex (arrows) but no abnormal signal or contour changes directly within the tibial cortex. Findings are compatible with medial tibial stress syndrome.*

Key Imaging Finding

Lower limb linear long bone activity

Differential Diagnoses

Medial tibial stress syndrome (shin splints)

Fracture

Osteomyelitis

Discussion

Lower extremity pain is a common complaint across age groups. In many situations, the clinical picture may be suggestive, but is often not definitive for a specific diagnosis. Radiographs are often the first study of choice but may be normal or equivocal. Bone scintigraphy has long been a popular and accessible next imaging option of choice and may provide useful information as to the etiology of lower extremity pain, impacting patient treatment and management options. Common conditions demonstrating a linear pattern of lower limb long bone activity include medial tibial stress syndrome (MTS), fractures, and osteomyelitis, detailed below. Other uncommon etiologies, such as venous stasis and hypertrophic pulmonary osteoarthropathy, are not discussed in this case review.

Medial Tibial Stress Syndrome

Medial tibial stress syndrome (MTS), colloquially known as shin splints, results from repetitive stress injury to the leg. The clinical presentation is exertional leg pain localized along the posterior medial border of the middle and/or distal thirds of the tibias. Radiographs are typically normal (**Figure 2**). Tc-99m bone scintigraphy has long been a useful tool in confirming this syndrome and excluding more severe pathologic mimics. Abnormal delayed phase uptake is typically seen in most, but not all, proven cases of MTS.[1] Perfusion and blood pool phases are typically normal.

Three patterns of uptake are closely associated with MTS: superficial uptake along the anterior and posterior tibial cortices (double stripe sign),[2] localized middle to distal tibial posteromedial

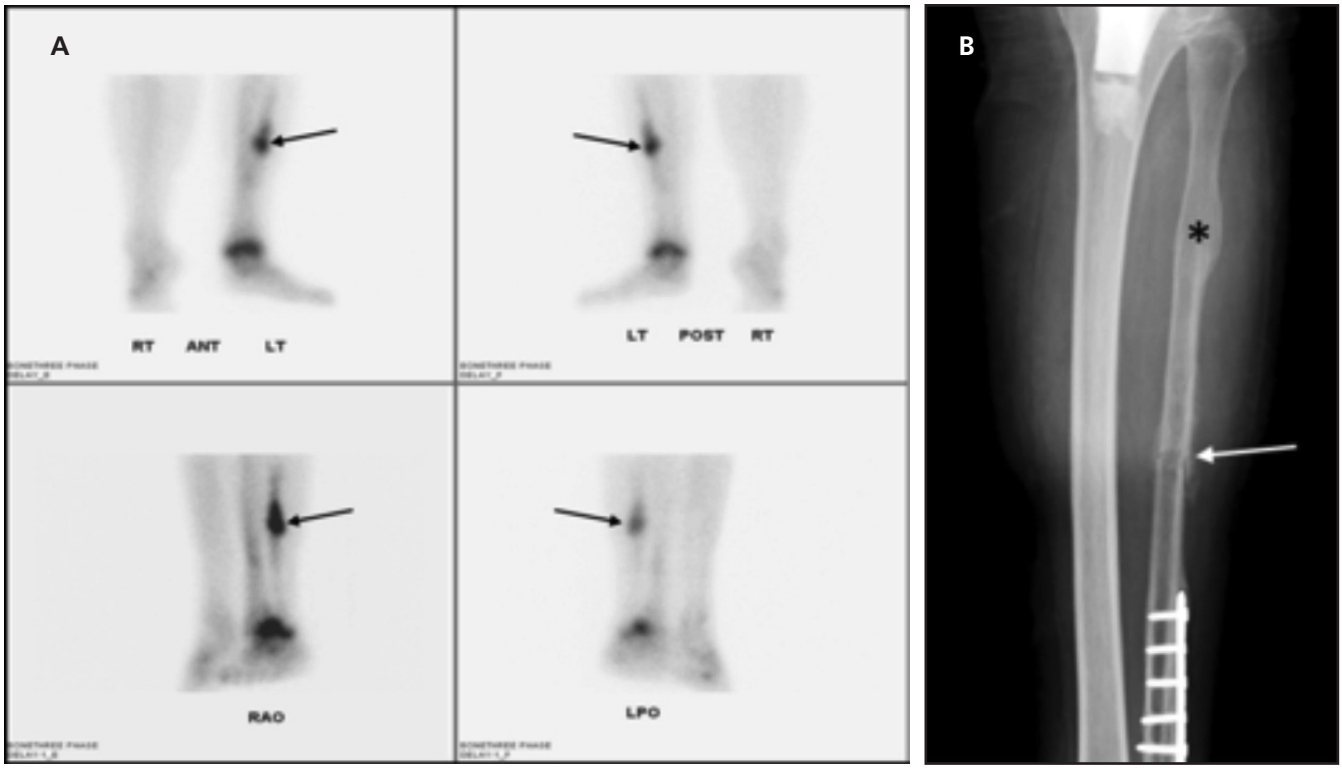

FIGURE 4. *A 64-year-old woman complaining of worsening left leg and ankle pain with a history of prior trauma and orthopedic fixation. Tc-99m HDP delayed planar images of lower legs (A) demonstrate focal intense fusiform uptake in the midfibular shaft (arrows) and subtle superior linear extension of activity along the shaft. Additional activity is present more diffusely across the ankle mortise adjacent to orthopedic hardware. Frontal radiograph of the left lower leg (B) reveals a midfibular shaft fracture with surrounding periosteal reaction and partially formed callus (arrow). A prior healed fracture is seen within the more proximal fibula (*). Orthopedic hardware is partially visualized in the proximal and distal lower leg.*

cortex activity (**Figure 1**),[3] and tubular pattern of tibial activity.[4] MTS most commonly involves at least one-third of the tibial shaft, is usually bilateral, and is often asymmetric and heterogenous.

Histological changes of MTS include osteocyte loss, enlarged lacunae, disrupted lamellar structure, and periosteal thinning or thickening. Interestingly, the extent and severity of histologic periosteal changes do not correlate with the intensity of uptake. This disparity has been suggested to represent differences between early and late/reparative phases of the disease process with abnormal activity preceding significant histologic changes.[1]

MRI can provide a useful adjunct assessment in equivocal cases with a progressive spectrum of findings, including normal or linear increased fluid signal periosteal edema with or without increased fluid signal marrow (**Figure 3**). The presence of intracortical abnormal signal crosses into the imaging patterns of occult stress fracture. In this clinical setting, the extent and severity of MRI findings has been shown to correlate with the likelihood of response to conservative treatment and time to return to sports activity.[5]

Fracture

Traumatic and stress fractures present with a fusiform or linear appearance (**Figure 4**). Stress fractures more commonly are transversely oriented to the cortex but longitudinal or oblique orientations may occur in about 10%.[6,] Combination of hyperperfusion, hyperemia, and delayed activity is typical, and in a young healthy patient appears within 24 hours of the inciting event. Delayed images at 72 hours may provide increased sensitivity, especially for elderly patients who may have delayed reparative response. Overall sensitivity of radionuclide imaging approaches 100%.[6] The pattern and severity of the fracture will determine the need for surgical vs. nonsurgical reduction and immobilization to facilitate healing. Uncomplicated fracture activity will persist for at least 6 months with most resolved by 2 years, excluding chronic nonaligned injuries, which may have indefinitely prolonged activity.[7]

Osteomyelitis

Infection shares the hyperperfusion, hyperemic, and intense delayed phase activity that is seen in fractures and can be focal, fusiform, linear, or diffuse in distribution (**Figure 5**). The scintigraphic appearance has a high accuracy (> 90%) in the setting of high clinical index of suspicion, but a low specificity if the clinical presentation is equivocal.[7] Additional studies, such as radiographs, MRI, indium-111-labeled autologous-leukocytes, or biopsy may be required for diagnostic confirmation. The high negative predictive value of a normal bone scintigraphy represents its best utility. Treatment

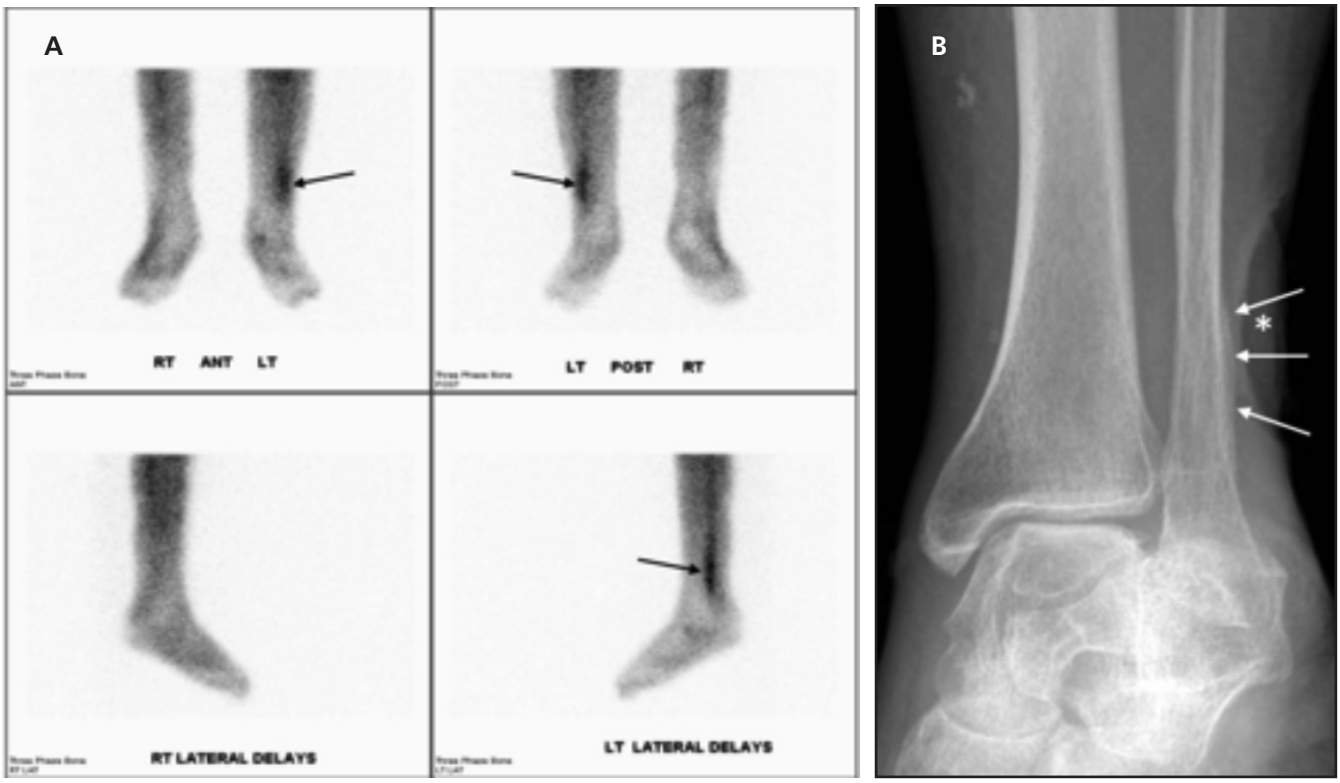

FIGURE 5. *A 61-year-old woman with worsening left leg pain and a lateral leg skin ulcer. Tc-99m HDP delayed planar images over the distal lower legs (A) demonstrate linear marked increased uptake along the distal fibular shaft (arrows). There is also slightly greater overall soft-tissue activity and a larger appearance of the left leg compared to right, consistent with hyperemia and swelling. Frontal radiograph of the left ankle (B) shows subtle periosteal reaction along the lateral distal fibula (arrows) subjacent to a large cutaneous defect from an overlying skin ulcer (*). There is diffuse soft-tissue edema.*

may include antibiotics and/or surgical debridement. Untreated or chronic osteomyelitis may result in progressive bone destruction, abscess formation, and sepsis with significant increase in mortality.

Diagnosis

Medial tibial stress syndrome (shin splints)

Summary

Bone scintigraphy is a useful and commonly utilized tool for assessing lower extremity pain. While the patterns of linear uptake among the differential diagnoses may overlap to some degree, subtle differences may be apparent, which when combined with the clinical picture, provide clues to the underlying diagnosis. Correlation with additional imaging – often radiographs – is helpful in suggesting the most likely diagnosis. Often, the best practical application of bone scintigraphy is when it is normal, providing a high degree of confidence in excluding each of these processes. The radiologist should have a general understanding of bone scintigraphy's role in the workup of a patient with lower extremity pain, be familiar with the common pathologic entities and their presenting patterns on scintigraphy, and be cognizant of the impact of imaging findings in terms of patient management and outcomes.

References

1. Bhatt R, Lauder I, Finlay DB, et al Correlation of bone scintigraphy and histological findings in medial tibial syndrome. Br J Sports Med 2000;34:49-53.
2. Lieberman CM, Hemingway DL. Scintigraphy of shin splints. Clin Nucl Med 1980;5:31.
3. Holder LE, Michael RH. The specific scintigraphic pattern of shin splints in the lower leg. J Nucl Med 1984;25:865-869.
4. Allen MJ, O'Dwyer FG, Barnes MR, et al. The value of Tc99m-MDP bone scans in young patients with exercise induced lower leg pain. Nucl Med Commun 1995; 16:88-91.
5. Anderson MW, Ugalde V, Batt M, et al. Shin splints: MR appearances in a preliminary study. Radiology 1997;204:177-180.
6. Anderson MW, Greenspan A. Stress fractures. Radiology 1996;199:1-12.
7. Love C, Din AS, et al. Radionuclide bone imaging: an illustrative review. RadioGraphics 2003; 23:341-358.