Breast Masses in Pregnancy and Lactation

Ida Teberian, M.D.,[1] Chandni Bhimani, D.O.,[1] Maria Sciotto, M.D.,[2] Annina Wilkes, M.D.,[1] Pauline Germaine, D.O.[2]

[1]Department of Radiology, Thomas Jefferson University Hospital, Philadelphia, PA
[2]Department of Radiology, Cooper University Hospital, Camden, NJ

Palpable breast lumps during pregnancy and lactation are a common presenting symptom. It is important to recognize benign masses to avoid unnecessary biopsies while maintaining a high clinical suspicion, as 20% of palpable lumps during this period are malignant.[1]

This article will cover the imaging appearances of various benign and malignant masses that may occur during pregnancy and/or lactation on ultrasound, mammography, and MRI.

Physiologic Changes in the Breast During Pregnancy and Lactation

The breast undergoes physiologic changes during pregnancy and lactation due to hormonal stimulation that increases breast size and water content. These changes manifest clinically as increased nodularity and firmness, making it difficult to pinpoint a new palpable finding on self-breast and clinical exam. The breasts return to their normal baseline state 3 months after lactation has ceased.[2]

When clinical concern arises, imaging is crucial for further evaluation. Ultrasound has the highest sensitivity and should be performed first. Mammography is less sensitive during this time due to the increased parenchymal density, which may obscure suspicious findings. This is most problematic in the late third trimester and during lactation.[3] Radiologists must be aware of the normal sonographic appearance of the breast during pregnancy and lactation. During pregnancy, the breasts demonstrate homogeneous hypoechogenicity. The lactating breast, however, demonstrates diffuse hyperechogenicity, as well as prominent ducts and increased vascularity.[1-3] Contrast-enhanced MRI should be avoided in pregnancy if possible but is acceptable during lactation, although sensitivity will be decreased. Normal lactational tissue demonstrates diffusely increased T2 signal due to the increased water content as well as rapid and plateau enhancement kinetics of breast parenchyma.[2,3]

Breast Masses Unique to Pregnancy and Lactation

Lactating Adenoma

Lactating adenomas are benign masses that arise in response to hormonal changes during pregnancy and lactation. They are common, representing 70% of biopsied masses in this population.[4] Lactating adenomas are similar to fibroadenomas but exhibit unique histologic features, most importantly the lack of both stromal components and myoepithelial proliferation. They are comprised of clusters of secretory lobules whose acini contain abundant secreted material including proteins, lipids and colostrum.[1,3]

Lactating adenomas most commonly arise as a single mass that is palpable and mobile, although they can be multiple and bilateral. They often present during lactation and rarely prior to the third trimester of pregnancy. Uniquely, they can regress spontaneously after return to a nonlactating state.[1]

Lactating adenomas share the same imaging appearance as fibroadenomas, with the most common sonographic appearance being a homogeneously hypoechoic solid mass with circumscribed margins and parallel orientation (**Figure 1**). Like fibroadenomas, they can develop areas of infarction due to rapid growth. They can have hypoechoic or hyperechoic areas due to fat content or lactational hyperplasia, respectively, or anechoic regions representing fluid. Suspicious features are also possible, including posterior acoustic shadowing, predominant hypoechogenicity, irregular shape, and microlobulated or indistinct margins, some of which may be secondary to infarction. When seen

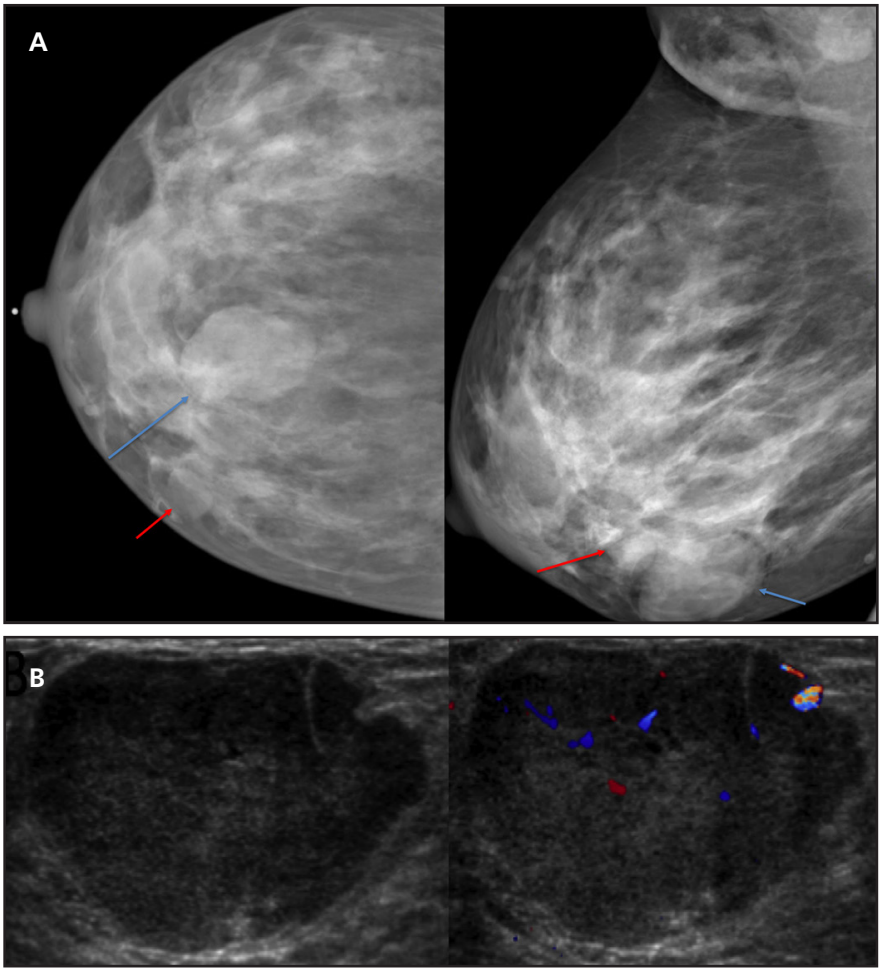

FIGURE 1. *Lactating adenomas in a 37-year-old woman, 35 weeks' pregnant, with palpable lumps in the right breast. (A) CC and MLO mammograms reveal two corresponding circumscribed masses (red and blue arrows). (B) Ultrasound demonstrates circumscribed hypoechoic solid masses with parallel orientation. In this case, core biopsy of both masses revealed lactating adenomas.*

on mammography, they appear as a circumscribed mass with variable density, including low (fat) density, and may also have a fat-fluid level due to colostrum within secretory lobules.[1]

Management is with close imaging surveillance if it appears benign. If it is atypical and without internal fat, biopsy should be performed. Lactating adenomas do not recur after surgical excision.[5]

Galactocele

Galactocele is the most common benign breast mass in a lactating patient, although it more commonly presents after cessation of breastfeeding. It may also present in the third trimester of pregnancy. Galactocele is a retention cyst originating from an obstructed duct.[2] The contents are widely variable, with different proportions of fat, proteins, and lactose possible. Histologically, they demonstrate normal epithelium and myoepithelium.[3] A fibrous wall of variable thickness may be present due to inflammation as inflammation is often the cause of duct obstruction.[1] Galactoceles can also be associated with necrotic debris if there is leakage, which incites an inflammatory reaction resulting in fat necrosis.

Clinically, galactocele often presents as a painless palpable mass discovered after cessation of breastfeeding. If it is

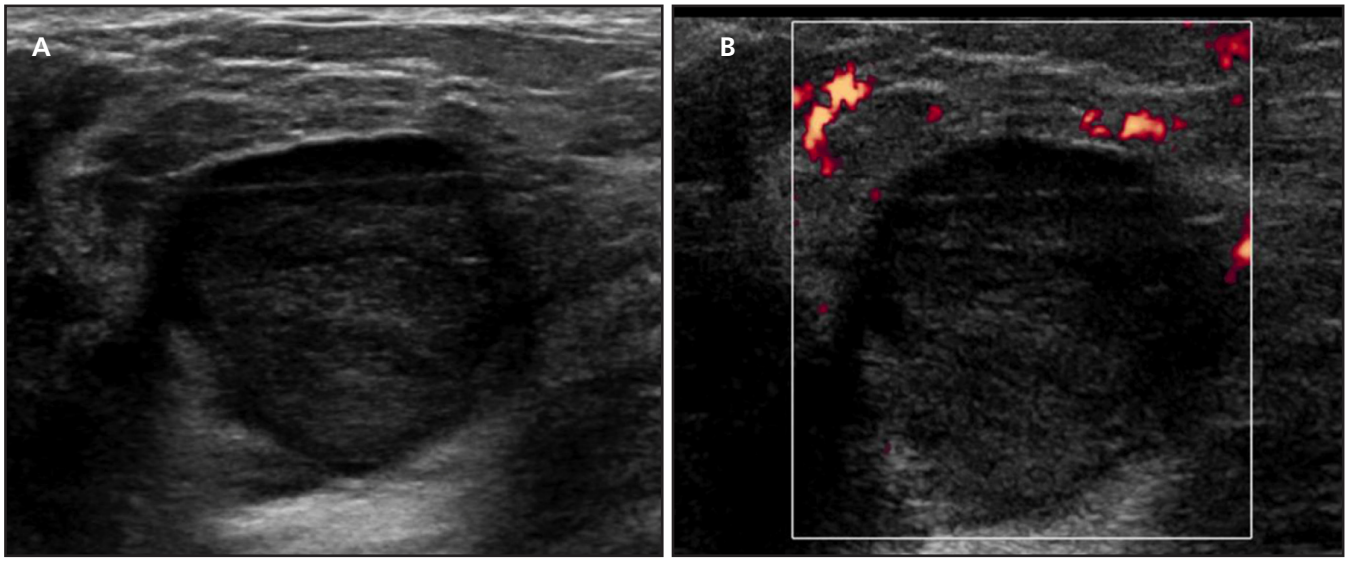

FIGURE 2. *Galactocele in a 30-year-old woman, 6 weeks' postpartum, with a palpable lump in the right breast. (A, B) Ultrasound demonstrates a complicated cyst with a fat-fluid level, posterior acoustic enhancement, and no internal vascularity.*

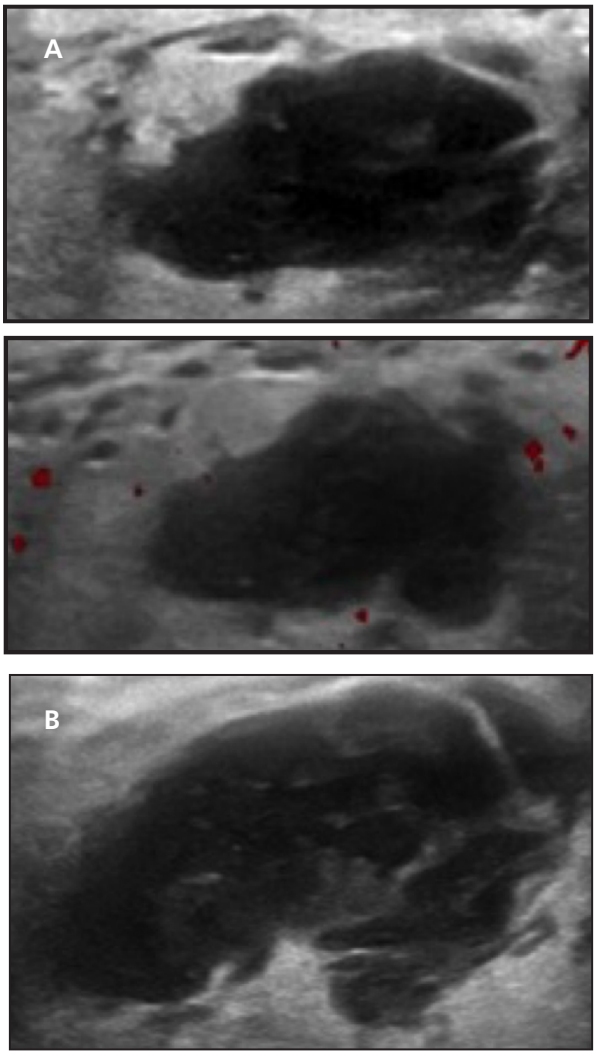

FIGURE 3. *Abscess in a 27-year-old woman, 12 weeks' pregnant, with right breast pain and redness. (A) Gray-scale and power Doppler ultrasound images show a complicated cyst with internal debris and irregular margins, concerning for an abscess. Nipple ring removal was reported by the patient approximately 1-2 months prior to the presentation. The patient was started on antibiotics. (B) Four days later, the patient returned with increased swelling, pain and redness, and ultrasound demonstrated increased size in the presumed abscess. Fine-needle aspiration produced blood-tinged milky fluid which grew Streptococcus Pyogenes Group A.*

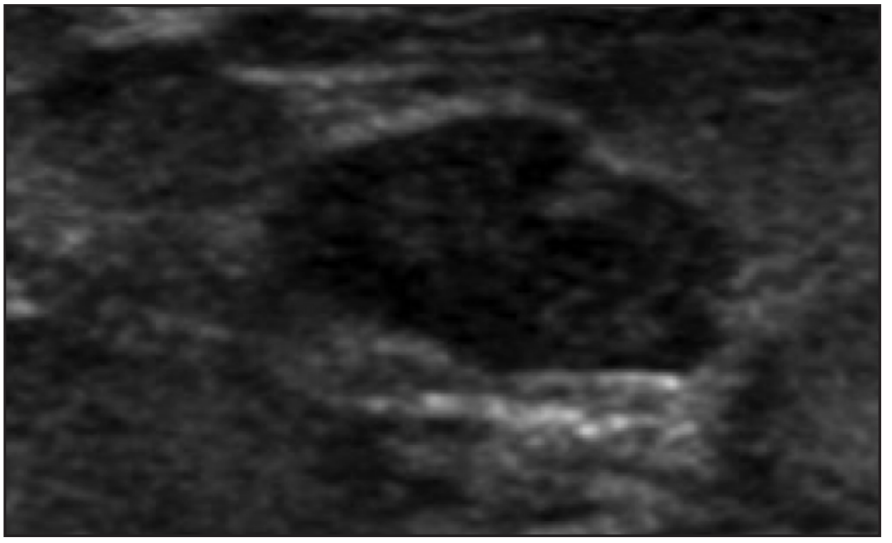

FIGURE 4. *Fibroadenoma in a 33-year-old woman, 6 months' pregnant, presenting for a 6-month follow-up of a cluster of cysts in the right breast. Ultrasound revealed an incidental oval hypoechoic solid mass with parallel orientation and posterior acoustic enhancement. Core biopsy was performed in this patient with a personal history of breast cancer, revealing a fibroadenoma.*

discovered while the patient is still lactating, a history of decreased frequency of breast-feeding is often elicited.[3] Galactoceles can be multiple and bilateral.[4]

The imaging appearance of galactoceles varies depending upon cyst contents. On mammography, it often demonstrates radiolucency, although this depends on the amount of fat present. It can be completely lucent, in which case it is known as a pseudolipoma.[2,5] Alternatively, it may have high density if it contains more viscous fluid. On ultrasound, it most commonly looks like a complicated cyst. An important radiologic sign classically seen on ultrasound is a cyst with a fat-fluid level, which occurs in galactoceles with fresh milk content (**Figure 2A**). This can also be visualized on mammography on the mediolateral (ML) projection. Galactoceles with older milk content have higher viscosity and the fat and water do not separate, resulting in a similar imaging appearance to a fibroadenolipoma.[2] Galactoceles may also appear as a solid mass with circumscribed margins and posterior acoustic enhancement, similar to a fibroadenoma, although a galactocele may also contain echogenic contents representing fat. With superimposed infection, it will appear as a complex cystic and solid mass. It is important to note that vascularity should never be present within the mass (**Figure 2B**).

With classic imaging and clinical features, no further intervention is required as galactoceles may regress spontaneously. Aspiration can be both diagnostic and therapeutic and will yield milky fluid, which may be thickened if performed after lactation has ended. Aspiration of milk must be accompanied by an appropriate clinical and imaging presentation to make the diagnosis, as similar fluid can be aspirated in any mass with lactational changes.[2]

Mastitis and Abscess

Mastitis with or without an abscess occurs more commonly during lactation and is uncommon during pregnancy.

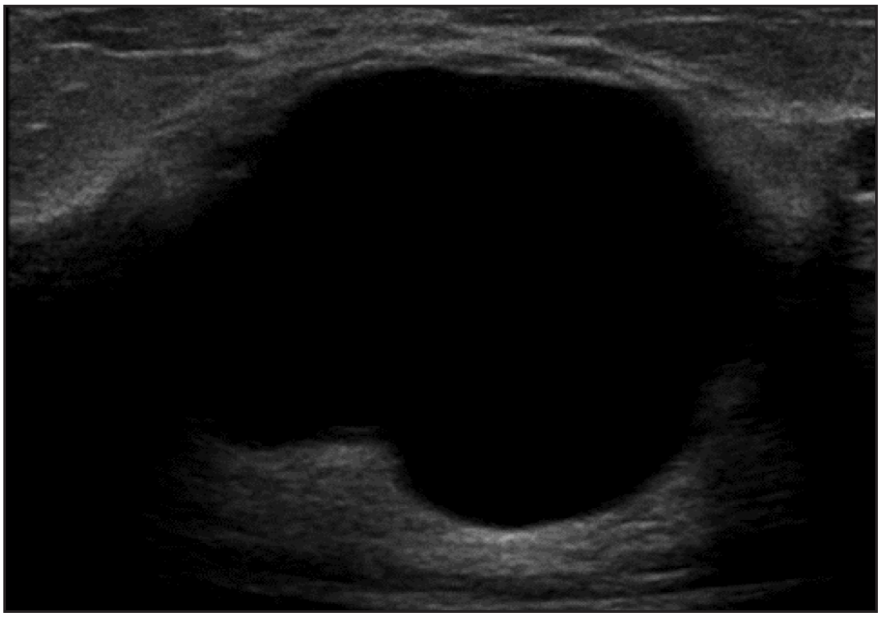

FIGURE 5. *Simple cyst in a 24-year-old woman, 7 weeks' pregnant, who presented with a palpable lump in the left breast. The oval anechoic mass with imperceptible wall and posterior acoustic enhancement correlates to the palpable lump and is consistent with a simple cyst.*

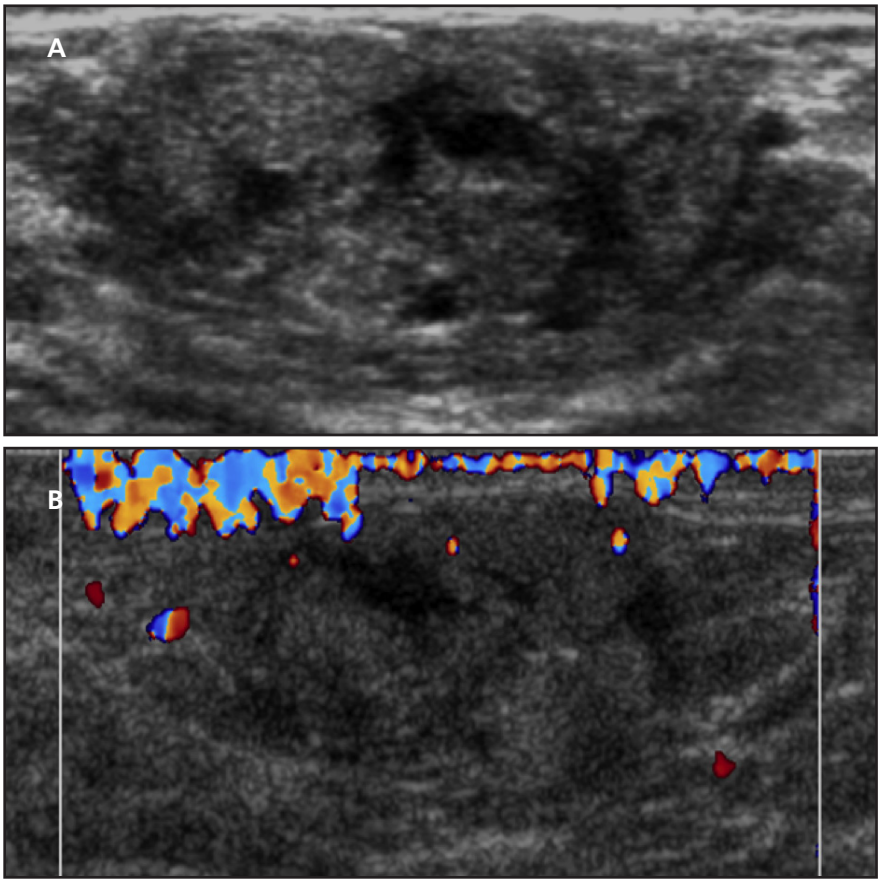

FIGURE 6. *Intraductal papilloma in a 29-year-old woman, 3 months' postpartum and lactating, with a palpable lump in the left breast. Sagittal (A) and Doppler (B) ultrasound images of the left breast demonstrate a complex cystic and solid mass at 10:00, 4 cm from the nipple with internal vascularity. Core biopsy revealed an intraductal papilloma without associated atypia or carcinoma, further confirmed on subsequent delayed excision postcessation of lactation.*

Retrograde dissemination of infectious organisms from the baby's nose or throat occurs through disruption of skin at the nipple areola complex. The most common causative organisms are *Staphylococcus* and *Streptococcus*.[2]

The diagnosis is most often clinical although imaging is indicated if an abscess or malignancy is suspected. Sonographic findings of simple mastitis include inflammation and periductitis. An abscess appears as an irregular hypoechoic or anechoic mass or complex cystic solid mass, with possible fluid or debris and posterior acoustic enhancement (**Figure 3**). Mammography is performed if there is suspicion of cancer, although it is often unrevealing due to increased parenchymal density. There may be skin and trabecular thickening due to edema and possibly a mass if there is an abscess.

Management of breast abscess includes diagnostic and therapeutic aspiration and appropriate antibiotic therapy, as well as surgical debridement if indicated, such as with a persistent or recurrent abscess or if it is > 3 cm.[4] If after appropriate therapy the findings do not resolve, cancer should be suspected and further workup performed.

Breast Masses That May Occur During Pregnancy and Lactation

Other Common Breast Masses in Pregnancy

Fibroadenoma

Fibroadenomas are the most common tumor seen during pregnancy and lactation as they often undergo sudden growth secondary to hormonal stimulation, making them newly palpable. Rapid growth also results in susceptibility to infarction as they outgrow their vascular supply. This manifests clinically as new focal pain with possible adherence to the skin and reactive adenopathy.[1,2]

Fibroadenomas arise in the terminal ductal-lobular unit (TDLU) and contain epithelial and stromal components. Secretory or lactational changes can be observed during pregnancy and lactation, whereas hyalinization, calcification,

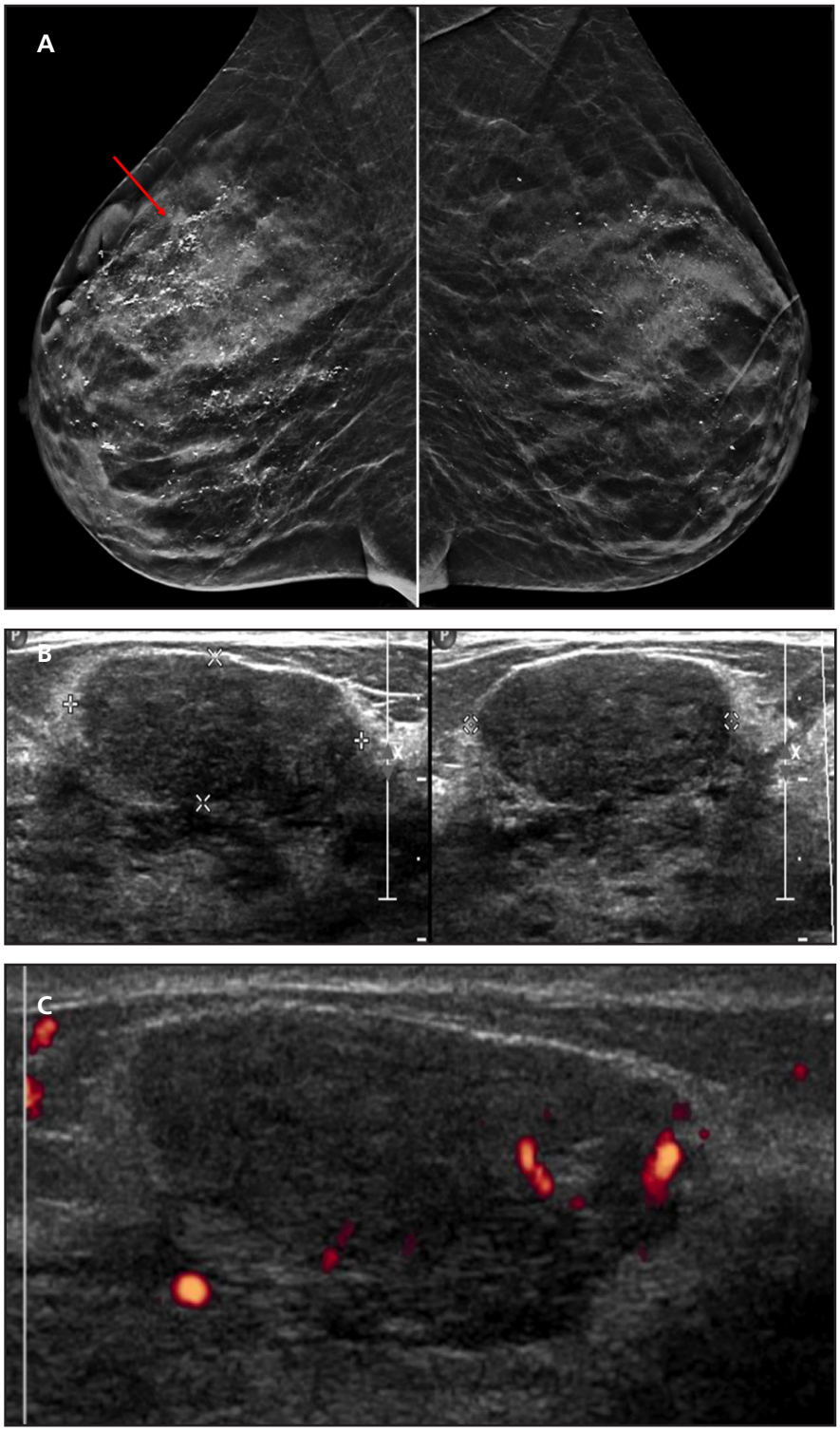

FIGURE 7. *One of the many possible imaging appearances of pseudoangiomatous stromal hyperplasia (PASH) is shown in a 40-year-old nonpregnant, nonlactating woman with a palpable lump in the right breast, increasing in size over time. (A) MLO views of the right breast demonstrate a mass at the 12:00 position, 4 cm from the nipple (red arrow). The patient had recently undergone percutaneous biopsy of the left breast, demonstrating an intraductal papilloma. (B) Ultrasound images of the palpable area in the right breast demonstrate an oval, isoechoic solid mass with circumscribed margins and parallel orientation. Subsequent core biopsy revealed PASH. (C) Mild internal vascularity is present within this mass on power Doppler evaluation.*

and ossification are atypical, classically occurring in older lesions in postmenopausal women.

The imaging appearance is usually identical to fibroadenomas in nonpregnant, nonlactating patients (**Figure 4**). A more complex appearance is possible during pregnancy, with cystic areas and/or prominent ducts, as well as greater vascularity. This may be due to infarction, which can also result in more lobulated margins, more heterogeneous echogenicity, and posterior acoustic shadowing.[1]

Nonpalpable fibroadenomas and those previously present with up to 20% growth in size can undergo close surveillance. Any atypical appearance or new mass should undergo histologic analysis. Diagnosis can be made with fine-needle aspiration (FNA) or core needle biopsy, as discussed below in "Tissue sampling during pregnancy and lactation." It is important to keep in mind that in fibroadenomas with secretory or lactational hyperplasia, milk can be aspirated, and calcifications may be present.[2]

Cysts

Cysts and fibrocystic changes are benign entities that occur with the same frequency during pregnancy and lactation as they do outside of these conditions. They are an important consideration in the differential diagnosis of palpable masses in pregnant and lactating women as they are most common in young premenopausal women.[4]

Cysts form either due to duct obstruction or an imbalance between secretions and absorption. Fibrocystic change represents various benign changes of ducts and stroma, such as adenosis, apocrine metaplasia, and usual ductal hyperplasia. It can present as cyclical breast pain and/or a palpable lump.

Cysts appear as circumscribed, homogeneous masses on mammography. Ultrasound is diagnostic, demonstrating an anechoic, round or oval mass with an imperceptible wall and posterior acoustic enhancement (**Figure 5**). In the case of complicated cysts, it is important to adhere to stringent diagnostic

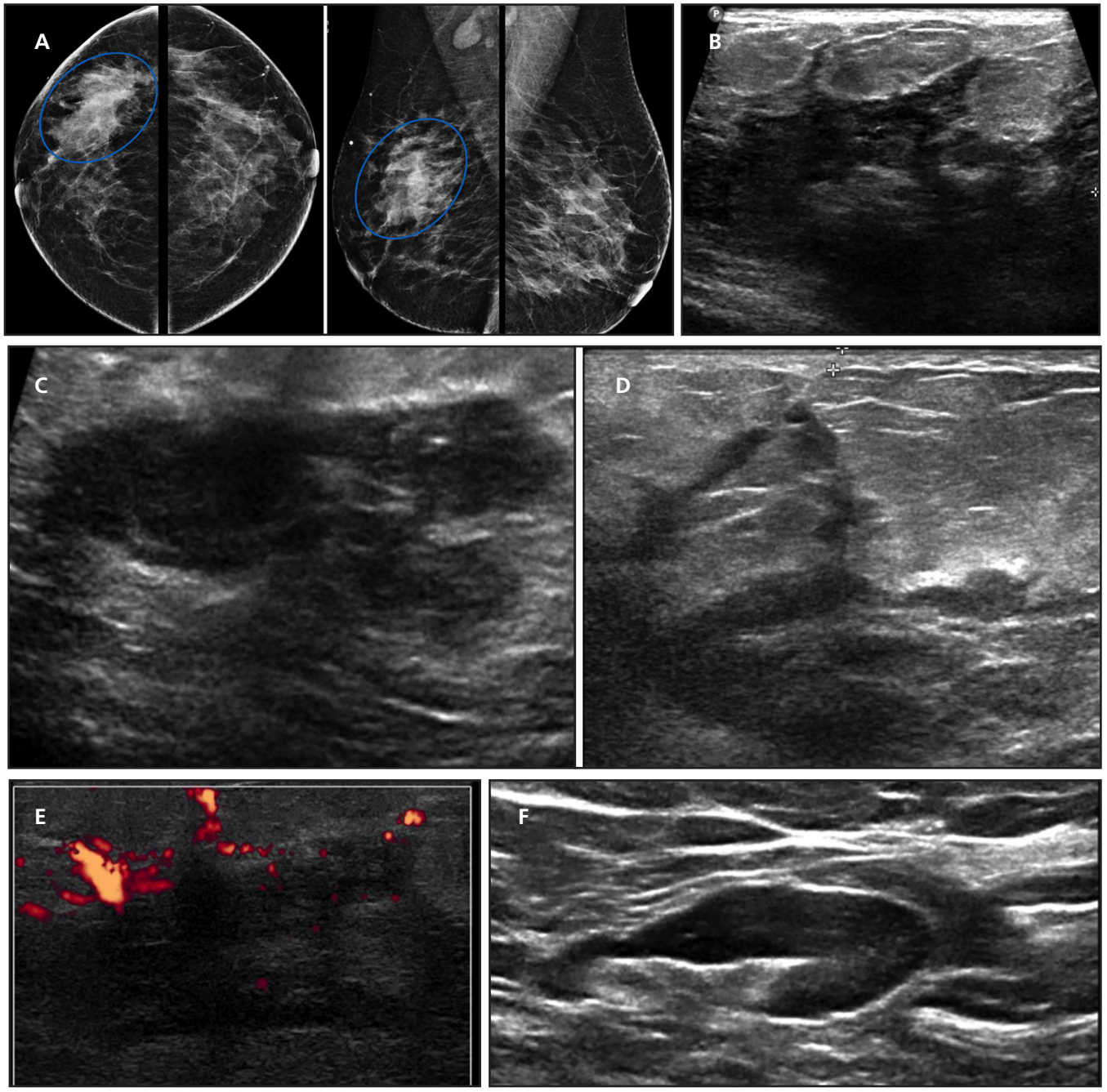

FIGURE 8. *Granulomatous mastitis in a 30-year-old woman, lactating and 2 years postpartum, with a palpable lump in the right breast. (A) Two-view bilateral mammogram reveals a focal asymmetry in the right breast, deep to the BB marker, with associated architectural distortion (blue ovals). (B-F) Ultrasound of the right breast in the area of palpable concern demonstrates a suspicious-appearing hypoechoic area spanning at least 5 cm with internal vascularity. (C) Some areas appear more mass-like than others and (D) there are associated tubular, hypoechoic structures. Mild skin thickening was also noted on the affected side. (F) Ultrasound of the right axilla revealed abnormal-appearing lymph nodes with asymmetric cortical thickening. Subsequent core biopsy of the palpable mass revealed granulomatous mastitis.*

criteria, including round or oval shape, uniform hypoechogenicity or fine internal echoes, circumscribed margins, posterior acoustic enhancement, and lack of a perceptible wall. Management of complicated cysts in pregnancy and lactation includes close surveillance or aspiration, as the differential diagnosis includes galactocele and abscess.[1] The MRI appearance of cysts is a uniformly T2-hyperintense, round or oval, nonenhancing mass.

Clustered microcysts represent a benign sonographic finding most often reflecting either fibrocystic change or apocrine metaplasia and are most common in perimenopausal women.[4] The typical appearance is a mass consisting of a group of 1-7 mm cysts with thin septae and lack of a solid component. They may be round, oval, or microlobulated

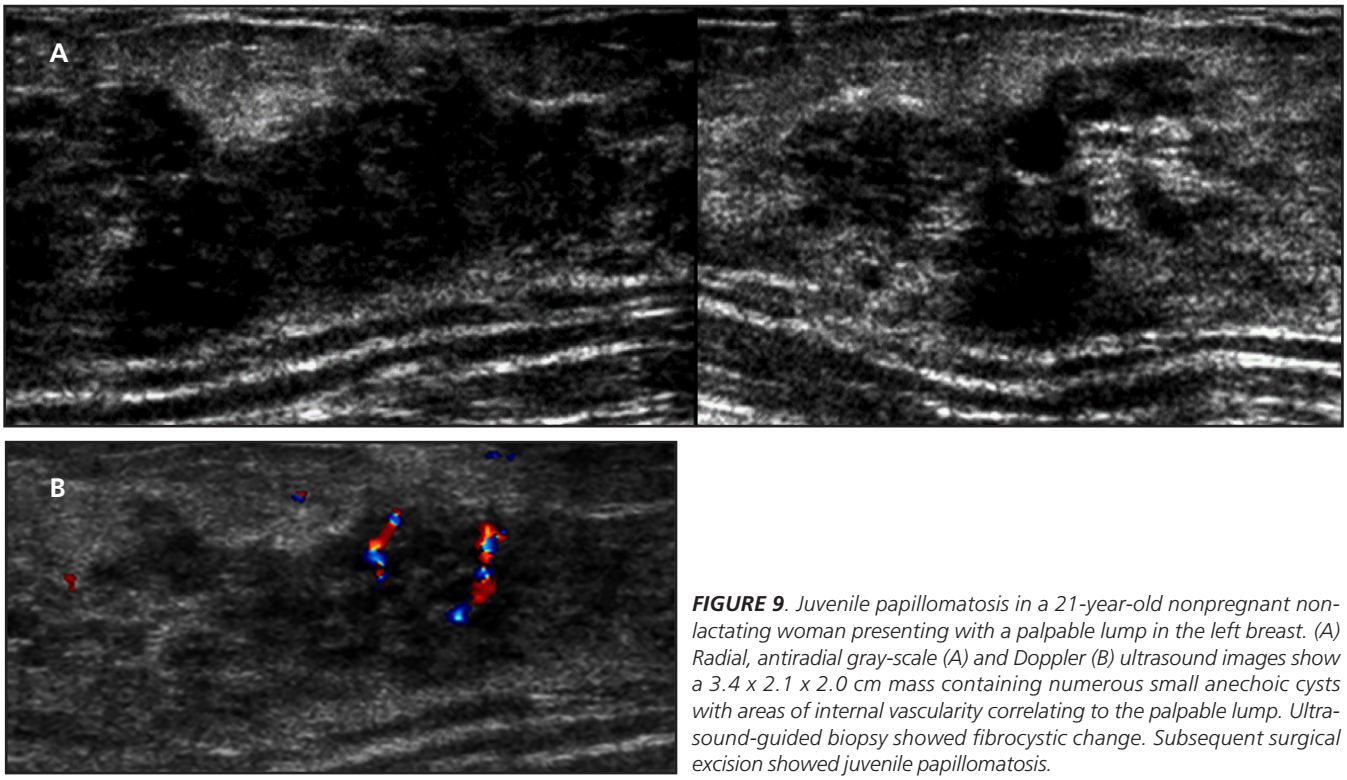

***FIGURE 9**. Juvenile papillomatosis in a 21-year-old nonpregnant nonlactating woman presenting with a palpable lump in the left breast. (A) Radial, antiradial gray-scale (A) and Doppler (B) ultrasound images show a 3.4 x 2.1 x 2.0 cm mass containing numerous small anechoic cysts with areas of internal vascularity correlating to the palpable lump. Ultrasound-guided biopsy showed fibrocystic change. Subsequent surgical excision showed juvenile papillomatosis.*

and have circumscribed margins. They can contain debris as well as milk of calcium. MRI will show T2 hyperintensity with nonenhancing hypointense septations.[4] If there are any atypical features, including a solid component, indistinct margins, rapid growth, or suspicious calcifications, biopsy should be performed.

Fibrocystic change has various sonographic appearances, including complicated cyst and clustered microcysts. Less commonly, it can appear as a thick-walled cystic mass with posterior acoustic shadowing due to fibrosis. On mammography, it is often occult but may be seen as a focal asymmetry or circumscribed mass similar to a cyst. MRI can show cysts, rim-enhancing cysts, scattered enhancing foci, or focal or regional nonmass enhancement.[4]

FNA can be performed for a symptomatic cyst for therapeutic relief. If cyst diagnosis is not certain based on imaging features, FNA can be performed to resolution to confirm that the finding is a cyst. If the cyst does not fully aspirate or a solid component persists, core biopsy should be considered.

Other Breast Masses Not Unique to Pregnancy

Intraductal Papilloma

Intraductal papilloma is a benign tumor representing papillary proliferation of ductal epithelium surrounding a fibrovascular stalk. Papillomas occur most often in women ages 30 to 50 years but are rare, accounting for 0.7% to 4% of solid breast lesions.[4] It can be solitary or multiple, with the solitary type usually in the central and retroareolar breast and in older patients, compared to multiple papillomas, which are usually peripheral and in younger patients.[4,6] They confer a slightly elevated risk of breast cancer, with a greater risk associated with multiple papillomas. The elevated risk is equal in both breasts.[7] Additionally, papillomas may be associated with atypia and ductal carcinoma in situ (DCIS), which are also more common with multiple papillomas.

Solitary papillomas present with bloody or nonbloody nipple discharge in 75% of cases. Bloody discharge occurs in cases of infarction and necrosis.[4,5] Multiple papillomas can present as palpable masses or with nipple discharge.

Ultrasound is more sensitive than mammography in detecting papillomas, which classically appear as a complex cystic and solid mass, representing growth within a duct (**Figure 6**). They may also appear as solid masses, similar to fibroadenomas. A feeding vessel may be identified, but it is important to keep in mind that lack of flow does not exclude the diagnosis.[4] This is especially important in pregnant and lactating women, as inspissated material within a focally dilated duct can mimic a papillary mass. Mammography may demonstrate a cylindrical, round, or oval mass, a focal asymmetry, or calcifications, which are present in 25%.[7] MRI may depict a dilated duct containing an oval, enhancing mass, although irregular or spiculated margins and heterogeneous enhancement are also possible. The kinetic enhancement patterns are variable.[4] MRI has high sensitivity for detecting papillomas since they are typically vascular.

Diagnosis is made by core biopsy. The differential diagnosis includes papillary carcinoma, which is rare and most often occurs in postmenopausal

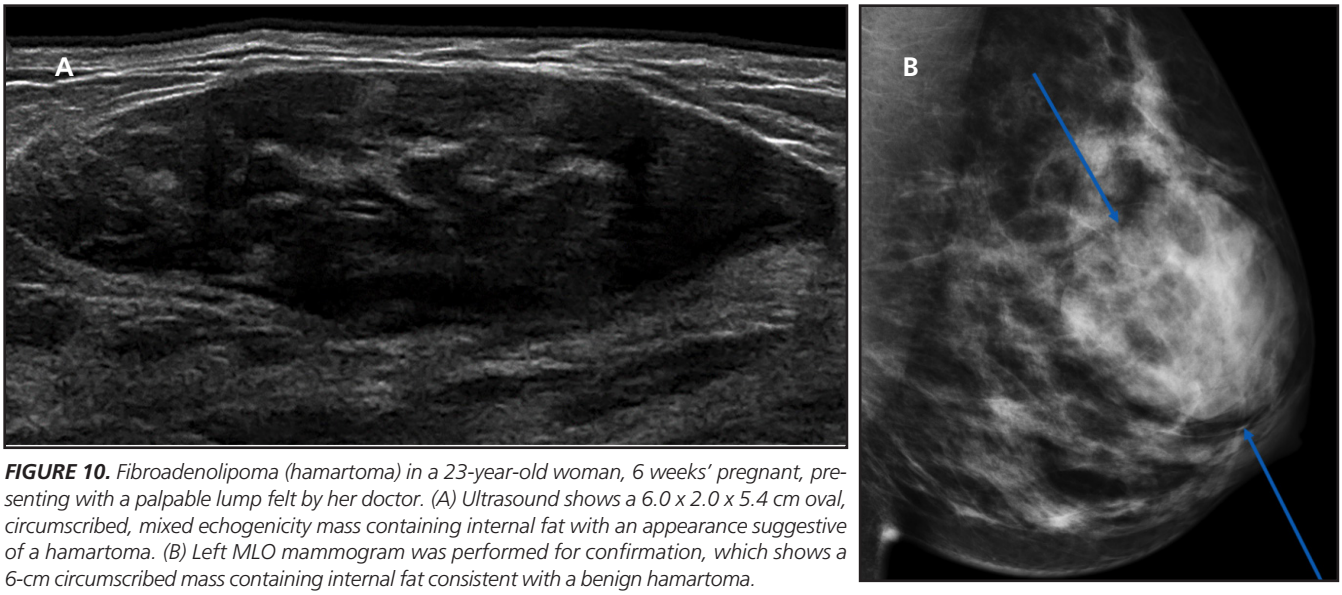

FIGURE 10. *Fibroadenolipoma (hamartoma) in a 23-year-old woman, 6 weeks' pregnant, presenting with a palpable lump felt by her doctor. (A) Ultrasound shows a 6.0 x 2.0 x 5.4 cm oval, circumscribed, mixed echogenicity mass containing internal fat with an appearance suggestive of a hamartoma. (B) Left MLO mammogram was performed for confirmation, which shows a 6-cm circumscribed mass containing internal fat consistent with a benign hamartoma.*

women, and invasive ductal carcinoma with central necrosis and/or duct extension. Benign papillomas can undergo surveillance or be surgically excised. When associated with symptoms or atypia on pathology, they are likely to be excised.

Pseudoangiomatous Stromal Hyperplasia (PASH)

Pseudoangiomatous stromal hyperplasia (PASH) is an idiopathic benign proliferation of nonspecialized stroma separating breast lobules and ducts, which contains spindle cells that form clefts or spaces mimicking vascular spaces. This mesenchymal proliferation can be found as a microscopic focus or can form a mass, which can be palpable. PASH occurs in premenopausal women as it is hormone-sensitive. It is more often found microscopically in older patients and is rarely palpable in this population.[5,8] Although benign, PASH is associated with other benign or malignant masses in 23% of cases.[8]

PASH has no specific imaging features and often resembles other masses, both benign and malignant (**Figure 7**). When it forms a mass, it is usually circumscribed with a round or oval shape and variable size. Mammography may depict a focal asymmetry or mass with no associated calcifications. If calcifications are present, they are due to a separate associated diagnosis. The mass is hypoechoic on ultrasound, usually with smooth margins and variable posterior sound transmission. MRI is equally nonspecific, demonstrating a mass or nonmass enhancement with variable T1 and T2 signal properties, although benign type 1 kinetics are most common. A suggestive MRI appearance is a mass containing T2-hyperintense slit-like spaces and cystic components.[8]

Due to its nonspecific imaging appearance, PASH is a pathologic diagnosis. Clinically and radiologically it mimics fibroadenomas. Histologically, it can mimic low-grade angiosarcoma, which occurs predominantly in young women. Diagnosis of low-grade angiosarcoma can be made by identifying red blood cells within true vascular spaces and testing for endothelial cytologic markers.[8]

Treatment of PASH is controversial although many agree that surgical excision is not necessary if pathology is concordant, in which case close surveillance is recommended.[4,8] Masses can grow over time and lead to discomfort or pain, in which case they are excised. Excision is also recommended in patients with a strong family history of breast cancer. Complete surgical excision is often performed in asymptomatic, average-risk patients due to the possibility of local recurrence and associated atypia, carcinoma in situ, or invasive carcinoma.[8-10]

Granulomatous Mastitis

Granulomatous mastitis is a very rare idiopathic inflammatory disease that has an association with pregnancy, with most patients presenting at a young age and usually within 5 years of pregnancy.[2] Clinical presentation may be with solitary or multiple firm palpable masses and possible associated lymphadenopathy or a more diffuse process.[11] There is no predilection for a specific location, although the subareolar breast is often spared.[2,4]

Mammograms are often normal but the most common finding is a focal asymmetry (**Figure 8A**).[2] It can also present as a mass with variable features. Ultrasound may show the classic appearance of multiple clustered tubular hypoechoic lesions, possibly with an associated hypoechoic mass (**Figures 8B-F**).

The diagnosis is one of exclusion as the histologic features are nonspecific, consisting of a noncaseating, nonvasculitic granulomatous reaction centered around breast lobules. The differential diagnosis for this is large and includes fungal and tuberculous infections, sarcoidosis, and a granulomatous reaction to carcinoma.[2,4]

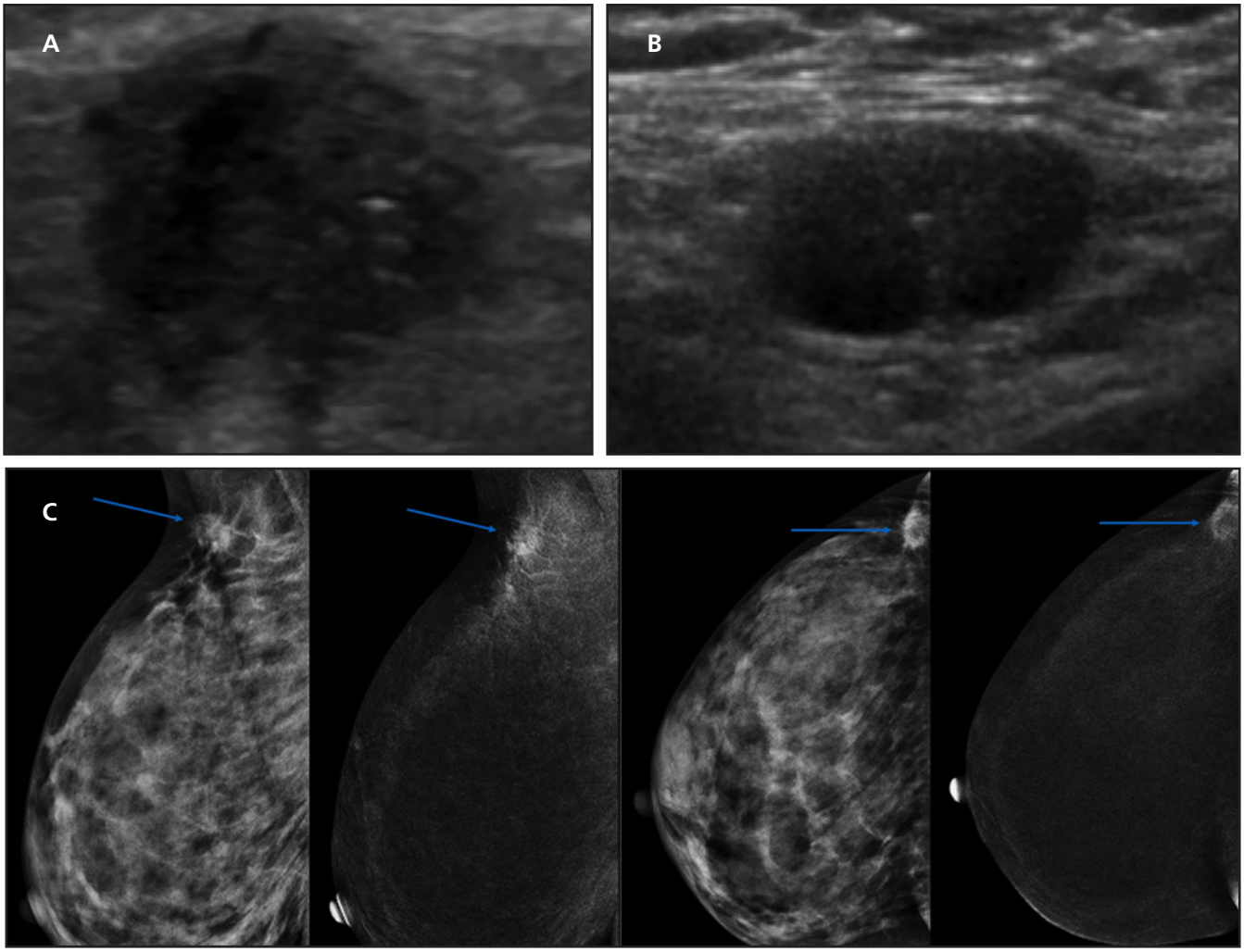

FIGURE 11. *Invasive ductal carcinoma in a 29-year-old woman, 2 months' postpartum, with a palpable right axillary lump felt by her gynecologist. (A, B) Ultrasound of the right axilla shows a hypoechoic, irregular solid mass in the axillary tail (A) as well as abnormal axillary lymph node, with loss of the fatty hilum (B). (C) Contrast-enhanced spectral mammography MLO and CC low-energy and subtraction images performed on the day of biopsy reveal a corresponding spiculated mass in the axillary tail. Core biopsy revealed invasive ductal carcinoma, ER/PR - and Her-2/neu +.*

Prognosis is good despite the possibility of local recurrence with surgical excision and corticosteroid therapy. If an organism is isolated, antibiotic therapy can be effective.[2,4,11]

Juvenile Papillomatosis

Juvenile papillomatosis is a very rare benign proliferative disorder that occurs more frequently during pregnancy and lactation as it is affected by hormonal stimulation. It consists of multiple cysts and dilated ducts within a dense fibrous stroma and clinically presents as a firm, mobile mass often at the periphery of the breast, mimicking fibroadenomas.[12] It is associated with increased risk of breast cancer, which may be concurrent with the diagnosis in 5% to 15% of cases and is considered a marker for familial breast cancer as 33% to 58% of patients have a positive family history.[9,12]

Ultrasound classically demonstrates an ill-defined hypoechoic mass comprised of multiple small anechoic cysts, often peripherally located (**Figure 9**). Mammograms are nonspecific and often negative but may show microcalcifications or an asymmetry. The MRI appearance is a lobulated mass containing small internal cysts with marked contrast enhancement with benign-type kinetics.[9,12]

Treatment is by surgical excision with wide margins as local recurrence is a possibility and because of the possible association with malignancy. Annual clinical surveillance after excision is recommended, as well as surveillance of family members.

Fibroadenolipoma (Hamartoma)

Fibroadenolipomas are benign masses containing glandular, stromal, and adipose tissue, the three components of a normal breast. They may occur at any point in a woman's life, including pregnancy and lactation, although there is no predilection for a certain physiologic state. They may present as palpable, soft, painless lumps.

Imaging by mammography and ultrasound depicts characteristic findings.

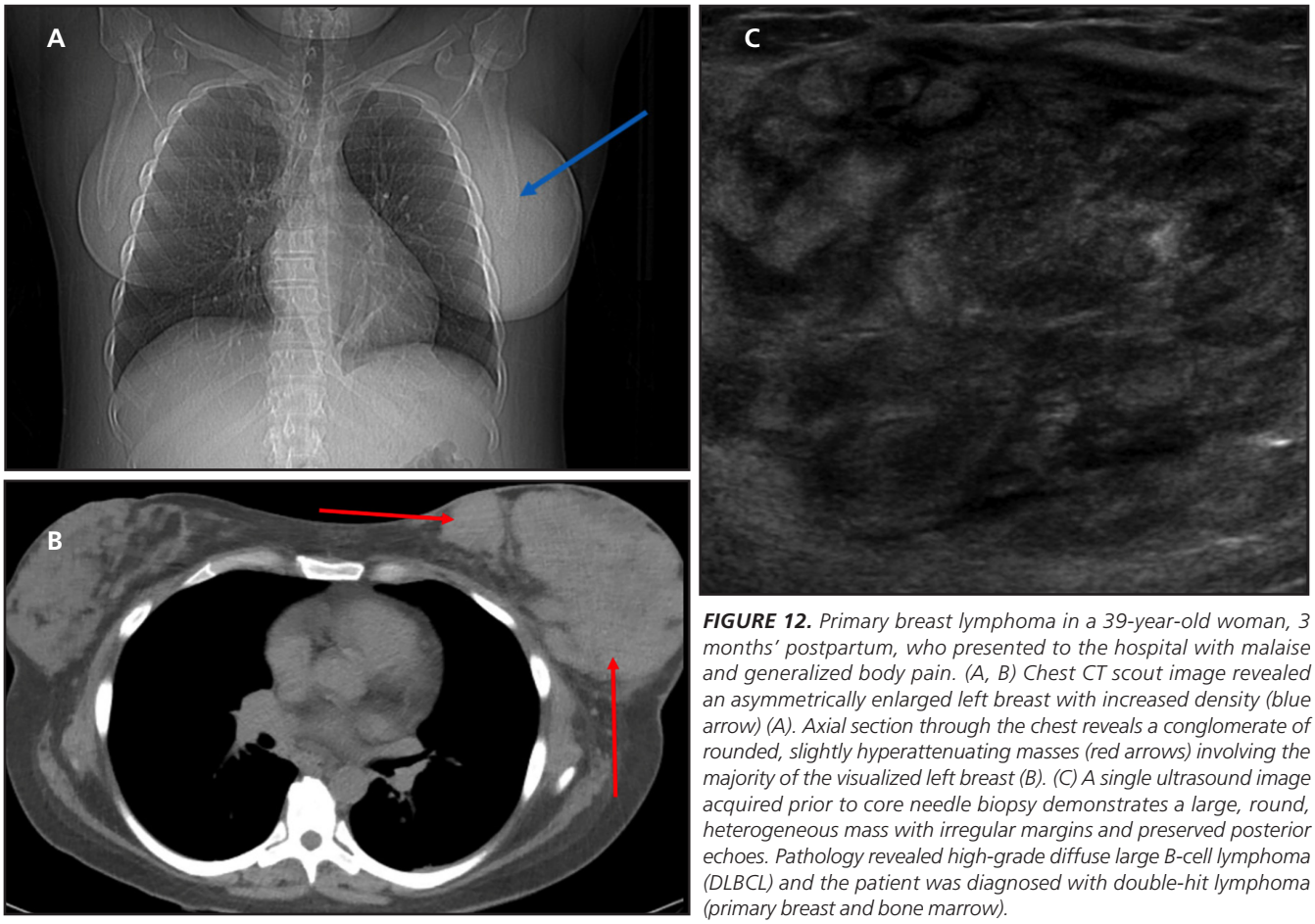

FIGURE 12. *Primary breast lymphoma in a 39-year-old woman, 3 months' postpartum, who presented to the hospital with malaise and generalized body pain. (A, B) Chest CT scout image revealed an asymmetrically enlarged left breast with increased density (blue arrow) (A). Axial section through the chest reveals a conglomerate of rounded, slightly hyperattenuating masses (red arrows) involving the majority of the visualized left breast (B). (C) A single ultrasound image acquired prior to core needle biopsy demonstrates a large, round, heterogeneous mass with irregular margins and preserved posterior echoes. Pathology revealed high-grade diffuse large B-cell lymphoma (DLBCL) and the patient was diagnosed with double-hit lymphoma (primary breast and bone marrow).*

On mammography and ultrasound both fat and parenchymal densities are seen within a circumscribed mass, often termed a "breast within a breast" appearance (**Figure 10**). Similar to other benign masses during pregnancy and lactation, growth and/or infarction can occur, resulting in atypical features.[1] With atypical sonographic features, mammographic demonstration of fat density can be helpful. Ultimately, biopsy must be performed if there is any uncertainty.

Breast Cancer

Pregnancy-associated breast cancer (PABC) is defined as breast cancer diagnosed during pregnancy or within 1 year of childbirth. It is rare, occurring in 1 out of 3,000 to 10,000 pregnancies and constituting 3% of all breast cancers.[2,4] It accounts for 6% to 10% of all cancers in women under 40, with the average age of onset at 34 years old.[1]

Patients usually present in the postpartum period, with 20% occurring during pregnancy.[1] Clinical presentation is usually with a large palpable mass and lymphadenopathy (**Figure 11**). Patients may also present with locally advanced disease, manifesting as swelling, erythema, and enlargement of the breast. The disease is more advanced at presentation compared to nonpregnancy-associated breast cancer in women of the same age. Tumors are more commonly high-grade, more than half present with metastatic lymphadenopathy, and inflammatory cancer is more common. Interestingly, approximately one-third of malignancies occur in high-risk women.[1]

Imaging features are similar to nonpregnancy-associated malignancy and can be benign-appearing, typical of high-grade tumors, demonstrating posterior acoustic enhancement on ultrasound.[1] Mammography is performed as it depicts calcifications, present in up to 55% of cases,[2] and may show multifocal or multicentric disease.

Treatment during pregnancy and lactation has some important considerations. Chemotherapy can be administered during the second and third trimesters with the primary fetal risk being prematurity. Radiation and hormone therapy are contraindicated during pregnancy.[1] Surgery can usually be performed at any point during pregnancy, although waiting until after the first trimester may be appropriate in certain cases.

Lymphoma

Primary breast lymphoma (PBL) is very rare, representing 0.1% of breast cancers, and occuring mostly in women in their fifth and sixth decades.[4,13] It is a form of non-Hodgkin lymphoma (NHL) and most often of B cell lineage. Burkitt lymphoma of the breast

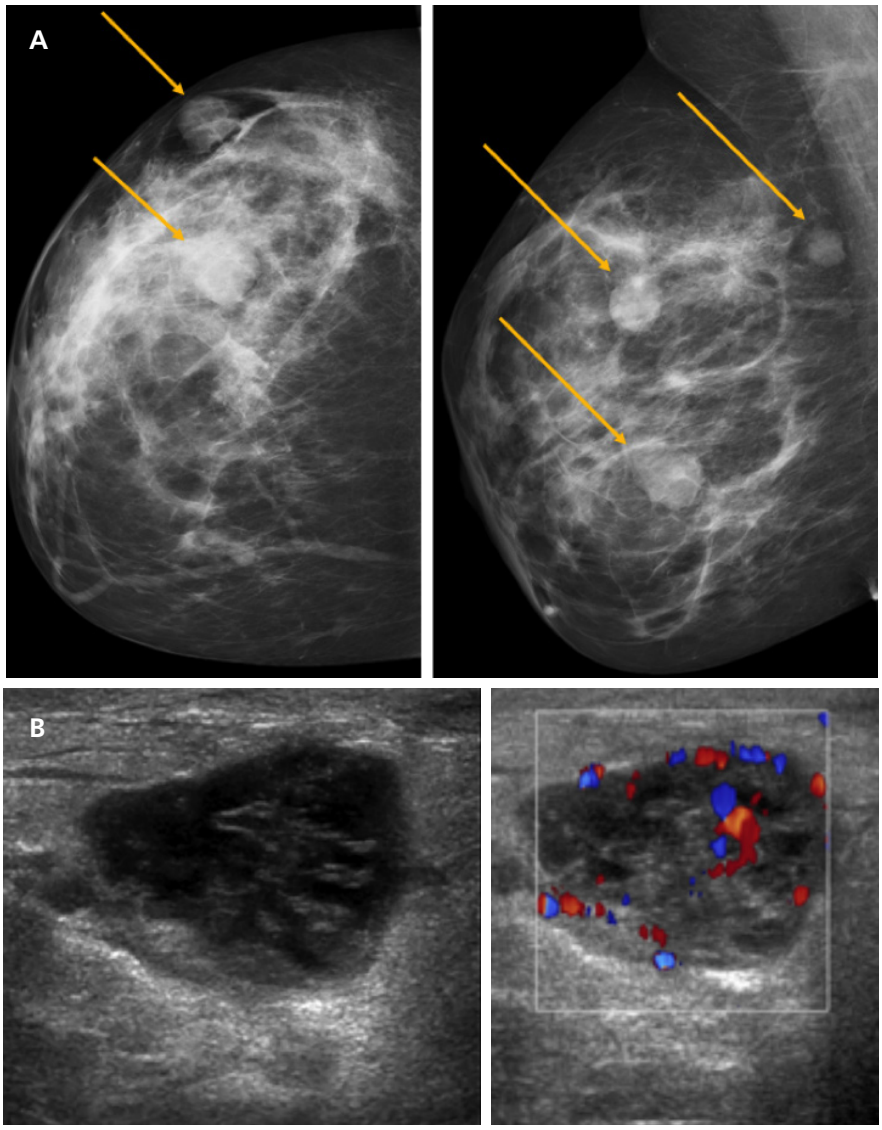

FIGURE 13. *A 43-year-old nonpregnant woman with a history of melanoma presented with a palpable right breast mass. (A) On the mammogram are multiple right breast masses (orange arrows). (B) A representative ultrasound image of the largest right breast mass shows a 2.3 x 2.3 x 1.6 cm heterogeneous vascular mass. This mass was biopsied with results of metastatic/recurrent melanoma.*

(BLB) is a very rare B-cell NHL subtype, which can be endemic, occurring in young African patients, or sporadic, occurring in Europe and the US. The sporadic form is most common and has been associated with pregnancy and the postpartum period, sometimes referred to as pregnancy-related Burkitt lymphoma.[2]

Patients with PBL often present with either a discrete palpable, painful mass or diffuse thickening.[4,14] There is no skin or nipple retraction or nipple discharge and patients rarely experience typical B symptoms (fever, weight loss, and night sweats). There can be diffuse breast enlargement with edema, mimicking inflammatory breast cancer. BLB often causes massive enlargement of both breasts.[2] It is aggressive and infiltrative, causing increased parenchymal density. Findings elsewhere in the body include enlargement of both ovaries and other abdominal organs. Peripheral lymph nodes are rarely involved.[2]

Imaging is nonspecific. A solitary mass is more common than multiple masses, which only occur in 9% of cases and is more common in secondary breast lymphoma (SBL).[13] Mammography may be negative or may show masses or global asymmetry. Mass margins can be indistinct or circumscribed. There are no associated calcifications or architectural distortion. Global asymmetry is seen in one-third of patients and is often associated with high-grade lymphoma.[2,13] There are often associated enlarged axillary lymph nodes. Ultrasound is nonspecific and variable, often demonstrating a round or oval hypoechoic mass with circumscribed or indistinct margins and variable vascularity and posterior acoustic properties, although up to 64% have hypervascularity and up to 75% have posterior enhancement (**Figure 12**).[13] There are often overlying skin changes as it is spread through the lymphatics.[14] Lymphoma on MRI is irregular with mild-to-marked heterogeneous enhancement and restricted diffusion.

PBL is aggressive with high relapse rates, occurring in the CNS in 20% of patients.[13] Treatment is primarily with chemoimmunotherapy and radiation, with surgical treatment offering no benefit.[13,15] Pregnancy-related BLB often spreads rapidly, has a poor prognosis, and can be easily misdiagnosed without adequate immunophenotypic or chromosome analysis.[2,16] Interestingly, it has also been known to spontaneously regress after cessation of lactation.[2]

Metastatic Disease

Metastases to the breast are rare although they are the first manifestation of the primary malignancy in up to 50% of cases.[14] The most common secondary breast malignancies are lymphoma, melanoma, lung and ovarian cancer, and sarcomas.[4] They can present as rapidly growing, painless masses but most are asymptomatic.[17] Prognosis is poor with median survival of 10 months.[18]

Metastases that have spread hematogenously present as masses, whereas those with lymphatic spread result in more diffuse findings similar to lymphoma. Solitary masses are more common, but metastases are more likely to be multiple and bilateral than primary

breast cancer (**Figure 13**). They classically lack signs of a desmoplastic reaction (spiculation, skin/nipple retraction). They are most often in areas of rich blood supply, including the upper outer quadrant, superficial subcutaneous tissue, and edges of breast parenchyma.[14,18] Masses are usually round and circumscribed and rarely cause distortion or contain calcifications. Calcifications can be found with certain malignancies, such as ovarian cancer. Mammographically, the masses are usually high-density with indistinct or microlobulated margins. Most masses are hypoechoic or heterogeneous but can be hyperechoic. They often have posterior enhancement and posterior shadowing is uncommon. Vascularity is variable and depends on the primary tumor.[18] Lymphatically spread malignancy will appear as diffuse heterogeneously hyperechoic adipose and glandular tissue with skin thickening and adenopathy. Although it mimics inflammatory breast cancer, there is no associated mass. MRI will often show T1 and T2 isointensity except for melanoma, which will be T1-hyperintense. Metastases often demonstrate rapid homogeneous enhancement with plateau or washout kinetics.[4,14,17,18]

Tissue Sampling During Pregnancy and Lactation

FNA and core needle biopsy are options for tissue sampling. Core needle biopsy has a high sensitivity and specificity, allowing for a more definitive and confident diagnosis. Core needle biopsy also allows for ancillary testing such as for immunochemistry for estrogen and progesterone receptors in a malignancy, which would not be possible in the setting of FNA; this would be especially important in a BIRADS 4C or BIRADS 5 finding.[22,23]

Due to increased vascularity in pregnancy, there is a slightly higher risk of bleeding and infection. Subcutaneous lidocaine has no known harmful effects to the fetus and is safe to use during pregnancy and lactation.[7]

Milk fistula is rarely a complication of core needle biopsy. Using an oblique track from skin surface to the target for biopsy can help decrease the incidence of milk fistula. If it occurs, it usually resolves on its own in several weeks. If it does not resolve, it may be necessary to suppress lactation to close the fistula.[22,23]

Conclusion

Palpable lumps can be a diagnostic challenge during pregnancy and lactation, both clinically and radiologically. Radiologists must be aware of the appearance of normal physiologic changes as well as the various entities that may present in this population. Biopsy during pregnancy and lactation carries greater risk of bleeding, infection, and fistula formation and can be avoided with adequate knowledge of the diagnostic imaging signs of common benign diagnoses. It is equally imperative to be aware of atypical findings and proceed to biopsy when they are present, however, as pregnancy-associated malignancy carries a poor prognosis that worsens with delayed diagnosis.

References

1. Langer A, Mohallem M, Berment H, et al. Breast lumps in pregnant women. Diagn Interv Imaging 2015;96:1077-1087.
2. Sabate JM, Clotet M, Torrubia S, et al. Radiologic evaluation of breast disorders related to pregnancy and lactation. Radiographics 2007;7:S101-S124.
3. Vashi R, Hooley R, Butler R, et al. Breast imaging of the pregnant and lactating patient: physiologic changes and common benign entities. Am J Roentgenol 2013;200(2):329-336.
4. Kopans DB. Breast Imaging, 3rd ed. Baltimore, MD: Lippincott Williams & Wilkins, 2007.
5. Rosen P. Rosen's Breast Pathology. 2d ed. New York: Lippincott Williams and Wilkins; 2001.
6. Yu JH, Kim MJ, Cho H, et al. Breast diseases during pregnancy and lactation. Obstet Gynecol Sci 2013;56(3):143-159.
7. Vashi R, Hooley R, Butler R, et al. Breast imaging of the pregnant and lactating patient: imaging modalities and pregnancy-associated breast cancer. Am J Roentgenol 2013;200(2):321-328.
8. Hosny IA, Salah El Din LA, Elghawabi HS. Radiological evaluation of palpable breast masses during pregnancy and lactation. Egyp J Radiol Nucl Med 2011;42: 267-273.
9. Eiada R, Chong J, Kulkarni S, et al. Papillary lesions of the breast: MRI, ultrasound, and mammographic appearances. Am J Roentgenol 2012;198:264-271.
10. Brookes MJ, Bourke AG. Radiological appearances of papillary breast lesions. Clin Radiol 2008;63: 1265-1273.
11. Raj SD, Sahani VG, Adrada BE, et al. Pseudoangiomatous stromal hyperplasia of the breast: multimodality review with pathologic correlation. Curr Probl Diagn Radiol 2017;46:130-135.
12. Chung EM, Cube R, Hall GJ, et al. From the archives of the AFIP: breast masses in children and adolescents: radiologic-pathologic correlation. Radiographics 2009;29:907-931.
13. Valeur NS, Rahbar H, Chapman T. Ultrasound of pediatric breast masses: what to do with lumps and bumps. Pediatr Radiol 2015;45:1584-1599.
14. Ogawa T, Mizutani M, Yabana T, et al. Case report: a case of Burkitt's lymphoma involving both breasts. Breast Cancer 2005;12(3):234-237.
15. Liu M, Hsieh C, Wang A, et al. Primary breast lymphoma: a pooled analysis of prognostic factors and survival in 93 cases. Ann Saudi Med 2005; 25(4):288-293.
16. Surov A, Fiedler E, Holzhausen H, et al. Metastases to the breast from non-mammary malignancies: primary tumors, prevalence, clinical signs, and radiological features. Acad Radiol 2011;18:565-574.
17. Sippo DA, Kulkarni K, DiCarlo P, et al. Metastatic disease to the breast from extramammary malignancies: a multimodality pictorial review. Curr Probl Diagn Radiol 2016;45:225-232.
18. Bitencourt AGV, Gama RRM, Graziano L, et al. Breast metastases from extramammary malignancies: multimodality imaging aspects. Br J Radiol 2017; 90:20170197.
19. Parker S, Saettele M, Morgan M, et al. Spectrum of pregnancy- and lactation-related benign breast findings. Curr Probl Diagn Radiol 2017;46:432-440.
20. Lepori D. Inflammatory breast disease: the radiologist's role. Diagnostic and Interventional Imaging 2015;96:1045-1064.
21. Glazebrook KN, Magut MJ, Reynolds C. Angiosarcoma of the breast. Am J Roentgenol 2008;190: 533-538.
22. Mitra S and Dey P. Fine-needle aspiration and core biopsy in the diagnosis of breast lesions: a comparison and review of the literature. Cytojournal 2016;13:18.
23. Mahoney MC and Ingram AD. Breast emergencies: types, imaging features, and management. Am J Roentgenol 2014;202:W390-W399.