# Globe Injury After Head Trauma

David Kopylov, M.D., Sarah Contrucci, D.O., Robert A. Koenigsberg, D.O., M.Sc., F.A.O.C.R.

Hahnemann University Hospital, Philadelphia, PA

## Case Presentation

A 45-year-old woman with end-stage renal disease, hypertension, and diabetes presented with acute-onset, right-eye blurriness with floaters following head trauma. An unenhanced CT head/orbits was obtained (**Figure 1**) followed by MR (**Figure 2**).

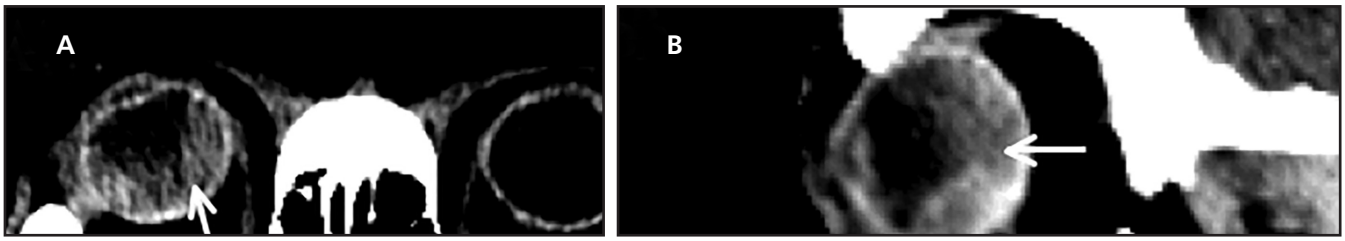


***FIGURE 1.*** *Axial (A) and sagittal (B) CT images through the right orbit demonstrate a biconcave V-shaped hyperdensity in the posterior aspect of the right globe (arrows).*

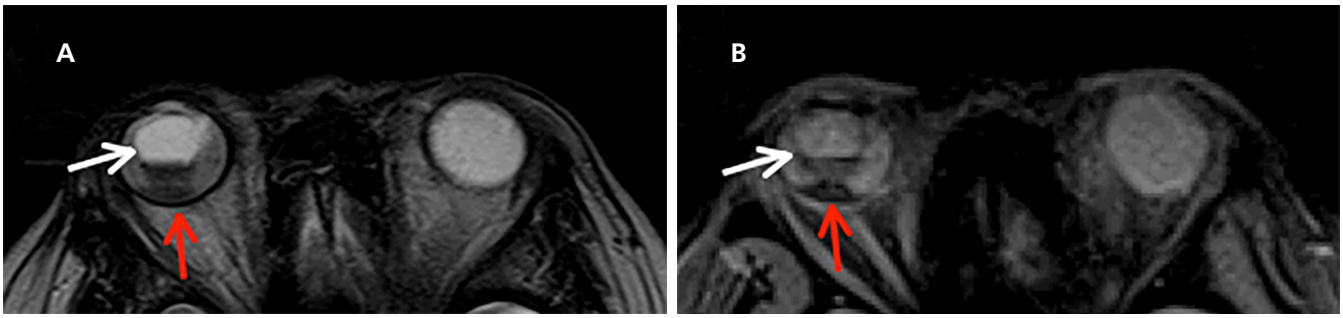


***FIGURE 2.*** *Axial T2-weighted (A) and gradient echo (B) MR images of the orbits. Folded membranes (white arrows) are seen in the vitreous humor that extend to the ora serrata anteriorly. T2-weighted hypointense subretinal fluid is demonstrated with associated susceptibility artifact representing blood products (red arrows).*

## Key Imaging Finding

V-shaped hyperdensity along the retinal surface of the globe

## Differential Diagnosis

Retinal detachment
Choroidal detachment
Vitreous hemorrhage
Lens dislocation
Globe rupture
Intraorbital foreign body

## Discussion

Orbital trauma with the potential of impairment and/or loss of vision is a critical clinical matter with an important role for radiologists. The interpreting physician must be aware of the imaging appearances of common injuries to the orbit and globe. CT is likely to be the initial imaging modality in the setting of trauma. MR imaging may also be encountered for further evaluation, but it is important to exclude an orbital metallic foreign body before MR acquisition.[1,2]

Although nontraumatic causes of vision impairment exist, the history of trauma provides a more focused differential diagnosis in this case. The initial diagnostic considerations included retinal detachment, choroidal detachment, vitreous hemorrhage as well as other traumatic causes such as a lens dislocation, globe rupture, and a foreign body.

## Differential Diagnosis

### *Retinal Detachment*

The retinal layer is the innermost layer of the globe. Anteriorly, the retina is adherent to the ora serrata, which is a transitional zone between the anterior margin of the retina and the ciliary body. The ora serrata cannot be directly visualized on CT/MR; however, its position can be inferred at the 2 and 10 o'clock positions of the globe just posterior to the ciliary bodies in the axial plane. Posteriorly, the retina is attached to the optic disc with the other portions of the retina less adherently attached to the underlying choroid layer.[2]

Retinal detachment occurs when the retina separates from the choroid layer. This can result from a variety of etiologies including inflammatory, neoplastic, postoperative, or traumatic.[2,3] Regardless of the cause, retinal detachment results in vitreous humor and/or blood collecting within the subretinal space. This fluid collection takes on a characteristic triangular V-shaped appearance, with the base at the ora serrata and the apex at the optic disc.[1-3]

Symptoms of retinal detachment include flashes of light, floaters, and peripheral field vision loss. Although radiographic imaging is not necessary to make the diagnosis, ultrasound (US), MR, and CT can be helpful to further evaluate and/or confirm clinical findings detected on the ophthalmoscopic examination.[1] On US imaging, a folded free-floating membrane (representing detached retina) can be seen in the vitreous humor.[1,2] On CT/MRI, a folded membrane can be visualized in the subretinal space fluid, which is usually detected as a vitreous hyperdensity on CT imaging. A variety of treatment procedures exist.[3]

### *Choroid Detachment*

The choroid is the middle layer of the globe, situated between the scleral and retinal layers. Choroidal detachment occurs when choroidal vessels rupture and cause fluid to accumulate, subsequently leading to detachment of the choroid from the underlying sclera.[2]

Symptoms of choroid detachment are similar to those of retinal detachment. On CT/MRI, choroidal detachment appears as a lentiform fluid collection that is of mixed intensity/signal based on the components of the collection (simple vs hemorrhagic fluid). It is important to note that choroidal detachment is not limited by the ora serrata anteriorly (unlike retinal detachment).[1,2] Additionally, unlike retinal detachment, choroidal detachment diverges as it approaches the optic disc and may not involve the posterior aspect of globe.[4] Treatment may be conservative/medical or surgical.

### *Vitreous Hemorrhage*

Vitreous hemorrhage occurs as a result of retinal vessel perforation that causes hemorrhage in the vitreous humor.[4] This is most commonly seen in the setting of diabetic proliferative retinopathy, retinal detachment/tear, orbital trauma, or orbital malignancy.[5] Patients generally present with sudden painless loss of vision with associated "floaters" or shadows in vision. On CT, small dependent areas of hyperattenuation may be seen in the posterior segment of the globe representing regions of acute hemorrhage.[4] Treatment of vitreous hemorrhage is usually conservative as nearly half of patients will show spontaneous resolution.[5] In persistent cases, surgical treatment with posterior vitrectomy may be necessary.[5]

### *Lens Dislocation*

The intraocular lens is held in place by the zonular fibers, which also attach to the ciliary body. Lens dislocation is most commonly due to trauma that disrupts the zonular fibers. Although anterior or posterior subluxation of the lens can occur, posterior dislocation is more common with the lens identified in the dependent portion of the vitreous humor.[2,4] Symptoms are similar to those of retinal detachment, including blurry vision or loss of vision. Pain is usually absent, unless there are other injuries in addition to the dislocation of the lens.

Anterior dislocations are less common, but carry greater risk of complications, such as cornea or iris injuries, as well as acute glaucoma.[6] Lens dislocation can also be nontraumatic, associated with systemic connective tissue disorders, such as Marfan syndrome, Ehlers-Danlos syndrome, and homocystinuria.[2]

On CT, the lens appears as a hyperdense lentiform structure in an abnormal position and/or orientation within the globe. Treatment varies and may be conservative, with corrective lenses and close follow-up, or surgical.[7]

### *Globe Rupture*

Blunt or penetrating trauma may result in injury to the sclera and subsequent globe rupture. As the sclera is relatively thinner posteriorly to the extraocular muscle insertions, this is

often the location of the defect in blunt trauma.[4] This is a clinically significant injury and is a common cause of vision loss. Imaging evaluation involves CT, with MRI recommended for further evaluation in cases with high clinical suspicion but no abnormality identified by CT. US is generally contraindicated when globe rupture is suspected.[4]

Imaging findings of globe rupture include abnormalities in globe contour, decreased globe volume, and discontinuity of the sclera.[4] Additional findings may include intraorbital air or foreign bodies.[2] Less obvious injuries, however, may only exhibit subtle scleral discontinuity. Increased anterior chamber depth can also suggest globe injury.[4] Treatment of open globe injuries includes antibiotics and typically urgent or emergent surgery. Presence of an afferent pupillary defect and poor visual acuity are poor prognostic indicators and indicate greater risk of the need for enucleation.[8]

### *Intraorbital Foreign Body*

Intraorbital foreign bodies typically result from penetrating trauma, and are often seen in conjunction with other orbital injuries, including in up to 40% of open globe injuries.[4] Intraocular foreign bodies are usually found in the posterior compartment, and can lead to inflammation, infection, and vision loss if not identified and treated promptly.[4] Foreign bodies can be classified as either organic or inorganic, with inorganic substances such as metal or glass most common.[4] Wood has a variable appearance that appears more low attenuating acutely and may be mistaken for air.[2,4]

CT is the imaging modality of choice, and the attenuation of the foreign body depends on its composition, with metal being highly hyperattenuating and glass being more variable but also generally hyperattenuating. MRI can also be used for imaging of nonmetallic foreign bodies, but only after the presence of a metallic foreign body is excluded.[2] Treatment for an acute foreign body usually involves antibiotics and surgical removal.[8]

## Diagnosis

Retinal detachment

## Summary

Although a broad differential was initially considered, the diagnosis was quickly narrowed based upon the imaging findings. A lens dislocation was discounted as a diagnosis as the hyperdensity in the posterior globe did not have the morphological appearance of an ocular lens. A globe rupture was not suspected given that the globe contour and globe volume appeared grossly symmetric compared to the contralateral globe. No intraocular foreign body was identified on CT imaging.

Thus, the main diagnoses to distinguish between for this case were retinal detachment, choroidal detachment, and vitreous hemorrhage. The V-shaped abnormality extending from the ora serrata converging toward the optic disk is most consistent with a retinal detachment. Follow-up ophthalmoscopy confirmed the diagnosis of retinal detachment.

Careful evaluation of the orbit and its contents is important to overall patient outcome. Familiarization with radiographic findings of various ocular trauma etiologies is crucial in making the correct diagnosis and guiding appropriate ophthalmologic therapy.

## References

1. Bord SP, Linden J. Trauma to the globe and orbit. Emerg Med Clin North Am 2008;26(1):97-123,vi-vii.
2. Kubal WS. Imaging of orbital trauma. Radiographics 2008;28(6):1729-1739.
3. Lane JI, Watson RE Jr, Witte RJ, et al. Retinal detachment: imaging of surgical treatments and complications. Radiographics 2003;23(4):983-994.
4. Sung EK, Nadgir RN, Fujita A, et al. Injuries of the globe: what can the radiologist offer? Radiographics 2014;34(3):764-776.
5. Spraul CW, Grossniklaus HE. Vitreous hemorrhage. Surv Ophthalmol 1997;42(1):3-39.
6. Nguyen VD, Singh AK, Altmeyer WB, et al. Demystifying orbital emergencies: a pictorial review. Radiographics 2017;37(3):947-962.
7. Jarrett WH II. Dislocation of the lens. A study of 166 hospitalized cases. Arch Ophthalmol 1967;78(3):289-296.
8. Pieramici DJ. Open-globe injuries are rarely hopeless. Review of Ophthalmology. 2005. www.reviewofophthalmology.com/article/open-globe-injuries-are-rarely-hopeless. Accessed January 27, 2019.