Complex Facial Fracture

Dov Rosenbaum, M.D., Elijah Kamermans, Robert A. Koenigsberg, D.O., M.Sc., F.A.O.C.R.

Hahnemann University Hospital, Philadelphia, PA

Case Presentation

A 33-year-old man presented to the emergency department after being hit by a car while crossing the street. Physical examination was significant for left orbital contusion without conjunctival hemorrhage, left eyebrow laceration, and a bloody nose. An unenhanced CT of the facial bones was obtained (**Figures 1-4**).

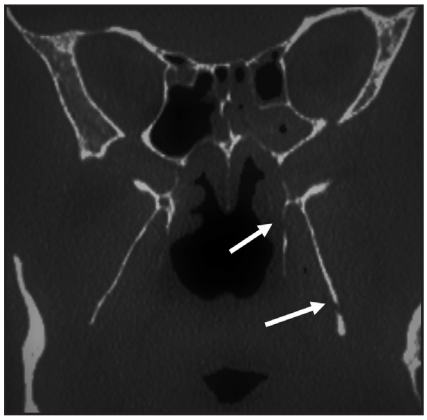

FIGURE 1. *Coronal reformatted CT of the facial bones demonstrates fractures of the left medial and lateral pterygoid plates (arrows). The right pterygoid plates are intact.*

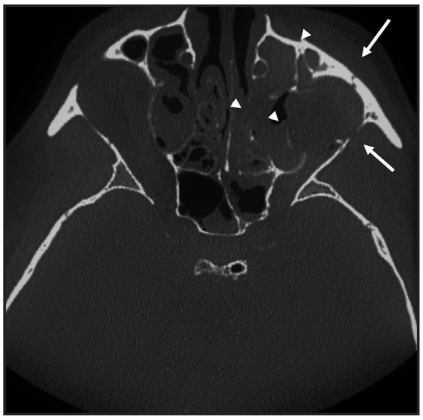

FIGURE 2. *Axial CT of the facial bone demonstrates fractures of the left zygomatic arch at the maxillary and sphenoid processes (arrows). Additional fractures of the posterior, anterior and medial walls of the left maxillary sinus (arrowheads).*

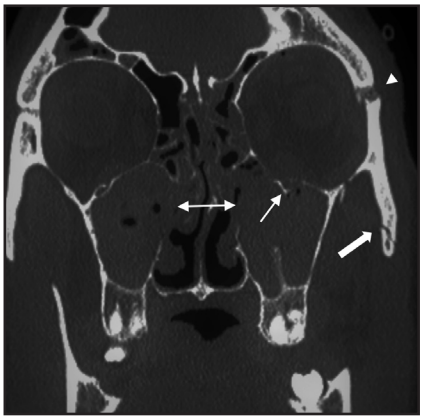

FIGURE 3. *Coronal reformatted CT image of the facial bones demonstrates a fracture of the left orbital floor (thin arrow), a fracture of the medial maxillary walls bilaterally (double-headed arrow), and fractures of the left zygoma with diastasis zygomaticofrontal suture (arrowhead) and fracture of the arch (thick arrow).*

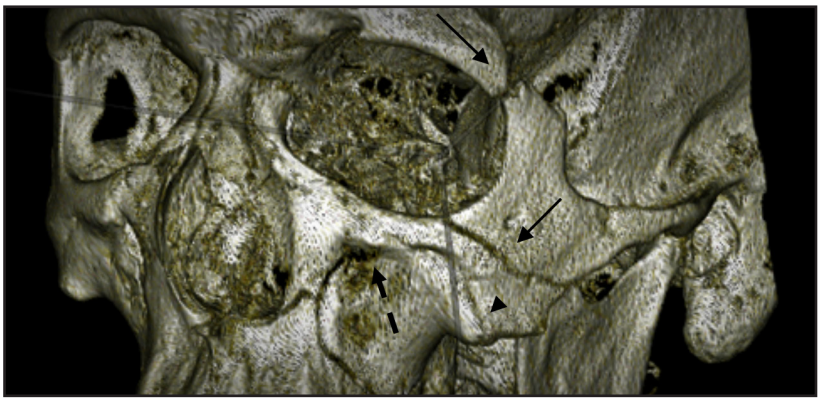

FIGURE 4. *A 3D reformatted image demonstrating a zygomatic fracture of the frontal and maxillary processes (arrows), a fracture of the anterior maxillary wall (arrowhead), and orbital floor (dashed arrow).*

Key Imaging Findings

Multiple facial bone fractures

Differential Diagnosis

Transfacial fracture (Le Fort)
Zygomaticomaxillary complex (ZMC) fracture
Naso-orbital-ethmoidal (NOE) fracture
Orbital fracture

Discussion

Facial bone fractures are routinely encountered in emergency radiology as the face is commonly involved in trauma. Specifically, traumatic injuries from motor vehicle accidents and assaults are common causes of midfacial fractures in addition to gunshot wounds and falls.[1,2]

The midface bones support the facial soft tissues and function. These osseous

structures are, therefore, often compared to architectural buttresses with the stability of the bony buttresses coming from their attachment to the skull base or cranium.[2] Search patterns along common fracture planes should include analysis of the buttresses and associated soft tissues to accurately diagnose and aid in treatment planning.

CT is the initial modality of choice for evaluating facial trauma. Many classic facial bone fractures and fracture patterns have been described, which largely comprise the differential diagnoses initially considered in this case. The radiologist must be ever observant because these fractures may not occur in isolation.

Differential Diagnosis

Transfacial fracture (Le Fort)

Le Fort fracture patterns are relatively common, occurring in approximately 25% of midface fractures.[3] There are 3 Le Fort patterns, each with a unique fracture not seen in the other patterns:

Le Fort I. Fracture of the anterolateral margin of the nasal fossa resulting in separation of the maxillary arch from the skull.

Le Fort II. Fracture of the inferior orbital rim resulting in separation of the maxillary bone from the skull.

Le Fort III. Fracture of the zygomatic arch resulting in separation of the face from the skull.[2,3]

Absence of a pterygoid plate fracture rules out a Le Fort fracture as a pterygoid plate fracture is common to all Le Fort fracture patterns. However, the converse is not always true.[3] In one study, up to one-third of pterygoid plate fractures were seen in the absence of a Le Fort fracture pattern.[4] Pterygoid plate fracture not associated with a Le Fort pattern can be associated with other fracture patterns including ZMC fractures, displaced mandibular fractures, temporal bone fractures, and fractures of the sphenotemporal buttress.[4]

Presence of a single Le Fort fracture pattern does not exclude an additional Le Fort pattern fracture on the ipsilateral or contralateral side.[3,5] The presence of a Le Fort fracture does not exclude other facial fractures including ZMC and NOE fractures.[3,5,6]

Zygomaticomaxillary Complex (ZMC) Fracture

The ZMC is structurally important in maintaining facial width and profile, and fractures have potential to be severely disfiguring.[2,6] The zygoma articulates with 4 other facial bones.[6] Radiographically, ZMC fractures can affect up to 5 structures including the lateral orbital wall, orbital floor, anterior maxillary wall, lateral maxillary wall, or the zygomatic arch.[5] Displaced ZMC fractures can increase orbital volume due to disruption to the lateral orbital wall.[2,6]

Naso-orbito-ethmoidal (NOE) Fracture

Isolated nasal bone fractures may occur in low-velocity trauma with more complex NOE fractures involving the nasal bone likely in high-velocity trauma.[1,5] NOE fractures occur along 5 fracture planes: the lateral nose and piriform aperture, the nasomaxillary buttress, the inferior orbital rim and floor, the medial orbital wall, and the frontomaxillary suture.[6] For a fracture to be classified as NOE, 4 out of 5 planes must be involved. These fractures can be simple or comminuted.[6]

NOE fractures are clinically significant due to involvement of the medial canthal tendon. The Markowitz-Mason classification is used to describe the degree of tendinous injury.[2,6]

Type I. Fracture of a single large fragment.

Type II. Comminuted fracture with a preserved medial canthal tendon insertion.

Type III. Comminuted fracture involving the medial canthal tendon insertion.

Additional focus should be placed on the nasofrontal ducts, as fracture of the bone around the duct can result in mucocele formation if not properly treated.[2]

Orbital Fracture

Orbital fractures can occur in isolation or as part of a more complex fracture pattern.[2,5] Both Le Fort and ZMC fractures can involve the lateral orbital wall or orbital floor. NOE fractures can involve the medial orbital wall. Orbital fractures can be associated with surgical emergencies if there is entrapment of the ocular muscles or optic nerve.[2,5,6] Fracture of the orbital roof can be associated with dural entrapment.[2]

Orbital fractures have the potential for serious ocular injury including ruptured globe.[1] Orbital fractures can be seen in up to 30% of facial fractures.[1]

Diagnosis

Left Le Fort II, Le Fort III, and ZMC fractures. Bilateral orbital fractures.

Summary

Trauma resulting in multiple facial bone fractures are common. The interpreting radiologist must be familiar with the gamut of fracture patterns to guide management. This case is an excellent example of multiple fractures and fracture patterns that was accurately diagnosed using a systemic approach. This case also demonstrated a number of potential diagnostic pitfalls including: (1) Multiple Le Fort patterns can be seen on one side, (2) Le Fort fractures can be unilateral and, if bilateral, do not need to demonstrate the same pattern bilaterally, and (3) Le Fort fractures can be seen with additional fracture patterns.

References

1. Chukwulebe S, Hogrefe C. The diagnosis and management of facial bones fractures. Emerg Med Clin N Am 2019;37:137-151.
2. Hopper RA, Salemy S, Sze RW. Diagnosis of midface fractures with CT: what the surgeon needs to know. Radiographics 2006;26:783-793.
3. Rhea JT, Novelline RA. How to simplify the CT diagnosis of Le Fort Fractures. Am J Roentgenol 2005;184:1700-1705.
4. Garg RK, Alsheik NH, Afifi AM, Gentry LR. Pterygoid plate fractures: not limited to Le Fort fractures. J Craniofac Surg 2015;26:1823-1825.
5. Fraioli, RE, Branstetter BF, Deleyiannis FWB. Facial fractures: beyond Le Fort. Otolaryngol Clin North Am 2008;41:51-76.
6. Dreizin D, Nam AJ, Diaconu SC, Bernstein MP, Bodanapally UK, Munera F. Multidetector CT of midfacial fractures: classification systems, principles of reduction, and common complications. Radiographics 2018;38:248-274.