CT Imaging and Interventional Radiology in Solid Organ Injury

Jonathan A. Friedman, M.D., Thomas J.D. Wilczynski, D.O., Neelabh Maheshwari, M.D., Brian A. Bianco, D.O.

Department of Interventional Radiology, Hahnemann University Hospital/Drexel University College of Medicine, Philadelphia, PA

According to the World Health Organization, traumatic injuries kill more than 5 million people worldwide every year, accounting for 9% of the world's annual death toll. Approximately one-quarter of the 5 million deaths are the result of suicide (16%) and homicide (10%) with another one-quarter due to road traffic injuries.[1] Even larger is the burden of the tens of millions of nonlethal injuries resulting in hospitalizations, emergency department visits, and outpatient encounters.

The liver, spleen and kidneys are among the most commonly injured solid organs and are particularly vulnerable to blunt or penetrating trauma, including iatrogenic injury, leading to arterial laceration, parenchymal or peritoneal hemorrhage, subcapsular hematoma, pseudoaneurysm, or arteriovenous fistula formation.[2] In the emergent setting, focused assessment with sonography in trauma (FAST) is preferred over diagnostic peritoneal lavage as the screening tool for detecting intra-abdominal bleeding. Exploratory laparotomy is indicated in hemodynamically unstable patients, while hemodynamically stable patients typically undergo initial diagnostic imaging.

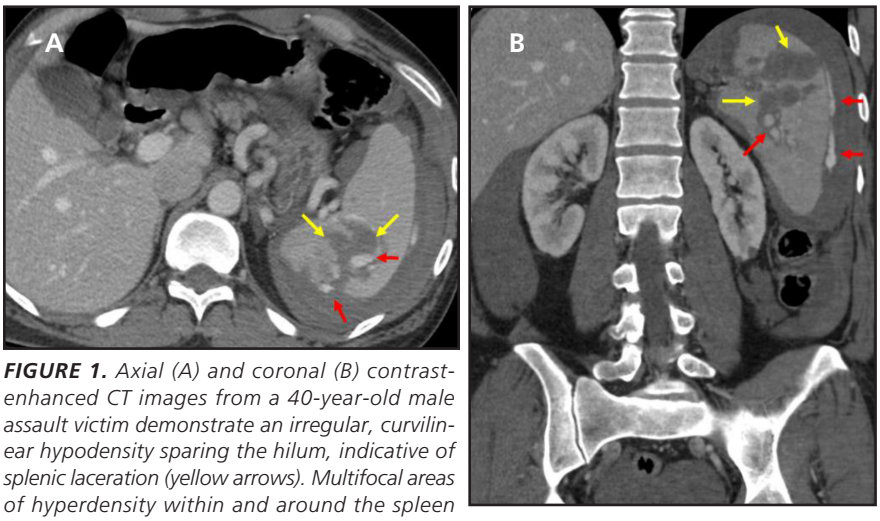

FIGURE 1. *Axial (A) and coronal (B) contrast-enhanced CT images from a 40-year-old male assault victim demonstrate an irregular, curvilinear hypodensity sparing the hilum, indicative of splenic laceration (yellow arrows). Multifocal areas of hyperdensity within and around the spleen with increased density of free fluid are indicative of hemoperitoneum with contrast extravasation (red arrows), findings compatible with grade V splenic injury.*

CT with intravenous contrast is the modality of choice because of its speed, availability, diagnostic accuracy, noninvasive nature, and ability to detect additional abdominal injuries that may require surgery.[3] Subsequent angiography may be necessary to evaluate for and potentially treat vascular injury. Typical angiographic findings in blunt abdominal trauma include contrast extravasation, subcapsular or parenchymal hematomas, and/or arterial occlusion, while penetrating trauma is usually more focal, demonstrating extravasation, pseudoaneurysms, and arteriovenous fistulas.[2]

Splenic Injury

The spleen is among the most commonly injured organs in blunt abdominal trauma, accounting for up to 49% of all visceral injuries, with rates of injury in penetrating abdominal trauma less than that of other organs such as the liver and bowel.[3,4] A substantial portion of penetrating splenic injury arises

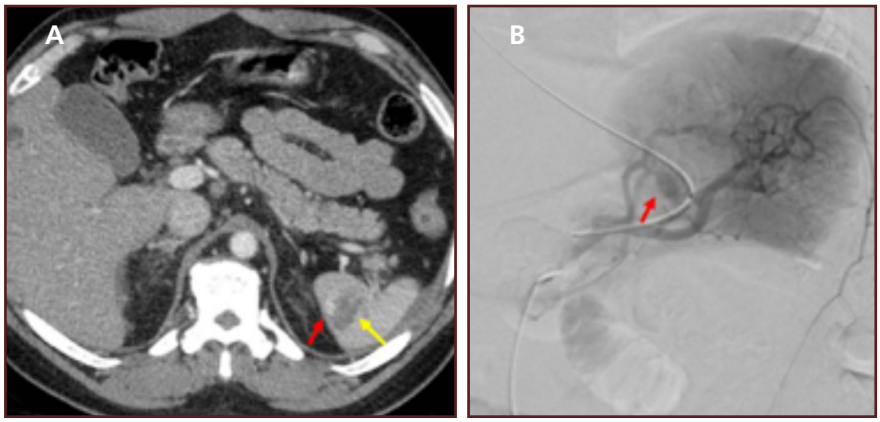

FIGURE 2. *Contrast-enhanced axial CT (A) illustrates a laceration of the spleen (yellow arrow) with a focal, ovoid area of enhancement in the splenic parenchyma consistent with traumatic splenic pseudoaneurysm that upgrades this injury to a grade IV injury (red arrow). Selective splenic arteriography (B) shows outpouching of contrast in the splenic parenchyma representing pseudoaneurysm (red arrow) originating from a branch of the splenic artery.*

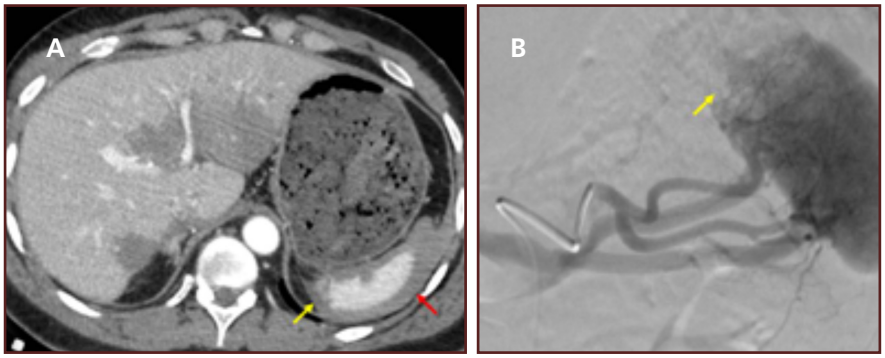

FIGURE 3. *Axial enhanced CT (A) demonstrates a small, linear hypoattenuating region in the posteromedial spleen representing a small laceration (yellow arrow). An elliptical collection of hypodense blood occupying < 10% of the spleen surface area is consistent with subcapsular hematoma and grade I splenic injury (red arrow). Incidental note is made of a large grade IV hepatic laceration involving the medial lobe with extension into the porta hepatis and surrounding perihepatic hematoma. Selective splenic arteriography (B) shows a small perfusion defect in the superior medial spleen (yellow arrow) corresponding to the grade I laceration seen on CT. The decision was made not to perform embolization as no other angiographic abnormality was identified.*

from inadvertent intraoperative injury. In splenic trauma, the ability to preserve functional spleen is dwarfed by the need for prompt diagnosis and management. CT with intravenous contrast is the diagnostic gold standard for the assessment of hemodynamically stable patients with suspected splenic injury.[2,3,5]

Imaging features of blunt splenic injury include laceration, nonperfusion, subcapsular or parenchymal hematoma, active hemorrhage, hemoperitoneum, sentinel clot and major vascular injury (**Figures 1, 2**). Laceration on CT appears as an irregular linear hypodensity. Subcapsular hematomas present as elliptical collections of hypodense blood between the capsule and enhanced parenchyma causing indentation or flattening of the organ contour (**Figure 3**). Ongoing bleeding appears as a punctate hyperdensity (85-350 HU) reflecting active contrast extravasation. Hemoperitoneum from splenic injury results in blood pooling in the left paracolic gutter and/or pelvis, possibly passing into the right upper quadrant.[3] A sentinel clot is typically a higher attenuation (45-80 HU) focus of clotted blood indicating an adjacent anatomic area of injury causing hemorrhage.[6]

The most commonly used injury classification is the American Association for the Surgery of Trauma (AAST) grading scale, which demarcates 5 grades of splenic injury (grades I-V) with a higher number indicating worse

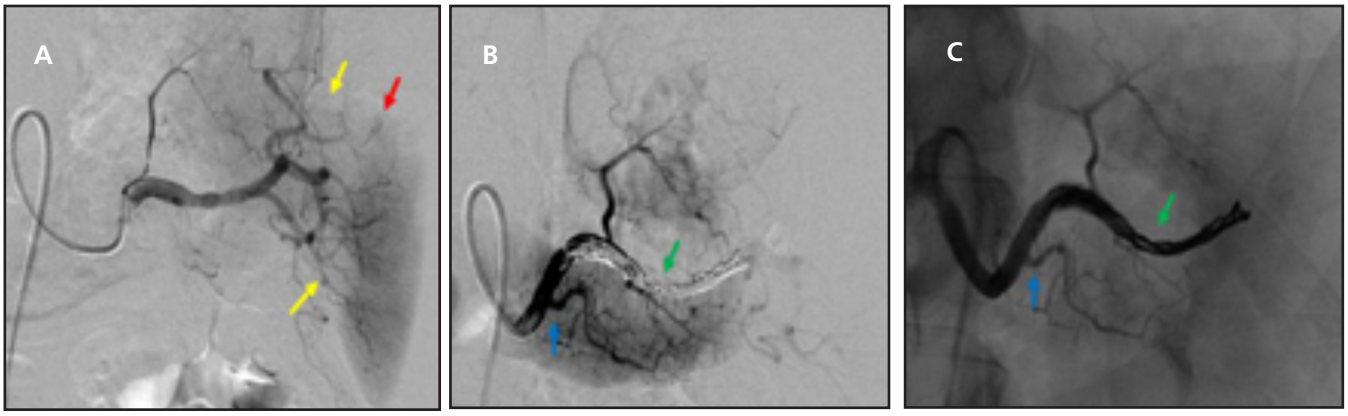

FIGURE 4. *Fluoroscopic images from a 34-year-old female motorcycle accident victim. A. Selective angiography of the splenic artery (A) shows a large area of diminished perfusion to the mid and upper poles of the spleen (yellow arrows), as well as a small focus of contrast extravasation (red arrow). Digital subtraction angiography (B) and selective splenic arteriography (C) demonstrate a coil mass in the main splenic artery (green arrow) just distal to the dorsal pancreatic artery (blue arrow) resulting in successful embolization.*

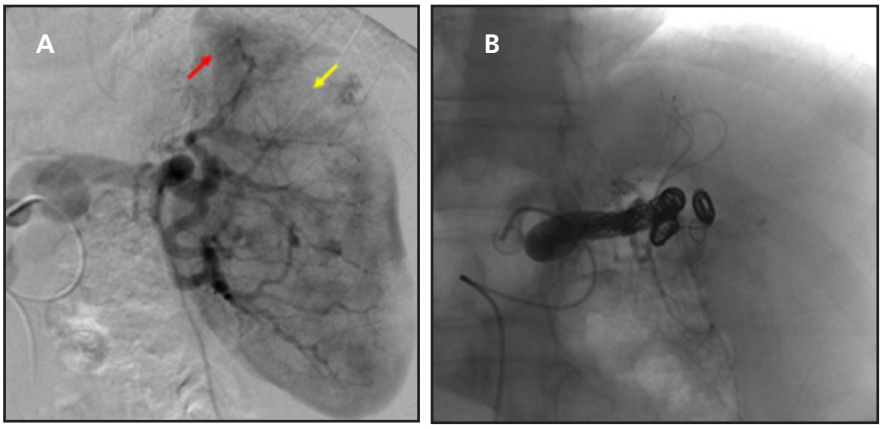

FIGURE 5. *The corresponding selective angiography (A) of the splenic artery in the 40-year-old assault victim from Figure 1 demonstrates active contrast extravasation (red arrow) from the superior pole of the spleen and large areas of hypoperfusion related to the laceration (yellow arrow). Follow-up images (B) after successful proximal coil embolization with the termination of bleeding is noted.*

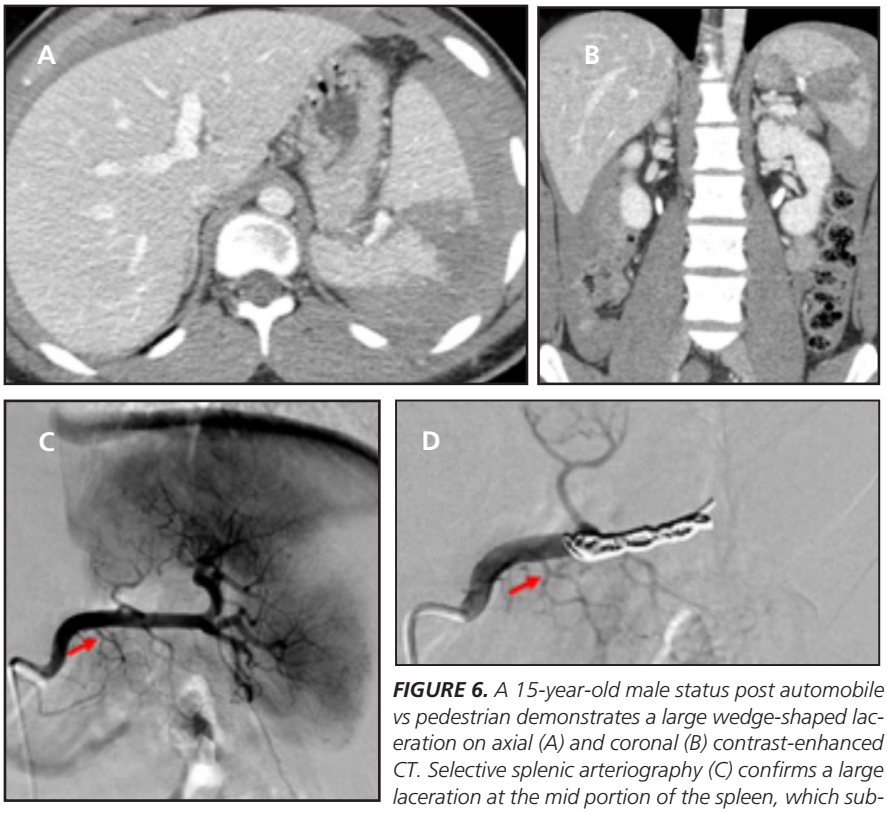

FIGURE 6. *A 15-year-old male status post automobile vs pedestrian demonstrates a large wedge-shaped laceration on axial (A) and coronal (B) contrast-enhanced CT. Selective splenic arteriography (C) confirms a large laceration at the mid portion of the spleen, which subsequently underwent proximal splenic artery embolization (D). The coil mass is deployed distal to the dorsal pancreatic artery (red arrows). No contrast extravasation, pseudoaneurysm, or arteriovenous fistula is seen.*

severity.[7] The 2018 version reflects advancements of newer CT scanners and the relative success of nonoperative management (NOM). Notably is the addition of vascular injury on imaging as an indicator of high-grade injury. This includes pseudoaneurysm and arteriovenous fistula.

The utility of repeat CT imaging in the acute inpatient setting is controversial. In a study by Davis et al with 524 patients, NOM failure was most likely to occur within the first 72 hours following traumatic injury.[8] Their protocol of repeat CT with intravenous contrast at 48-72 hours after initial imaging found that 74% of splenic pseudoaneurysms were not present on initial imaging. Subsequent angioembolization lowered the overall failure rate for NOM to 6%. However, a study by Haan et al with 472 patients and a similar protocol found only 2 cases of delayed vascular injury on follow-up CT imaging, of which both were preceded by a drop in hematocrit.[9] The average AAST injury grade in this study was 1.8, which may indicate that repeat CT imaging may not be necessary for low-grade splenic injuries.

The use of angiographic embolization varies by institution with no accepted practice guidelines or consensus on patient selection criteria.[5,10] Some institutions favor aggressive endovascular management by performing embolization as the predominant therapy for grade III-V injuries and reserve surgery for patients with hemodynamic instability or peritonitis. Other institutions favor medical or surgical management as the first-line therapy and reserve endovascular techniques for active extravasation. Factors associated with NOM failure include age (> 55), high-grade injury (> grade III), active extravasation, large-volume hemoperitoneum, concomitant solid organ injury and vascular abnormalities.[5]

Most authors support the recommendation of splenic surgery or angioembolization for grade IV and higher injuries, meaning any injury with evidence of a vascular component such as active hemorrhage or pseudoaneurysm.[10] According to Martin et al, "literature supports practice paradigms with aggressive IR intervention in grades IV-V injuries and injuries with evidence of active arterial injury."[11] The Eastern Association for the Surgery of Trauma (EAST) recommends consideration of angiography for patients with AAST splenic injury grade III or higher, the presence of a contrast blush, moderate hemoperitoneum, or evidence of ongoing splenic bleeding.[12]

Three common interventional radiology techniques used in the trauma setting include: transarterial embolization

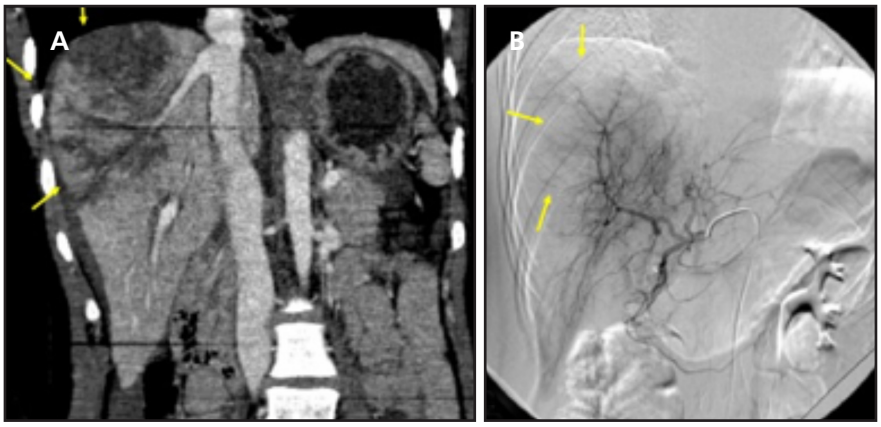

FIGURE 7. *Contrast-enhanced axial CT (A) illustrates a grade IV injury involving most of the right hepatic lobe (yellow arrows). No active extravasation is seen. Selective arteriography (B) shows abnormal perfusion characteristics of the right hepatic lobe corresponding to CT findings (yellow arrows). Right hepatic artery embolization was performed using Gelfoam.*

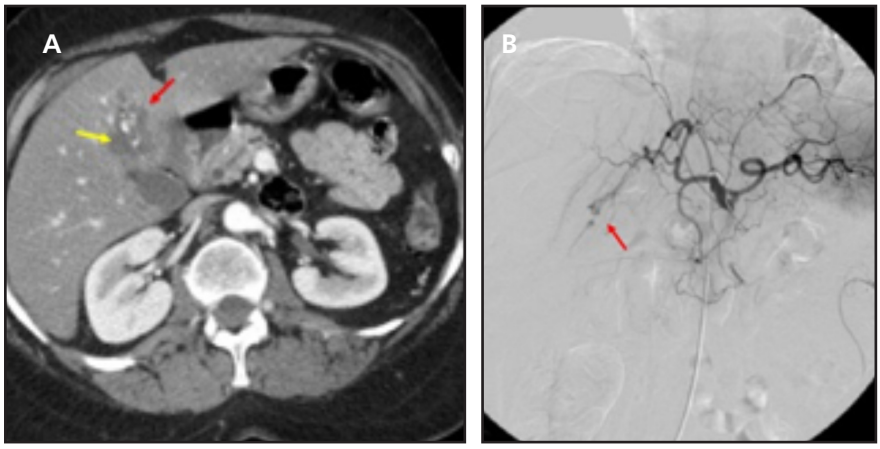

FIGURE 8. *Contrast-enhanced axial CT (A) illustrates a grade IV injury of the liver with multiple small ovoid areas of enhancement within an intraparenchymal hematoma consistent with traumatic pseudoaneurysm (arrows). Selective arteriography (B) shows small pseudoaneurysms (red arrow) within a branch of the segment 4 hepatic artery. Proximal superselective segment 4 hepatic artery embolization was performed using Gelfoam.*

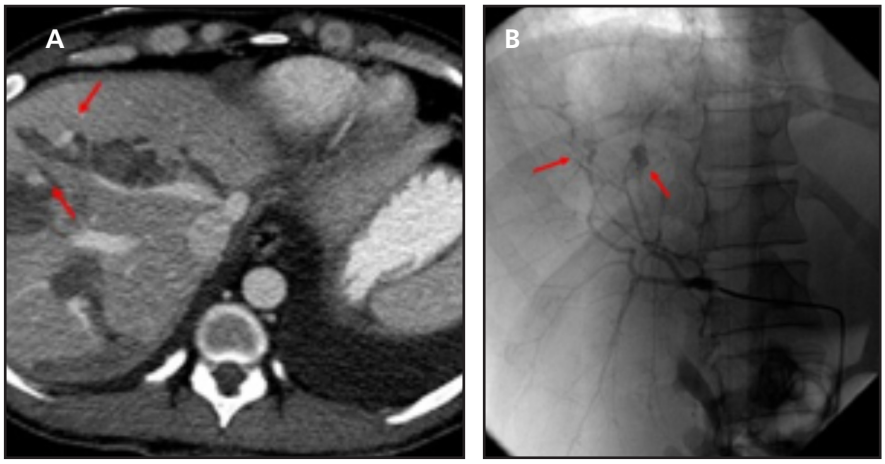

FIGURE 9. *Contrast-enhanced axial CT (A) illustrates a grade IV hepatic injury with pseudoaneurysms (red arrows). Selective arteriography (B) shows hepatic artery pseudoaneurysms corresponding to CT findings (red arrows). Segment VIII and IVa hepatic artery embolization was performed using Gelfoam.*

(TAE), balloon occlusion, and stent grafts.[13] Splenic arterial embolization (SAE) has proven successful with 3 general methods: proximal embolization, distal embolization, or a combination of both (**Figure 4**). Proximal embolization entails deploying coils or plugs approximately 2 cm distal to the dorsal pancreatic artery and is typically performed for diffuse splenic trauma (eg, shattered spleens and/or multiple areas of contrast extravasation) allowing collateral circulation from pancreatic, gastroduodenal, and gastric branches to maintain distal parenchymal perfusion (**Figure 5**). Distal embolization may be performed with Gelfoam (Pfizer Inc., New York, NY) distributed by flow or superselective embolization of a focal defect or single injured vessel with coils or particles, with the latter technique requiring increased time and technical skill (**Figure 6**).[13,14]

Splenic artery embolization carries a high success rate. A systematic review and meta-analysis performed by Rong et al of 876 patients with 2 study sets demonstrated a primary success rate of SAE to be 90% with an overall incidence of severe complications at 20% and cases requiring further surgical intervention even fewer at 6%.[15] Although success rates were higher for proximal embolization, no statistically significant differences between success rates and embolization location were identified, although the study suggested a reduced risk of adverse events with proximal SAE compared to distal and combination embolization. The use of coils is associated with higher success rates and a lower risk of developing life-threatening complications compared to Gelfoam.[15]

Hepatic Injury

Similar to splenic trauma, hemodynamic status and contrast CT imaging are the cornerstones in directing management by assessing the liver parenchyma as well as evaluating for other signs of injury including hemoperitoneum, pneumoperitoneum, hepatic

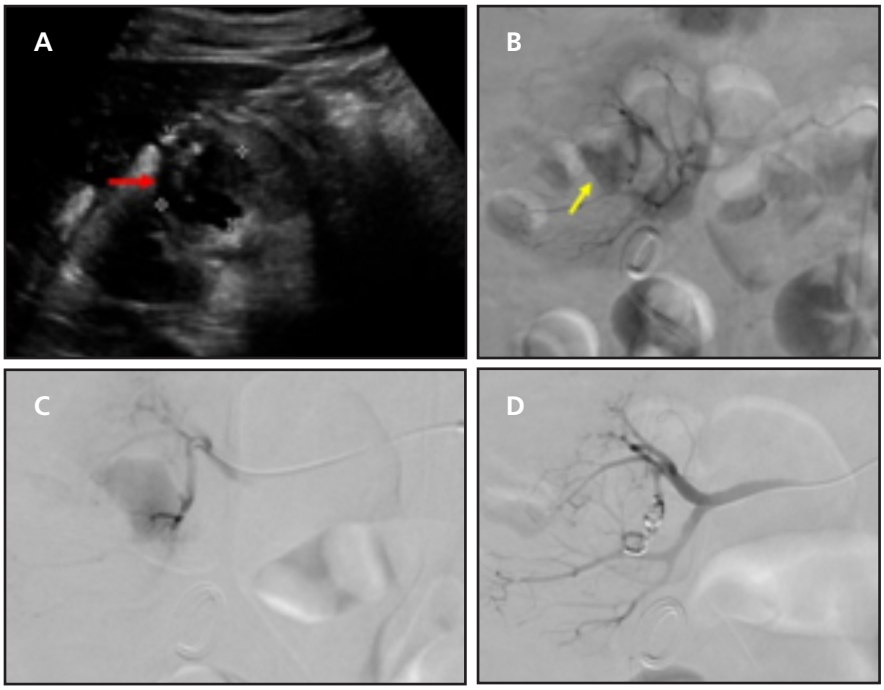

FIGURE 10. *A 59-year-old female with dropping hemoglobin after a partial nephrectomy for renal cell carcinoma. Postoperative retroperitoneal ultrasound (A) confirms a hematoma (red arrow). Right renal artery digital subtraction angiography (B) demonstrates a pseudoaneurysm from the middle segmental branch (yellow arrow). Selective angiography of the middle segmental branch (C) confirms pseudoaneurysm. The patient underwent a successful coil embolization (D) with 23mm coil resulting in thrombosis of the pseudoaneurysm.*

venous injury, periportal low attenuation, sentinel clot(s), additional organ injuries, and active bleeding (**Figure 7, 8**).[16] Active hemorrhage is identified by a contrast blush, seen as a hyperattenuating focus on arterial or venous phase imaging and has a similar Hounsfield unit with nearby arterial vasculature.[16] If there is uncertainty as to whether the hyperattenuating focus represents active hemorrhage, delayed images may show worsening contrast extravasation or morphologic changes.

Follow-up CT with intravenous contrast may play a role in management. Re-evaluation using CT is recommended when there is a persistent systemic inflammatory response syndrome (SIRS), increasing or persistent abdominal pain, jaundice, or a decrease in hemoglobin. Even in asymptomatic patients repeat CT may be useful. A study involving 259 patients with blunt liver trauma reimaged patients 4-5 days following traumatic injury and found that 3% of asymptomatic patients had developed a pseudoaneurysm.[17] In a study by Yoon et al, the authors explained that CT is useful in the assessment of delayed complications of blunt liver trauma, including hemorrhage, hepatic or perihepatic abscess; post-traumatic pseudoaneurysm; hemobilia; and biliary complications such as biloma and bile peritonitis.[18] Their study also confirmed that follow-up CT is needed for patients with high-grade liver injuries to mitigate future issues requiring intervention.

The AAST scale for liver injury demarcates 5 grades of splenic injury (grades I-V) with a higher number indicating worse severity.[7] Hepatic trauma can be divided into 3 management classifications: NOM, TAE, and surgery. CT can accurately characterize the severity of hepatic injury and has reduced the number of patients undergoing surgery. According to EAST, "NOM of blunt hepatic injuries currently is the treatment modality of choice in hemodynamically stable patients, irrespective of the grade of injury or patient age," but only in an environment that can support monitoring for acute decompensation and provide emergent interventional or surgical management.[19] Patients with hemodynamic instability or peritonitis still require surgical intervention as the first-line option; however, TAE may be considered before surgery if the patient transiently responds to resuscitative efforts and imaging shows identifiable arterial bleeding.

Even in high-grade injuries, the use of NOM in hemodynamically stable patients remains successful. A meta-analysis conducted by Melloul et al utilized data from 4743 patients with grade III-V hepatic injury. NOM in hemodynamically stable patients with grade III-V hepatic injury showed a success rate of 82% to 100%, an overall 90-day mortality rate of 0% to 8%, and liver-related mortality of 0% to 4%. Similarly, TAE showed a success rate of 81% to 100%, with biliary leak cited as the most common complication (5.9%).[20] TAE should be utilized after the identification of contrast blush on CT imaging. A retrospective series with 351 blunt hepatic trauma patients identified high-grade injury (grade III-V) and CT angiographic contrast blush as prognostic indicators for the likelihood of NOM failure.[21] In those patients, TAE in NOM can reduce the likelihood of failure and the need for surgery (**Figure 9**).

TAE can also be used if clinical signs indicate continuing or worsening hemorrhage in the setting of known hepatic injury. Celiac and mesenteric arteriography localizes previously seen or clinically suspected active hemorrhage. Even without a blush on CT, angiography and TAE may be performed if a patient shows clinical signs of hemorrhage. One study identified all liver trauma patients with severe liver injuries from their institution over 10 years, regardless of hemodynamic status, and all underwent TAE with a success rate of 90%.[22]

Hepatic TAE is successful and generally well tolerated by patients with procedure-related death being

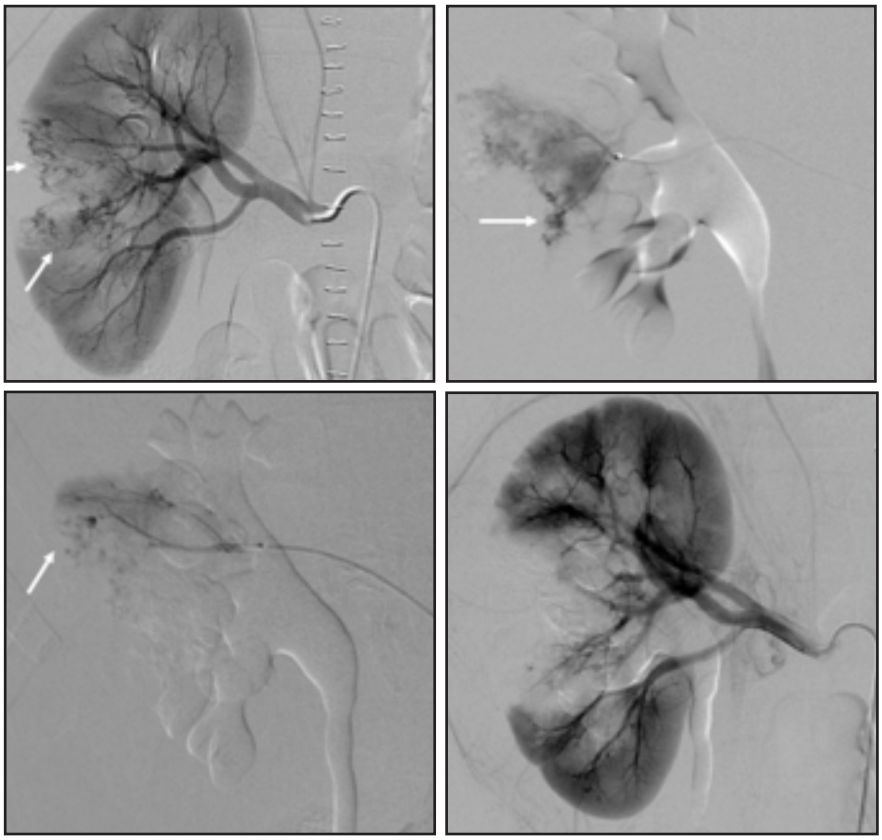

FIGURE 11. *A 23-year-old trauma patient who sustained an abdominal gunshot wound. This patient had an exploratory laparotomy with surgical fixation of a liver laceration and washout of a peri-renal hematoma. Postoperatively, the patient presented with hematuria and continuous drop in hemoglobin. Renal angiography (A) demonstrates innumerable pseudoaneurysms and an area of devascularization (arrows). Selective angiography of the superior segmental renal artery (B) demonstrates pseudoaneurysms (arrow). Selective angiography of the middle segmental renal arteries (C) also demonstrates pseudoaneurysms (arrow). Both branches were embolized with Gelfoam (D), resolving the pseudoaneurysms.*

extremely rare.[23] A systematic review by Virdis et al evaluated 3855 patients and found success rates of TAE to range between 80% to 97%.[24] All-cause mortality following TAE is < 10%; the risk of liver-related mortality is rated at 6%; and the most significant possible risks of TAE include bile leak at 5.7%, hepatic necrosis, and abscess.[24] Other risks include gallbladder infarct if the right hepatic artery is embolized without careful attention to the cystic artery.[24,25] Most TAE complications can be treated with NOM or endovascular approaches, such as percutaneous drainage, cholangiography or endoscopic retrograde cholangiopancreatography.[24,25]

Biliary and hepatic venous injury can also be repaired by interventional radiology. Hepatic venous trauma is almost always handled surgically, but there are cases of endovascular repair in which 2 endovascular covered stents were successfully placed to bridge flow from the hepatic vein to the IVC following traumatic injury.[25] Biliary injuries may develop into a complicating biloma, abscess, stricture, or arteriobiliary fistula, all of which are amenable to repair through percutaneous transhepatic cholangiography, stenting, embolization, and/or drain placement.[26,27]

Renal Injury

The kidneys are the third most common abdominal organ to be traumatically injured. Blunt trauma is a major mechanism, but there is an increasing number of iatrogenic causes (both during interventional and intraoperative procedures) due to the rise in interventional procedures such as renal artery angioplasty, stenting, percutaneous biopsy, nephrostomy, and nephro-ureterolithotomy (**Figures 10-12**).[28]

Traumatic renal injuries are identified on CT imaging with intravenous contrast and graded using the AAST classification system (grade I-V, with grade V the most severe), which takes into account specific complications such as renal vascular thrombosis, segmental renal artery or vein injury, and damage to the collecting system.[7] There has been a trend toward the NOM of renal traumatic injury that is often institution-dependent and based on the injury grade and the patient's clinical status. Grade I-III parenchymal or vascular injuries are always initially managed conservatively with observation.[29] NOM is also increasingly becoming the standard of care for grades IV and V parenchymal injury provided the patient is hemodynamically stable and there is no evidence of active contrast extravasation or urine leakage. A multicenter study of 206 patients with grade IV or V blunt renal injury demonstrated safe NOM of hemodynamically stable patients, with a nonoperative failure rate of 7.8%.[30] Furthermore, NOM decreases ICU stay, lowers transfusion requirements, and yields fewer complications.[31] Current guidelines from the American Urological Society recommend observation in hemodynamically stable patients and intervention in hemodynamically unstable patients.[32]

Surgical treatment is always indicated for hemodynamically unstable patients, in grade V vascular injury (avulsion of the renal artery, vein, or collecting system), and in expanding retroperitoneal hematomas discovered during exploratory laparotomy for other abdominal injury. Ureteral stenting is the treatment of choice in lacerations involving the collecting system and ureteropelvic junction laceration.[29]

Several retrospective studies have shown early follow-up CT imaging does not detect or prevent any urologic

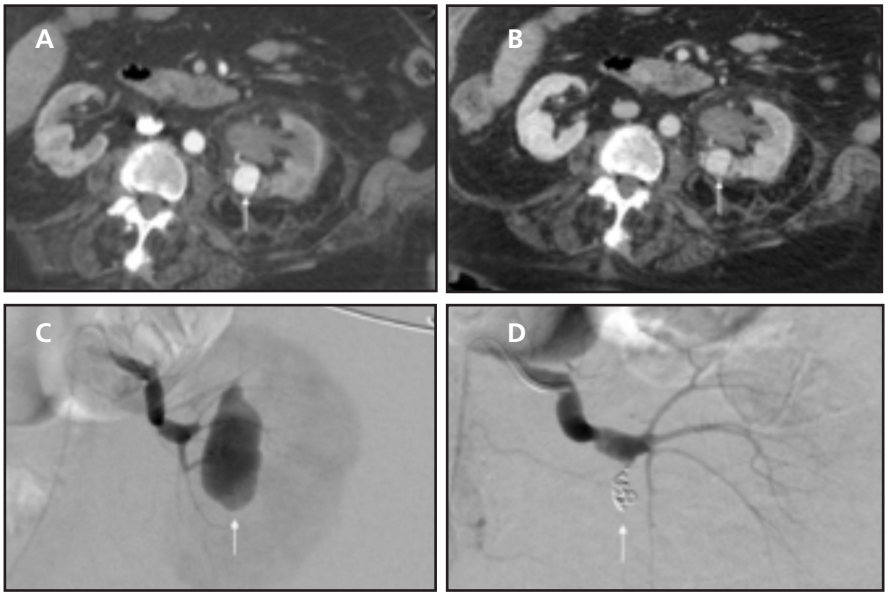

FIGURE 12. *A 75-year-old woman presenting with hematuria 1 month after wedge resection of left kidney for renal cell carcinoma. CT shows a left kidney focus of enhancement (arrows) in the (A) early arterial phase that persists in the late arterial phase (B), matching the contrast density of the aorta, findings consistent with pseudoaneurysm. Angiography (C) of left renal artery shows a pseudoaneurysm (arrow) arising from an inferior polar branch of the renal artery. The patient underwent a successful thrombosis (D) of the pseudoaneurysm and regained normal flow to the remaining kidney.*

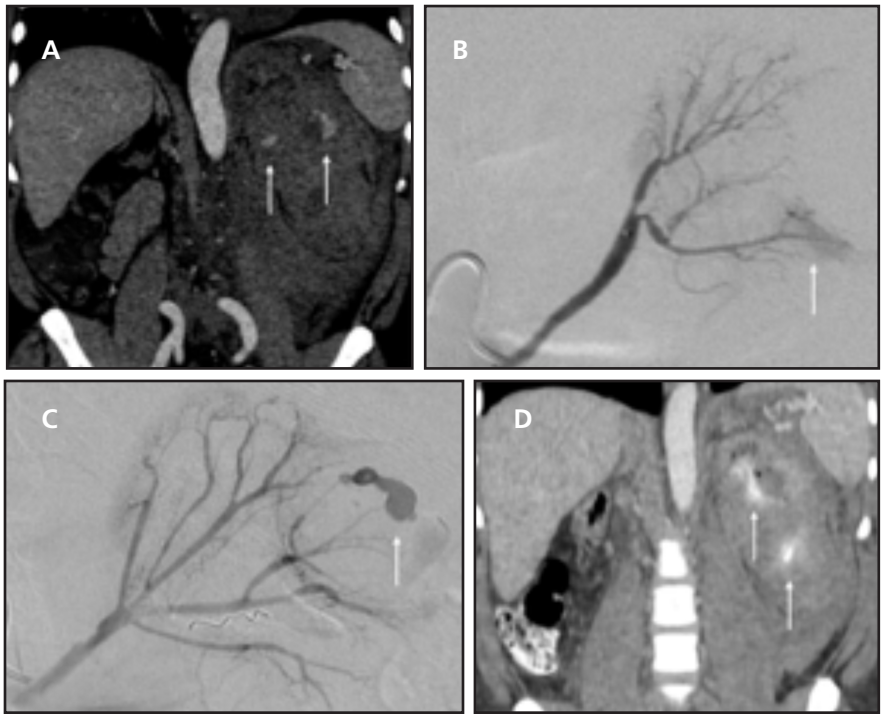

FIGURE 13. *A 31-year-old man with end-stage renal disease presenting with acute left back pain. Contrast-enhanced angiographic phase CT (A) demonstrates multiple foci of contrast extravasation (arrows) in a large heterogeneous left retroperitoneal hematoma. Angiography of inferior polar left renal artery (B) shows contrast extravasation (arrow), which was superselectively embolized with a 3mm coil and Gelfoam. Superior polar angiography (C) shows an additional area (arrow) of contrast extravasation/pseudoaneurysm formation, which was again superselectively embolized with a 3mm coil and Gelfoam. Previously seen contrast extravasation from the inferior polar branch is now resolved. A follow-up contrast-enhanced CT (D) demonstrates no evidence of contrast extravasation.*

complications. For example, a study at the University of Tennessee of 207 patients who sustained grade I-III renal injury found that follow-up CT with intravenous contrast in renal cortical and excretory phases did not detect or prevent any urologic complications.[33] Another study at Cork University Hospital of 102 patients with grade I-V renal injury demonstrated all complications of renal trauma were symptomatic.[34] The European Association of Urology Guidelines refer to repeat imaging for renal injuries and recommend repeat CT imaging in grades I-IV only if the patient demonstrates clinical deterioration such as fever, flank pain, and decreasing hemoglobin.[35]

Interventional radiology is slowly taking a larger role in the treatment of blunt renal trauma with selective renal artery embolization (**Figure 13**); however, there is little data reported in the literature.[29] A study of 20 patients who underwent renal artery embolization for blunt trauma and gross hematuria demonstrated successful cessation of bleeding in all patients.[36] A study of 52 patients with grade III or IV renal laceration showed peri-renal hematoma size and contrast extravasation to be predictors for renal artery embolization.[37] Renal pseudoaneurysm is another possible vascular injury from blunt renal trauma. Again, data are limited to case series, including a study of 5 patients treated successfully with embolization.[38]

Conclusion

Identification and management of abdominal organ injury is rapidly evolving. Injuries once identified and treated operatively are now diagnosed by CT and predominantly treated nonoperatively and/or via interventional techniques in hemodynamically stable patients. These more conservative and minimally invasive techniques are driven by the goals of increased patient safety and reduced morbidity and mortality. Given these trends, there will likely be an increasing role for interventional radiology in patient management and treatment as part of a multidisciplinary clinical team.

References

1. World Health Organization. Injuries and violence: the facts 2014. http://www.who.int/iris/handle/10665/149798. Accessed March 21, 2019.
2. Valji K. hepatic, splenic, and portal vascular systems. In: *Vascular and Interventional Radiology.* 2nd ed. Philadelphia: Saunders; 2006:269-319.
3. Hassan R, Abd Aziz A, Md Ralib AR, Saat A. Computed tomography of blunt spleen injury: a pictorial review. Malays J Med Sci 2011;18(1):60-67.
4. Joseph B, Khalil M, Rhee P. Penetrating injuries to the spleen and kidney: an evolution in progress. Curr Trauma Reports 2015;1(2):76-84. doi:10.1007/s40719-015-0016-9.
5. Zarzaur BL, Rozycki GS. An update on nonoperative management of the spleen in adults. Trauma Surg Acute Care Open. 2017;2(1):e000075. doi:10.1136/tsaco-2017-000075.
6. Orwig D, Federle M. Localized clotted blood as evidence of visceral trauma on CT: the sentinel clot sign. Am J Roentgenol 1989;153(4):747-749. doi:10.2214/ajr.153.4.747.
7. Kozar RA, Crandall M, Shanmuganathan K, et al. Organ injury scaling 2018 update. J Trauma Acute Care Surg 2018;85(6):1119-1122. doi:10.1097/TA.0000000000002058.
8. Davis KA, Fabian TC, Croce MA, et al. Improved success in nonoperative management of blunt splenic injuries: embolization of splenic artery pseudoaneurysms. J Trauma 1998;44(6):1008-1013; discussion 1013-5. http://www.ncbi.nlm.nih.gov/pubmed/9637156. Accessed April 10, 2019.
9. Haan JM, Boswell S, Stein D, Scalea TM. Follow-up abdominal CT is not necessary in low-grade splenic injury. Am Surg 2007;73(1):13-18. http://www.ncbi.nlm.nih.gov/pubmed/17249449. Accessed April 10, 2019.
10. Saksobhavivat N, Shanmuganathan K, Chen HH, et al. Blunt splenic injury: use of a multidetector CT-based splenic injury grading system and clinical parameters for triage of patients at admission. Radiology 2015;274(3):702-711. doi:10.1148/radiol.14141060.
11. Martin JG, Shah J, Robinson C, Dariushnia S. Evaluation and management of blunt solid organ trauma. Tech Vasc Interv Radiol 2017;20(4):230-236. doi:10.1053/j.tvir.2017.10.001.
12. Stassen NA, Bhullar I, Cheng JD, et al. Selective nonoperative management of blunt splenic injury: an Eastern Association for the Surgery of Trauma practice management guideline. J Trauma Acute Care Surg 2012;73(5 Suppl 4):S294-300. doi:10.1097/TA.0b013e3182702afc.
13. Gould JE, Vedantham S. The role of interventional radiology in trauma. Semin Intervent Radiol 2006;23(3):270-278. doi:10.1055/s-2006-948766.
14. Lopera JE. Embolization in trauma: principles and techniques. Semin Intervent Radiol 2010;27(1):14-28. doi:10.1055/s-0030-1247885.
15. Rong J-J, Liu D, Liang M, et al. The impacts of different embolization techniques on splenic artery embolization for blunt splenic injury: a systematic review and meta-analysis. Mil Med Res 2017;4:17. doi:10.1186/s40779-017-0125-6.
16. Soto JA, Anderson SW. Multidetector CT of blunt abdominal trauma. Radiology 2012;265(3):678-693. doi:10.1148/radiol. 12120354.
17. Østerballe L, Helgstrand F, Axelsen T, Hillingsø J, Svendsen LB. Hepatic pseudoaneurysm after traumatic liver injury: is CT follow-up warranted? J Trauma Manag Outcomes 2014;8:18. doi:10.1186/1752-2897-8-18.
18. Yoon W, Jeong YY, Kim JK, et al. CT in blunt liver trauma. Radiographics 2005;25(1):87-104. doi:10.1148/rg.251045079.
19. Stassen NA, Bhullar I, Cheng JD, et al. Nonoperative management of blunt hepatic injury: an Eastern Association for the Surgery of Trauma practice management guideline. J Trauma Acute Care Surg 2012;73(5 Suppl 4):S288-93. doi:10.1097/TA.0b013e318270160d.
20. Melloul E, Denys A, Demartines N. Management of severe blunt hepatic injury in the era of computed tomography and transarterial embolization: a systematic review and critical appraisal of the literature. J Trauma Acute Care Surg 2015;79(3):468-474. doi:10.1097/TA.0000000000000724.
21. Xu H, Jie L, Kejian S, et al. Selective angiographic embolization of blunt hepatic trauma reduces failure rate of nonoperative therapy and incidence of post-traumatic complications. Med Sci Monit 2017;23:5522-5533.
22. Inukai K, Uehara S, Furuta Y, Miura M. Nonoperative management of blunt liver injury in hemodynamically stable versus unstable patients: a retrospective study. Emerg Radiol 2018;25(6):647-652. doi:10.1007/s10140-018-1627-6.
23. Green CS, Bulger EM, Kwan SW. Outcomes and complications of angioembolization for hepatic trauma: A systematic review of the literature. *J Trauma Acute Care Surg* 2016;80(3):529-537. doi:10.1097/TA.0000000000000942.
24. Virdis F, Reccia I, Di Saverio S, et al. Clinical outcomes of primary arterial embolization in severe hepatic trauma: A systematic review. Diagn Interv Imaging 2019;100(2):65-75. doi:10.1016/j.diii.2018.10.004.
25. Jeph S, Ahmed S, Bhatt RD, Nadal LL, Bhanushali A. Novel use of interventional radiology in trauma. J Emerg Crit Care Med 2017;1(12):40-40. doi:10.21037/jeccm.2017.10.04.
26. Thompson CM, Saad NE, Quazi RR, Darcy MD, Picus DD, Menias CO. Management of iatrogenic bile duct injuries: role of the interventional radiologist. RadioGraphics 2013;33(1):117-134. doi:10.1148/rg.331125044.
27. Stefaczyk L, Polguj M, Szubert W, Chrząstek J, Jurałowicz P, Garcarek J. Arterio-biliary fistulas: What to choose as endovascular treatment? Vascular 2018;26(4):445-448. doi:10.1177/1708538117743178.
28. Loffroy R, Chevallier O, Gehin S, et al. Endovascular management of arterial injuries after blunt or iatrogenic renal trauma. Quant Imaging Med Surg 2017;7(4):434-442. doi:10.21037/qims.2017.08.04.
29. Bonatti M, Lombardo F, Vezzali N, et al. MDCT of blunt renal trauma: imaging findings and therapeutic implications. Insights Imaging 2015;6(2):261-272. doi:10.1007/s13244-015-0385-1.
30. van der Wilden GM, Velmahos GC, Joseph DK, et al. Successful nonoperative management of the most severe blunt renal injuries: a multicenter study of the research consortium of New England Centers for Trauma. JAMA Surg 2013;148(10):924-931. doi:10.1001/jamasurg.2013.2747.
31. Altman AL, Haas C, Dinchman KH, Spirnak JP. Selective nonoperative management of blunt grade 5 renal injury. J Urol 2000;164(1):21-27..
32. Morey AF, Brandes S, Dugi DD 3rd, et al. Urotrauma: AUA guideline. J Urol 2014;192(2):327-335. doi:10.1016/j.juro.2014.05.004.
33. Malcolm JB, Derweesh IH, Mehrazin R, et al. Nonoperative management of blunt renal trauma: is routine early follow-up imaging necessary? BMC Urol 2008;8:11. doi:10.1186/1471-2490-8-11.
34. Breen KJ, Sweeney P, Nicholson PJ, Kiely EA, O'Brien MF. Adult blunt renal trauma: routine follow-up imaging is excessive. Urology 2014;84(1):62-67. doi:10.1016/j.urology.2014.03.013.
35. Summerton DJ, Djakovic N, Kitrey ND, et al. Guidelines on Urological Trauma; 2014. https://uroweb.org/wp-content/uploads/24-Urological-Trauma_LR.pdf. Accessed February 21, 2019.
36. Vozianov S, Sabadash M, Shulyak A. Experience of renal artery embolization in patients with blunt kidney trauma. Cent Eur J Urol 2015;68(4):471-477. doi:10.5173/ceju.2015.491.
37. Nuss GR, Morey AF, Jenkins AC, et al. Radiographic predictors of need for angiographic embolization after traumatic renal injury. J Trauma 2009;67(3):578-82; discussion 582. doi:10.1097/TA.0b013e3181af6ef4.
38. Poulakis V, Ferakis N, Becht E, Deliveliotis C, Duex M. Treatment of renal-vascular injury by transcatheter embolization: immediate and long-term effects on renal function. J Endourol 2006;20(6):405-409. doi:10.1089/end.2006.20.405.