Evaluation of Common Pathology of the Elbow Utilizing Dynamic Ultrasound and MRI

Kelli Rosen, D.O.,[1] Leah Davis, D.O.,[2] Courtney Scher, D.O.[1]

[1]Department of Musculoskeletal Radiology, Henry Ford Hospital, Detroit, MI; [2]Grand Traverse Radiologists, Traverse City, MI

Musculoskeletal ultrasound (US) is an ideal imaging modality for assessing elbow joint anatomy and pathology. The elbow joint is particularly amenable to US evaluation as it is a small joint with 360-degree accessibility by the transducer and is easily manipulated, both actively by the patient and passively by the examiner.[1] Beyond diagnostics, US can also aid in image-guided treatment of certain conditions.

MRI also plays an important role in evaluating the elbow. In addition to soft-tissue anatomy and pathology, MRI also depicts radiographically occult fractures, bone contusions, and intra-articular pathology exquisitely.[2] Magnetic resonance arthrography (MRA) utilizing gadolinium-based contrast placed directly into the joint allows for optimal evaluation of articular cartilage/intracapsular structures, intra-articular loose bodies, and the collateral ligaments.[1,2]

This article will review the anatomy and pathology of the elbow joint and review the US examination by compartment, featuring the most pertinent anatomic structures and their related pathology (**Table 1**). Correlative MRI evaluation of the elbow joint and pathology will also be discussed.

Osseous Articulations

The ulnohumeral articulation is a hinge joint, providing the majority of flexion and extension motion at the elbow. The radiocapitellar articulation is a "hinge and pivot" joint without inherent osseous mobility. The proximal radioulnar joint, held in place by the annular ligament, allows for rotation of the radial head in the sigmoid notch of the ulna in supination and pronation. These three articulations, as well as anterior and posterior fat pads, are encased by the joint capsule.[3]

Many muscles, tendons, ligaments, and nerves work together with this bony foundation to create the elegant, dynamic, and complex function of the elbow joint. These structures and their related pathologies will be discussed further, based on the compartment in which they reside.

Anterior Compartment

Structures of interest in the anterior elbow include the joint recess, distal biceps tendon insertion, brachialis muscle, as well as the median and radial nerves (**Figure 1**).[4,5]

The biceps brachii, composed of a long head originating from the supraglenoid tubercle and a short head from the coracoid process, crosses the shoulder and elbow joints. As it courses distally over the anterior humerus, the muscle bellies of the lateral long head and medial short head gradually, but incompletely, insinuate with one another.

Table 1. Elbow Ultrasound Examination Checklist

Anterior Compartment
Brachialis muscle
Biceps brachii tendon
Median nerve
Radial nerve and posterior interosseous branch (PIN)
Anterior joint recess

Lateral Compartment
Common extensor tendon
Lateral collateral ligament complex
Radiocapitellar joint recess

Medial Compartment
Ulnar collateral ligament
Common flexor tendon and pronator teres
Ulnar nerve

Posterior Compartment
Posterior joint recess
Triceps brachii
Olecranon bursa

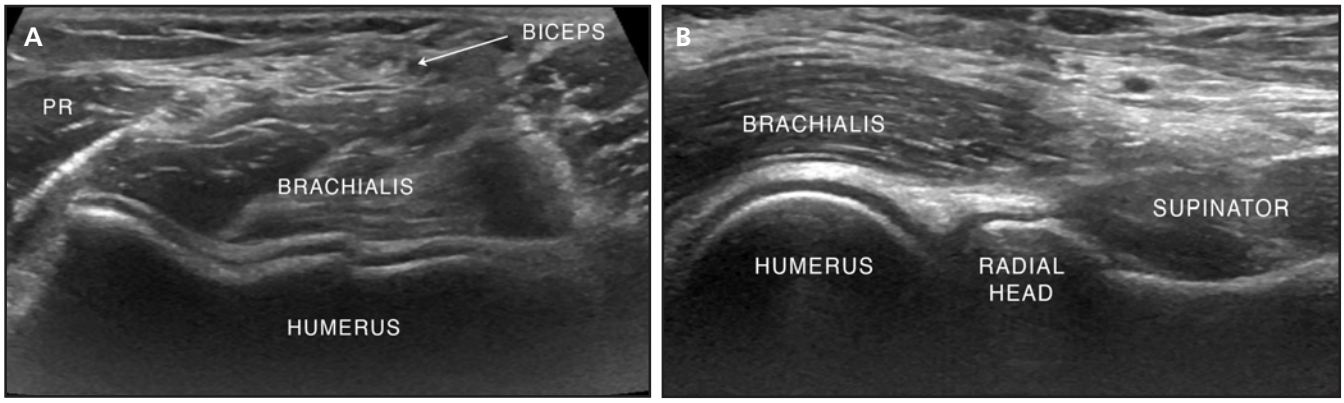

FIGURE 1. *Normal anterior compartment of the elbow. Anterior elbow joint in short axis at the level of distal humerus (A). (PR = Pronator muscle) Radiocapitellar joint in long axis (B).*

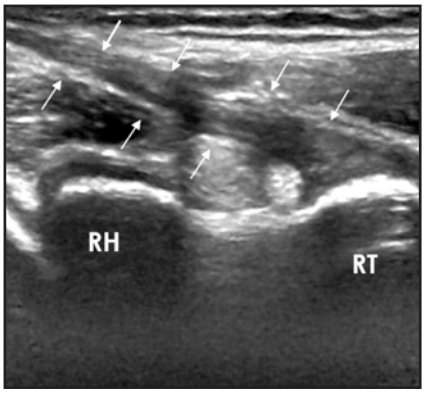

FIGURE 2. *Normal oblique course of the DBT (arrows) in long axis (RH = radial head, RT = radial tuberosity).*

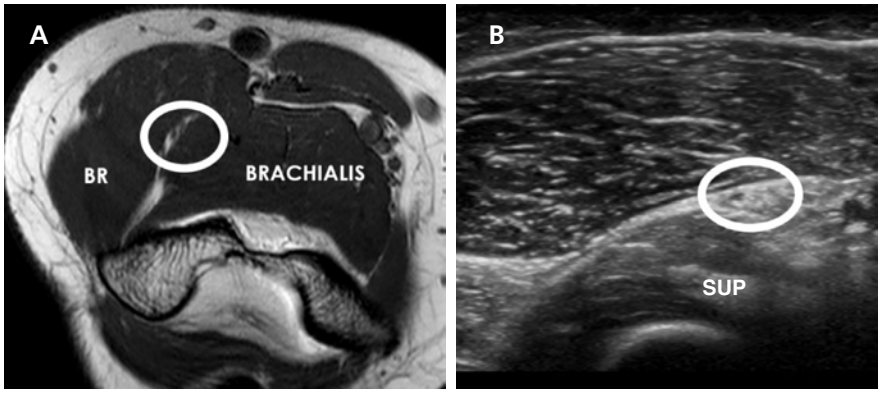

FIGURE 3. *Radial nerve and its PIN. Axial proton-density MRI image: the radial nerve (circle) can be found between the BR and the brachialis muscles proximal to the elbow joint (A). (BR = brachioradialis) US short-axial image: radial nerve (circle) as it branches into the PIN and superficial sensory branch, just superficial to the SUP (B). (SUP = supinator muscle)*

Just proximal to the elbow joint, the biceps brachii muscle separates again into two distinct tendon heads. Both heads contribute to the distal biceps tendon coursing through the cubital fossa and inserting on the radial tuberosity.[6]

Evaluation of the distal biceps tendon (DBT) can be challenging due to its oblique course and deep insertion.[4,5] The normal tendon may appear hypoechoic as it dives deep, secondary to an artifact known as anisotropy.[1] Keeping the probe parallel to the tendon in long axis and perpendicular in short axis is important for avoiding this artifact and causing subsequent misinterpretation. Long-axis images are ideal for evaluating the distal biceps tendon insertion on the radial tuberosity (**Figure 2**).[4,5]

At the anterolateral aspect of the elbow, the radial nerve and its posterior interosseous branch (PIN) can be visualized. Of note, it is important to visualize the PIN as it pierces and then travels through the two heads of the supinator muscle and the Arcade of Frohse (**Figure 3**). The course of the PIN, as it travels from the anterior to the posterior compartments, may be obtained in the transverse plane as the subject pronates the forearm.[4,5]

Distal Biceps Tendon Tear

The biceps tendon is the most powerful forearm supinator and is the most commonly torn tendon in the elbow. Injury is common at or near the insertion of the DBT on the radial tuberosity, owing to its relative hypovascularity in this location.[1] Tendon rupture most often results from acute trauma rather than overuse, and is relatively common in rugby players and weight lifters when the arm is forcefully extended against a flexed elbow.[7] Of note, rupture of the proximal long-head biceps tendon at the shoulder joint is approximately 10 times more common than rupture of the DBT at the elbow.[7]

In the setting of complete tendon rupture, the lacertus fibrosus may prevent retraction of the DBT proximally. If the lacertus fibrosus is also torn, a complete tear can present as a palpable painful mass over the proximal anterior arm. Early diagnosis of a complete DBT tear is critical, as clinical outcome is greatly improved with early surgical intervention within the first few weeks following injury. This is in contrast with tears of the proximal biceps tendon, where conservative treatment is the therapy mainstay.[7]

Complete tear of the DBT is amenable to US diagnosis. Findings include nonvisualization of the tendon at the insertion site with hypoechoic fluid collection/hematoma in the tendinous bed (**Figure 4**). Partial tears of the DBT are

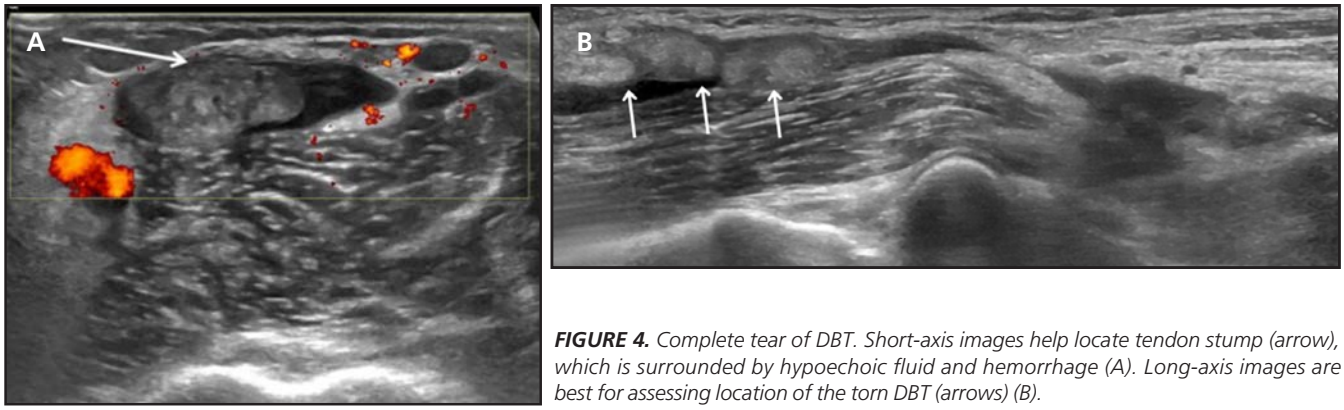

FIGURE 4. *Complete tear of DBT. Short-axis images help locate tendon stump (arrow), which is surrounded by hypoechoic fluid and hemorrhage (A). Long-axis images are best for assessing location of the torn DBT (arrows) (B).*

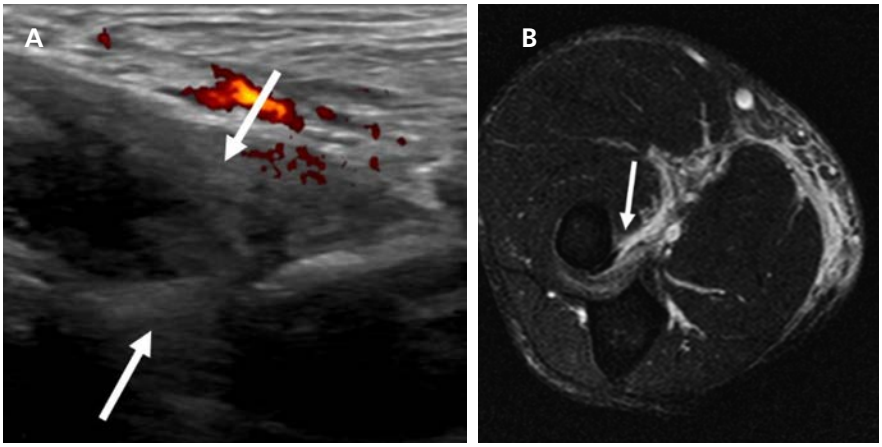

FIGURE 5. *US long-axis image demonstrates irregularity, hyperemia, and a partial tear of the DBT (arrows) (A). MRI axial T2-weighted image shows a partial tear at the insertion of the DBT on the radial tuberosity (arrow) (B).*

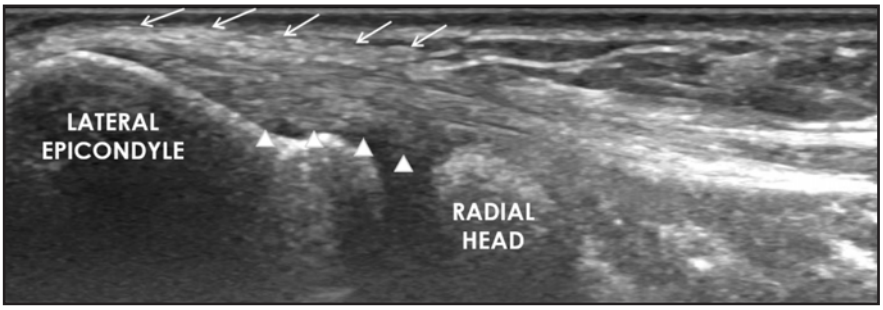

FIGURE 6. *Lateral compartment of the elbow. Normal appearance of the CET (arrows), radial collateral ligament (arrowheads) and radiocapitellar joint in long axis.*

often more difficult to diagnose by US compared to MRI. In the setting of partial DBT tear, the thinned tendon will assume an irregular, attenuated profile or wavy contour (**Figure 5**).[7]

MRI is particularly useful for diagnosing a DBT injury and discerning the degree of severity. DBT is best evaluated on axial images, although fluid-sensitive sagittal images can help confirm a complete rupture and estimate the degree of stump retraction. Focal T2 hyperintensity in and adjacent to the DBT indicate a partial tear (**Figure 5**).[7]

Lateral Compartment

Important lateral elbow structures to evaluate include the common extensor tendon, lateral collateral ligament complex, and radiocapitellar joint.[4,5]

Placement of the transducer longitudinally over the lateral epicondyle will reveal the radiocapitellar articulation, radial collateral ligament (RCL), and overlying thin, long common extensor tendon (CET) (**Figure 6**).[1]

The CET is best visualized on the coronal plane/long axis and is composed of the origins of the extensor carpi radialis longus and brevis, extensor digiti minimi, and extensor digitorum communis tendons.[4,5] On US, the CET is a smooth hyperechoic beak-shaped structure originating from the anterolateral aspect of the lateral epicondyle, with the radial collateral ligament just deep to the tendon origin (**Figure 6**).[1] The radiocapitellar joint is visible deep to the CET and the ligament.[4,5]

Lateral Epicondylitis

Lateral epicondylitis is the most common sports-related elbow injury, classically seen in tennis players, but is also commonly seen secondary to repetitive work-related activities.[7]

Lateral epicondylitis involves the common extensor tendon origin at the lateral epicondyle, with the extensor carpi radialis brevis tendon the most commonly affected.[8] Despite the "-itis" suffix, lateral epicondylitis is degenerative in nature, resulting from overuse of the extensor and supinator muscles.[7,8]

Tendinosis can be recognized by US as an abnormal hypoechoic thickened appearance of the CET origin. Areas of osseous irregularity underlying the CET may be present with hyperemia seen during color or power Doppler interrogation (**Figure 7**). An anechoic cleft with complete or incomplete disruption of tendon fibers will be seen with partial and full thickness tears, respectively.

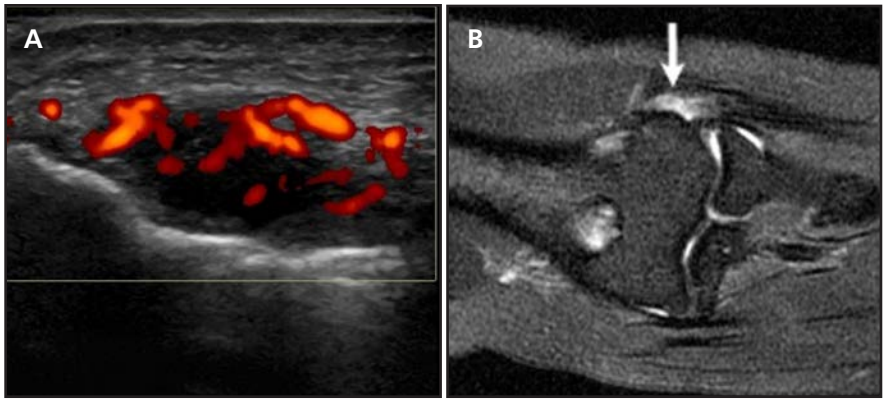

FIGURE 7. *Lateral epicondylitis. Color Doppler long-axis image showing hyperemia, thickening, and hypoechogenicity at CET origin (A). Coronal fat-suppressed T2 MRI with thickening of the common extensor origin and increased T2 signal within the CET origin (arrow) (B).*

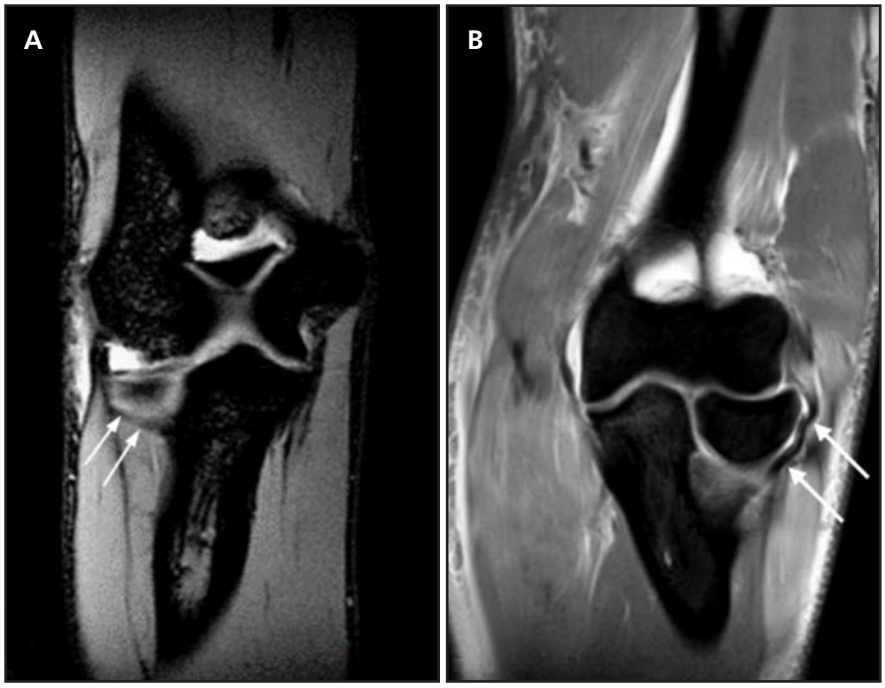

FIGURE 8. *Lateral ulnar collateral ligament. Coronal T1 fat-saturated MRI image from an arthrogram showing a normal intact LUCL (arrows). (A). Coronal T1 fat-saturated MRI image from an arthrogram showing a torn LUCL (arrows). Note the discontinuity distally and the associated laxity of the midportion of the ligament (B).*

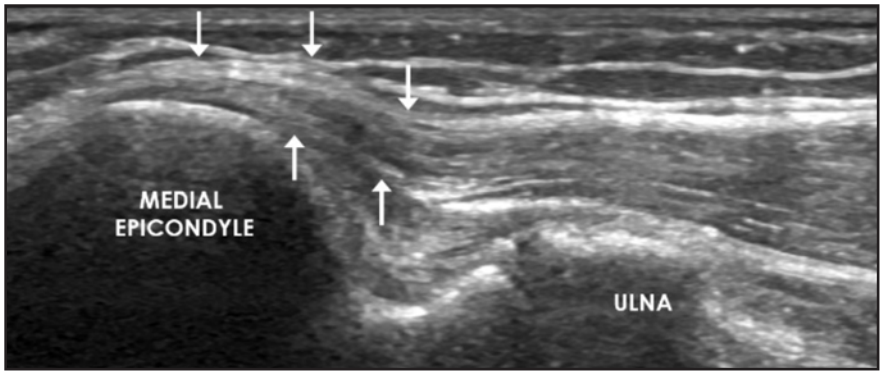

FIGURE 9. *Normal common flexor tendon origin. Longitudinal US image of normal CFT origin (arrows) at the medial epicondyle of the distal humerus.*

On MRI, lateral epicondylitis is demonstrated by intermediate T1- and increased T2-weighted signal representative of intratendinous mucoid degeneration and neovascularization (**Figure 7**). These findings result from microscopic tearing and formation of reparative tissue. Over time, macroscopic tearing or injury to the radial collateral ligamentous complex may also occur. Many secondary findings suggestive of lateral epicondylitis may be observed: bone marrow edema, periostitis of lateral epicondyle, anconeous muscle edema, or fluid in the radial head bursa.[7]

Of special importance in the setting of lateral elbow trauma, is evaluation for concomitant injury of the CET and underlying lateral collateral ligament complex, which can result in posterolateral rotary instability (PLRI). Tears of the RCL are especially important to note as surgical debridement of the CET could result in further destabilization of an already injured RCL.[7]

The lateral ulnar collateral ligament (LUCL) is a component of the lateral collateral ligament complex. It arises from the inferior surface of the lateral epicondyle, taking an oblique medial course to insert on the proximal ulna. It is a primary restraint to varus stress of the elbow and when injured, can also contribute to PLRI. The LUCL is best visualized on coronal MRI sequences (**Figure 8**).[9] It is not reliably well visualized by US.

Medial Compartment

US evaluation of the medial elbow is primarily performed to evaluate the common flexor tendon (CFT), ulnar collateral ligament (UCL), and the ulnar nerve.[4,5]

The CFT origin on the medial epicondyle of the humerus includes the flexor carpi radialis and ulnaris, palmaris longus, flexor digitorum superficialis, and pronator teres tendons. Positioning the transducer longitudinally with the proximal aspect over the medial epicondyle will reveal the CFT in long axis (**Figure 9**).[1]

The UCL is the primary static stabilizer of the elbow against valgus stress.[1]

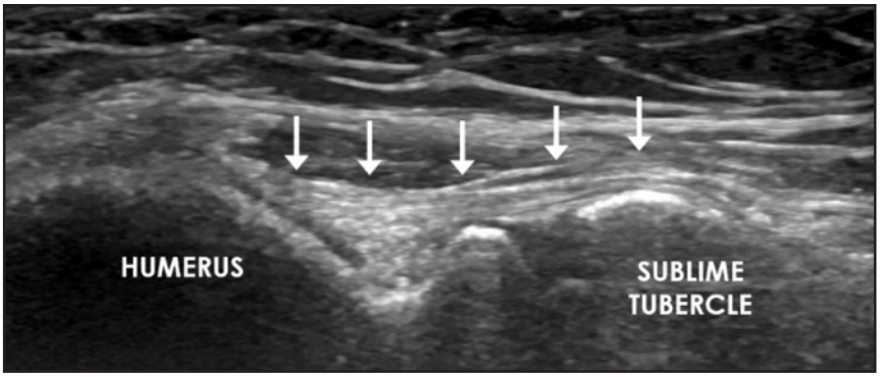

FIGURE 10. *Normal anterior band UCL (arrows).*

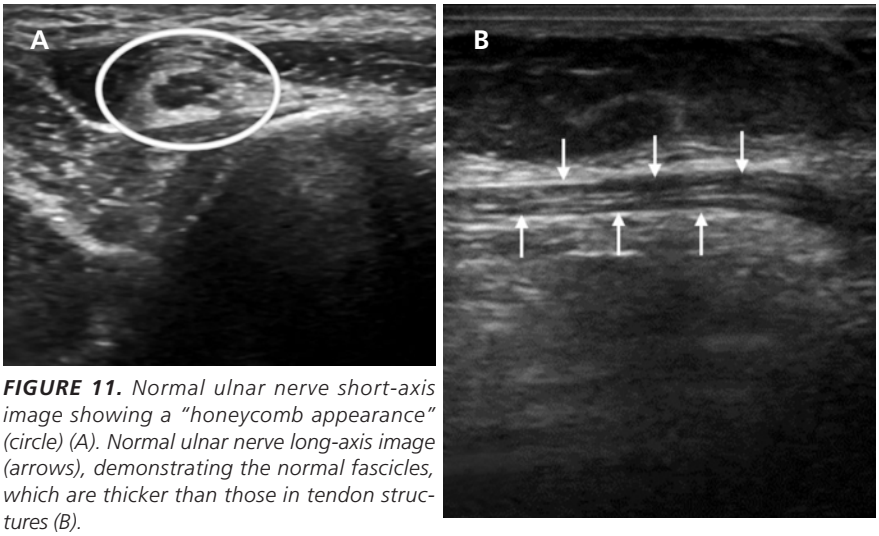

FIGURE 11. *Normal ulnar nerve short-axis image showing a "honeycomb appearance" (circle) (A). Normal ulnar nerve long-axis image (arrows), demonstrating the normal fascicles, which are thicker than those in tendon structures (B).*

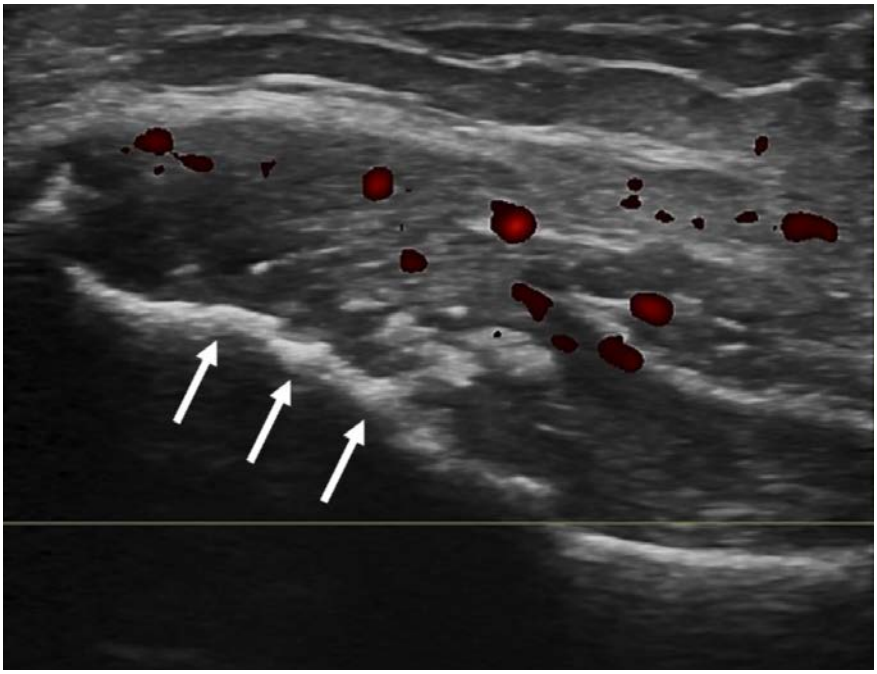

FIGURE 12. *Medial epicondylitis. Long-axis medial epicondyle with thickening, hypoechogenicity, and hyperemia of the CFT origin and slight cortical irregularity of the medial epicondyle (arrows).*

With the probe oriented obliquely longitudinally over the medial epicondyle, the anterior bundle of the UCL will be visible in long axis (**Figure 10**). Dynamic imaging of the UCL with valgus stress on the ulnohumeral joint should also be performed for complete assessment. Subsequent joint space widening will accentuate ligament laxity, if present, and may reveal a partial tear of the ligament.[4,5]

At the level of the cubital tunnel, the ulnar nerve can be well evaluated. In cross-section/short axis, the nerve will appear as a hypoechoic rounded structure surrounded by echogenic fat, creating a honeycomb appearance (**Figure 11**).[1]

Dynamic maneuvers can be performed while visualizing the ulnar nerve in short axis to assess for subluxation or dislocation over the medial epicondyle during elbow flexion.[4,5]

Medial Epicondylitis

Medial epicondylitis, also known as golfer's or pitcher's elbow, develops in the setting of overuse or trauma and involves the CFT at its origin, most commonly affecting the pronator teres and flexor carpi radialis tendons.[4,5,8] Patients may complain of aching pain over the medial elbow and, in chronic cases, grip strength may weaken.[7] Medial epicondylitis is much less common than lateral epicondylitis.[7]

US is an important modality for diagnosing medial epicondylitis and is especially useful to distinguish medial epicondylitis from a tear of the deeper UCL.[7] Tendinosis can be recognized as abnormally thick, hypoechoic areas in the CFT at its origin (**Figure 12**). Additionally, areas of bony irregularity of the medial epicondyle may be present, as well as peritendinous fluid, hyperemia, or soft-tissue swelling.[7,8] An anechoic cleft with complete or incomplete disruption of tendon fibers will be seen with partial and full thickness tears, respectively.[8] Because of the close spatial and functional relationship of the CFT, UCL, and ulnar nerve, these structures are susceptible to concomitant injury. As many as 60% of patients

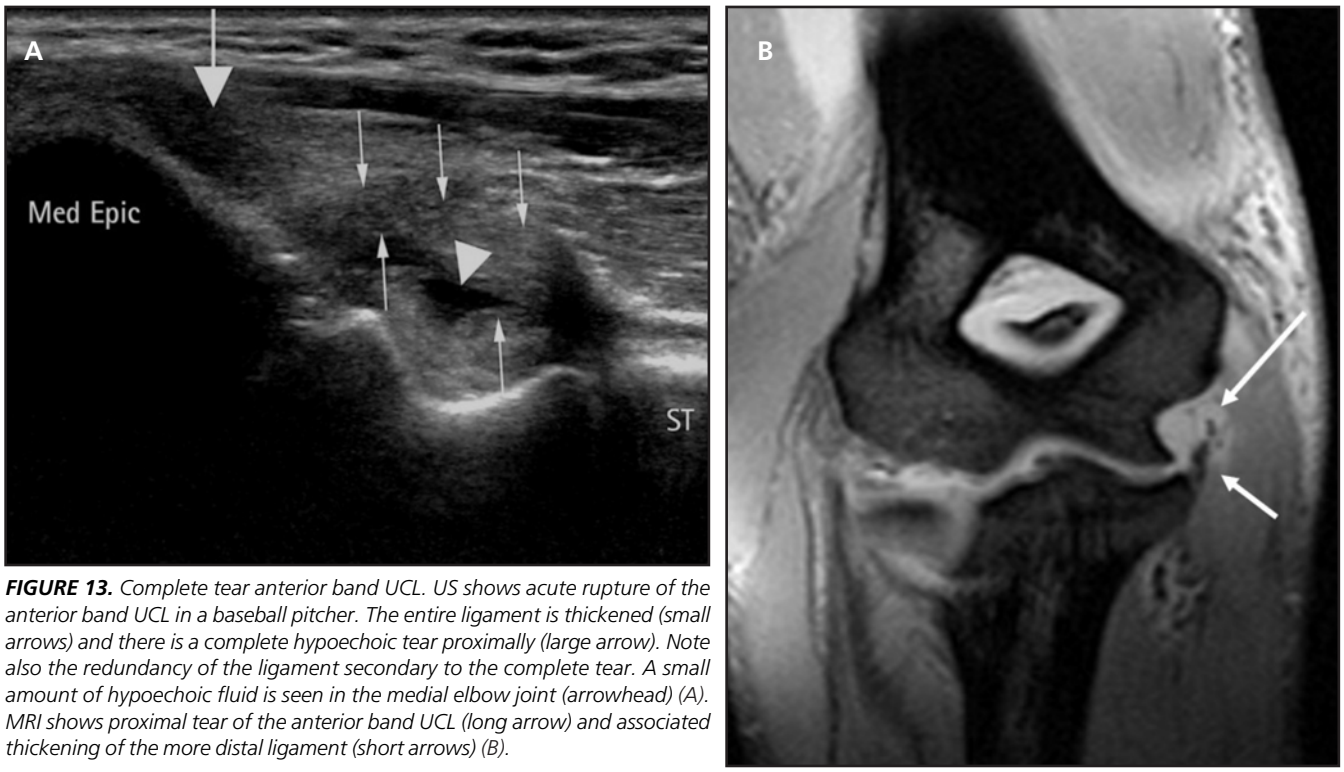

FIGURE 13. *Complete tear anterior band UCL. US shows acute rupture of the anterior band UCL in a baseball pitcher. The entire ligament is thickened (small arrows) and there is a complete hypoechoic tear proximally (large arrow). Note also the redundancy of the ligament secondary to the complete tear. A small amount of hypoechoic fluid is seen in the medial elbow joint (arrowhead) (A). MRI shows proximal tear of the anterior band UCL (long arrow) and associated thickening of the more distal ligament (short arrows) (B).*

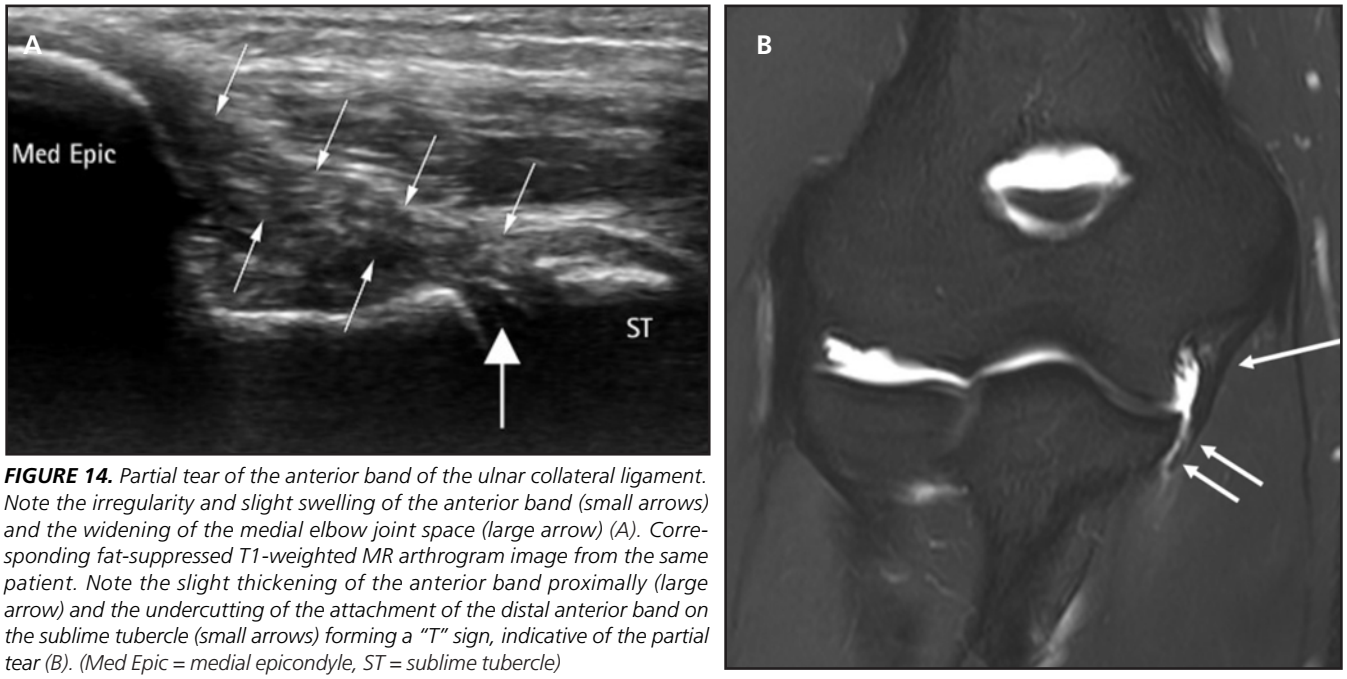

FIGURE 14. *Partial tear of the anterior band of the ulnar collateral ligament. Note the irregularity and slight swelling of the anterior band (small arrows) and the widening of the medial elbow joint space (large arrow) (A). Corresponding fat-suppressed T1-weighted MR arthrogram image from the same patient. Note the slight thickening of the anterior band proximally (large arrow) and the undercutting of the attachment of the distal anterior band on the sublime tubercle (small arrows) forming a "T" sign, indicative of the partial tear (B). (Med Epic = medial epicondyle, ST = sublime tubercle)*

undergoing surgery for medial epicondylitis have been found to exhibit signs of ulnar nerve neurapraxia.[7,10]

MRI imaging in the setting of medial epicondylitis demonstrates increased T1- and T2-weighted signal, representative of intratendinous mucoid degeneration and neovascularization as a result of microscopic tearing and formation of reparative tissue. Over time, macroscopic tearing may occur.[7]

Injury to the Anterior Band of the Ulnar Collateral Ligament

The most clinically relevant and commonly injured component of the UCL is the anterior band that extends from the undersurface of the medial epicondyle to the sublime tubercle on the proximal ulna.[4,5] The UCL is a primary elbow joint stabilizer, providing nearly 50% of the protection against valgus stress. Injury to the anterior band of the UCL is classically seen in

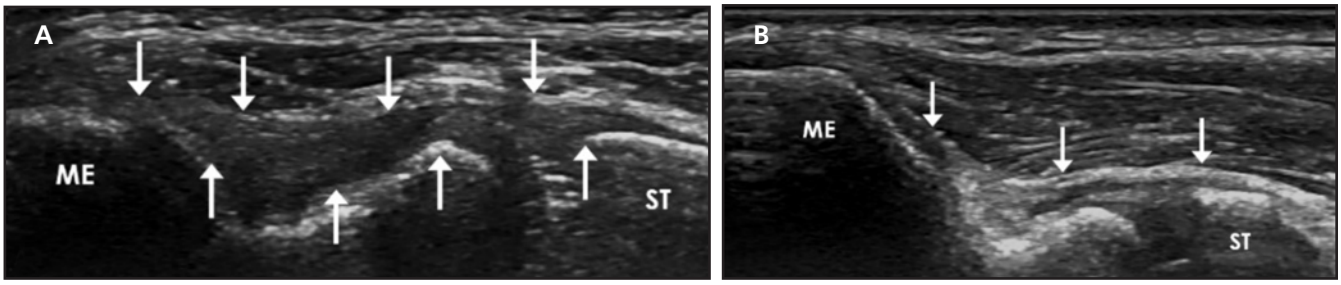

FIGURE 15. *A 15-year-old amateur baseball pitcher with UCL thickening (arrows) and joint space laxity affecting his right side/pitching elbow (A). Contralateral/left elbow in the same patient demonstrates a normal UCL (arrows) and joint space (B). (ME = medial epicondyle, ST = sublime tubercle)*

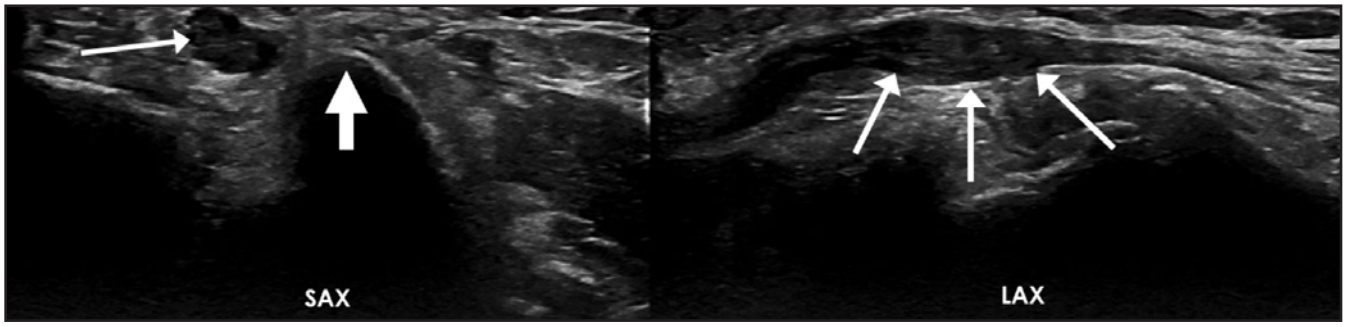

FIGURE 16. *Ulnar nerve compression. Ulnar nerve enlargement in short axis (SAX) and long axis (LAX) at the level of the cubital tunnel showing ulnar nerve thickening (thin arrows). In this case, the neuropathy was due to a large impinging bone spur (thick arrow).*

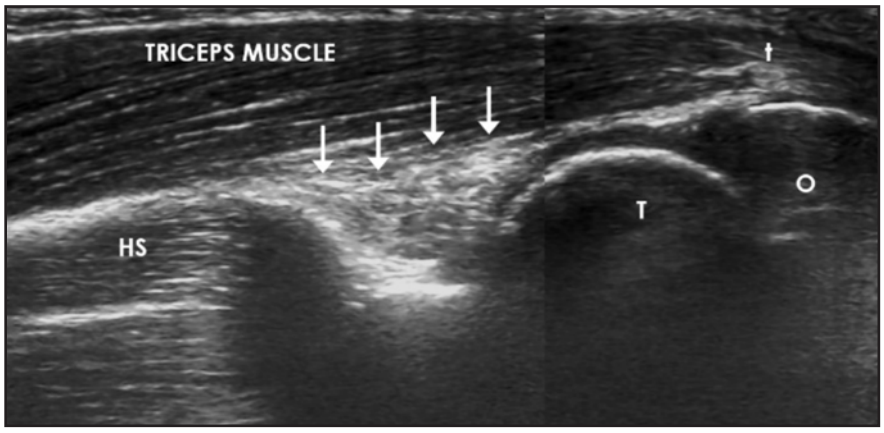

FIGURE 17. *Posterior compartment of the elbow. Normal longitudinal view of the posterior elbow and the olecranon fossa. Note the normal posterior fat pad (arrows) with underlying joint recess. (HS = humeral shaft, T = triceps tendon, T = trochlea, O = olecranon)*

overhead throwing athletes, especially pitchers, secondary to repetitive microtrauma in the form of valgus stress (**Figure 13**). Acute trauma, such as a fall on an outstretched arm, or posterior elbow dislocation, is a less common cause of UCL injury.[7]

On MRI, the UCL is normally homogeneous and hypointense on all sequences. Injury to the UCL is best displayed on coronal MRI images, where it will appear as T2 hyperintense, discontinuous, and ill-defined in shape. While increased signal alone may not be indicative of a tear, signal abnormality with architectural distortion is.[11] Acute injury is also suggested by flexor digitorum superficialis muscle and/or periligamentous edema (**Figure 13**).[7]

Partial tear or sprain of the UCL presents as hypoechoic thickening and/or heterogeneity of the ligament without complete fiber disruption (**Figure 14**). Ligament laxity, demonstrated with valgus stress maneuvers, without ligamentous disruption may indicate remote injury, partial tear, or acquired laxity in high-level overhead athletes such as baseball pitchers. Complete fiber disruption signifies a full thickness tear. In the acute setting with hemorrhage and edema, it may be difficult to discern full and partial thickness tears. Again, dynamic imaging with valgus stress may reveal separation of torn ligament ends, suggesting complete tear.

Of note, professional or high-level amateur pitchers may demonstrate areas of hypoechogenicity or foci of calcification, ligamentous thickening, and laxity without symptoms, especially during the sporting season (**Figure 15**).[8]

Ulnar Nerve Injury

The ulnar nerve at the medial elbow is prone to injury or entrapment, especially as it passes beneath the cubital tunnel and the retinaculum between the medial epicondyle of the humerus and olecranon process. Etiologies for ulnar nerve injury at the elbow include acute trauma, overuse or repetitive injury, and nerve subluxation or dislocation.[8]

Ulnar nerve entrapment, or cubital tunnel syndrome, is a common elbow pathology. US will reveal an enlarged, hypoechoic ulnar nerve proximal to the cubital tunnel (**Figure 16**). Within the tunnel, the nerve often normalizes in

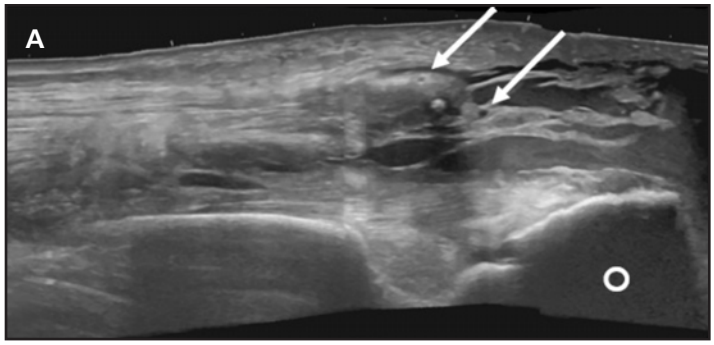

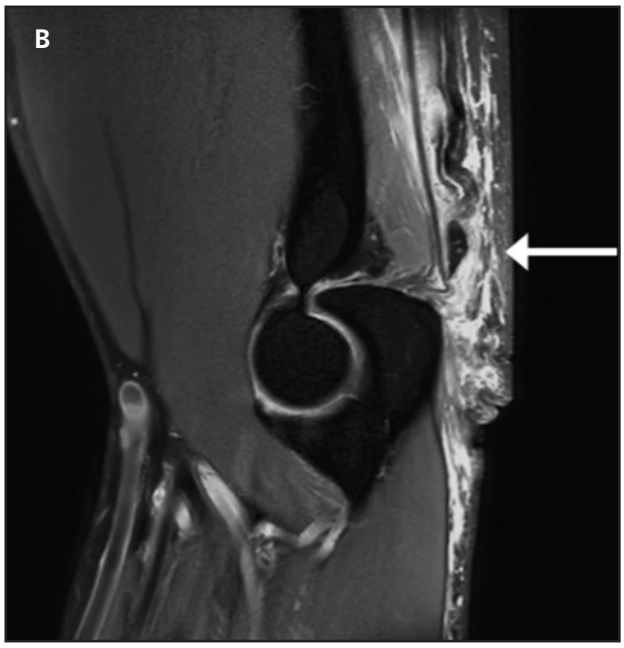

FIGURE 18. *Complete tear of the triceps tendon (arrows) from the olecranon. Fluid is seen surrounding the tendon stump and within the overlying soft tissues (A). (O = olecranon) Sagittal MRI with full thickness avulsion of the tendon with retracted tendon stump (arrow) (B).*

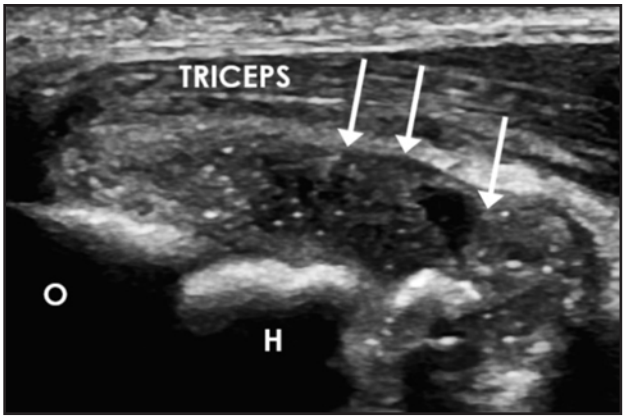

FIGURE 19. *Complex joint effusion. US with complex posterior joint effusion and internal hyperechoic foci representing urate crystals (arrows) in a patient with gout.*

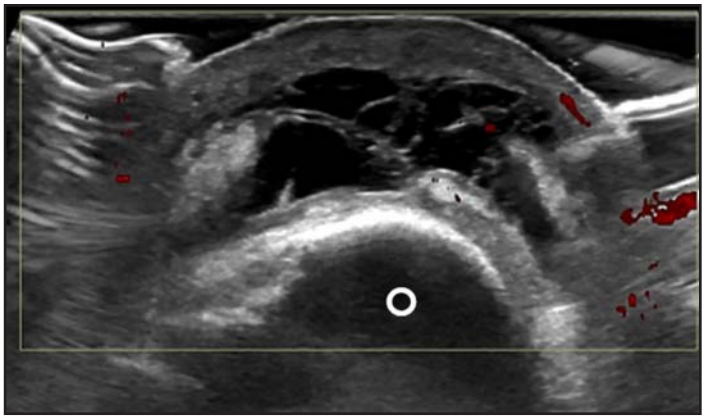

FIGURE 20. *Olecranon bursitis. Distended olecranon bursa with complex fluid, seen in short axis, without hyperemia during power Doppler interrogation. (O = olecranon)*

size. A maximal cross-sectional diameter of the ulnar nerve > 9 mm sq, or a change in caliber > 2-3 mm sq proximal to or within the cubital tunnel, suggests pathology.[8]

Dynamic evaluation may reveal the ulnar nerve dislocating over the medial epicondyle during elbow flexion, with relocation in extension. While this transient dislocation may be seen with ulnar nerve irritation/injury or injury to the overlying Osborn's ligament, up to 20% of the asymptomatic population will demonstrate this variation.[8]

In contrast, dynamic imaging may also demonstrate dislocation of the medial head of the triceps tendon and the ulnar nerve over the cubital tunnel and medial epicondyle with flexion. This phenomenon is referred to as snapping triceps syndrome and is considered a pathologic entity.[7]

MRI can also be used to evaluate the ulnar nerve as it courses through the cubital tunnel.[1] The benefit of US assessment includes superior resolution and magnification of the nerve, as well as the ability to perform a dynamic examination.

Posterior Compartment

Structures of importance in the posterior elbow include the triceps tendon, olecranon bursa and the posterior joint recess.[4,5] The triceps tendon appears as a short, broad, echogenic fibrillar structure inserting on the olecranon (**Figure 17**).[1]

Pay close attention to probe pressure over the superficial olecranon bursa, as increased pressure may shift small bursal effusions out of view.[4,5]

Triceps Tendon Injury

Injury to the triceps tendon or muscle is relatively uncommon and may be post-traumatic, spontaneous, or degenerative. When it is sports related, weight lifters, bowlers, baseball pitchers, and football players are most often affected with post-traumatic injuries.[7,8] Spontaneous injury to the triceps tendon can be

seen in patients with systemic illnesses, such as lupus, chronic renal failure with secondary hyperparathyroidism, rheumatoid arthritis, and other conditions for which steroid therapy is utilized.[4,5]

Tears of the distal triceps tendon (DTT) may be full or partial thickness and often involve the combined lateral and long heads. Most tears are incomplete with the short muscular medial head attachment remaining intact.[8] Complete tendon disruption and a variable degree of tendon retraction can be seen following a full-thickness tear, with the tendon itself appearing lax and heterogenous (**Figure 18**). In the setting of radial head fracture, be careful to evaluate for DTT injury, as they occur with similar injury mechanisms.[7,8]

Olecranon Bursitis and Joint Pathology

Rheumatoid arthritis, gout, infection, and hemorrhage, whether spontaneous or post-traumatic, are potential etiologies of bursal or joint distention with complex-appearing fluid. In patients with gout, evaluation may reveal hyperechoic synovial hypertrophy with internal hyperechoic foci/crystals (**Figure 19**). Synovial hypertrophy will demonstrate increased color or power Doppler flow, while lack of internal flow on color Doppler suggests complex fluid (**Figure 20**).[8]

Injection and Aspiration

In addition to its diagnostic capabilities, US is an ideal modality for image-guided intervention in and around the elbow joint. In the setting of osteoarthritis, inflammatory or crystalline arthropathy, US can guide joint aspiration and steroid injection. When an infectious etiology is suspected, US-guided joint aspiration can confirm diagnosis, allowing for timely treatment.

Dry needling, or repeated lancing of an abnormal area of tendon to incite internal hemorrhage and elicit the consequent inflammatory response, is felt to promote healing and granulation tissue formation. Peritendinous steroid injection may also be performed with US guidance, taking care to not inject steroids into the tendon itself; intratendinous steroid injection increases the likelihood of post-procedure tendon rupture and should be avoided.[12]

The olecranon bursa is also amenable to injection and/or aspiration when distended with fluid or thickened synovial tissue. Steroid injection should not be performed if septic bursitis is suspected.[12]

Conclusion

In summary, US is a useful tool in the diagnostic evaluation and treatment of the elbow joint and related pathologies. US is particularly beneficial in evaluating the superficial structures of the elbow including the tendons, muscles and ligaments. The dynamic capabilities of US allow for additional evaluation of the structural integrity of the ulnar collateral ligament, ulnar nerve and triceps tendon. During image-guided intervention, US allows for patient comfort adaptations in addition to providing exceptional anatomic visualization.

MRI examination of the elbow allows for exquisite visualization of the deeper intra-articular structures including the cartilage and bone marrow, as well as the tendons, muscles, and ligaments. However, a benefit of US includes its ability to obtain dynamic imaging of the joint. These principles should be considered when choosing the optimal imaging modality for diagnostic purposes, as well as intervention of the elbow and related pathologies.

References

1. Pope T, Beltran J, Bloem HL, et al. 10. In: Musculoskeletal Imaging. 1st Ed. Philadelphia, PA: Elsevier Health Sciences, 2015:134-147.
2. Pope T, Beltran J, Bloem HL, et al. 10. In: Musculoskeletal Imaging. 1st ed. Philadelphia, PA: Elsevier Health Sciences, 2015:148-156.
3, Manaster BJ, Miller TT. Elbow Overview. RADPrimer. https://app.radprimer.com/document/d724eeff-a489-4f47-a8e5-9271da9e9b90/lesson/7a444fbb-2bdb-4c84-ac85-a47f80132470. Accessed March 2019.
4. Beggs I, Bianchi S, Bueno A. Elbow. In: Musculoskeletal Ultrasound Technical Guidelines. Vienna, Austria: European Society of MusculoSkeletal Radiology.
5. Martinoli C. Musculoskeletal ultrasound: technical guidelines. Insights Imag 2010;1(3):99-141.
6. Dirim B, Brouha SS, Pretterklieber ML, et al. Terminal bifurcation of the biceps brachii muscle and tendon: anatomic considerations and clinical implications. Am J Roentgenol 2008;191(6):W248-255.
7. Pope T, Beltran J, Bloem HL, et al. In: Musculoskeletal Imaging. 2nd ed. Philadelphia, PA: Elsevier Health Sciences, 2015:157-168.
8. Jacobson JA. Fundamentals of Musculoskeletal Ultrasound. 3rd Ed. Philadelphia, PA: Elsevier; 2018;127-167.
9. Karbach LE, Elfar J. Elbow Instability: Anatomy, Biomechanics, Diagnostic Maneuvers, and Testing. J Hand Surg Am 2017;42(2): 118-126.
10. Maffulli N, Regine R, Carrillo F, Capasso G, Minelli S. Tennis elbow: an ultrasonographic study in tennis players. Br J Sports Med 1990;24(3): 151-154.
11. Husarik DB, Saupe N. Pfirrmann CW, Jost B, Hodler J, Zanetti M. Ligaments and plicae of the elbow: normal MR imaging variability in 60 asymptomatic subjects. Radiology 2010;257(1): 185-194.
12. Allen GM, Wilson DJ. Ultrasound guided musculoskeletal injections. Philadelphia, PA: Elsevier, 2018;85-112.