Neck Infections: What the Radiologist Needs to Know

Roberto Kutcher-Diaz, M.D., David Radcliffe, M.D., Hao Lo, M.D., Hemang Kotecha, D.O., Gabriela Santos-Nunez, M.D.

Department of Radiology, UMass Memorial Medical Center, Worcester, MA

Neck infections represent common clinical emergencies. While diagnosis and treatments are often merely clinical, approximately 10% to 20% of deep neck infection complications are potentially life threatening.[1] Common etiologies for head and neck infection include pharyngitis, mastoiditis, and odontogenic infections. Localization and patterns of spread, especially involving the deep cervical spaces, can be challenging for the treating clinician. Clinical manifestations vary based on the age of presentation and infection site. CT of the neck is the first line of imaging in the acute setting.[2] Although anatomy of the head and neck is challenging, knowledge of common imaging patterns and complications is critical for prompt and accurate diagnosis, which will minimize adverse outcomes.[1]

Cervical Fascia

While there is considerable variation in the description of the cervical fascial layers, a commonly utilized classification system is based on topographic morphology and distinguishes between the superficial and deep fascia, with the deep fascia being further classified into the superficial, middle, and deep layers. The superficial fascia is of limited clinical importance to radiologists as it is a connective layer interposed between the skin and deep fascia. By comparison, the deep fascia is significant to radiologists as understanding fascial boundaries allows for easier detection of disease, more refined differential diagnoses, anticipated routes of disease spread and subsequent complications.[3,4]

The first layer of the deep cervical fascia, the superficial layer, is also known as the investing layer. The superficial layer of the deep cervical fascia (SLDCF) encircles the neck with attachment to the spinous processes and ligamentum nuchae posteriorly; hyoid bone anteriorly; the mandible, temporal, and occipital bones superiorly; and the manubrium, clavicles, and scapulae inferiorly. Through its course, the external layer encompasses the stylohyoid and digastric muscles at the level of the suprahyoid neck; the parotid glands superiorly; the sternocleidomastoid muscles anteriorly; and the trapezius muscles posteriorly. The SLDCF is also continuous with the pectoralis major fascia as well as the trapezius and latissimus dorsi fascia.[3,4]

The middle layer, also known as the pretracheal layer, can be further broken down into the muscular and visceral divisions. The muscular division encircles the infrahyoid, geniohyoid, and mylohyoid muscles with superior attachment to the hyoid and thyroid cartilage and inferior continuity with the clavipectoral fascia. The visceral division of the pretracheal layer encircles the thyroid, parathyroid glands, trachea, and esophagus. The posterior aspect of the visceral division, also named the buccopharyngeal fascia, extends from the skull base to the thoracic cavity where it attaches to the pericardium. This layer is of particular clinical significance given that the retropharyngeal spaces lies directly posterior to the buccopharyngeal fascia.[3,4]

The deep layer of the deep cervical fascia (DLDCF), also known as the prevertebral fascia, attaches to the ligamentum nuchae posteriorly, encircles the paraspinal musculature, attaches to the transverse processes, encircles the prevertebral musculature, and extends anteriorly where it lies immediately posterior to the buccopharyngeal fascia. Superiorly, the DLDCF attaches to the skull base. Inferiorly, DLDCF is contiguous with the anterior longitudinal ligament, contributes to the transversalis fascia, axillary sheath, and Sibson's fascia. Of note, the carotid sheath is considered by some to be included as a portion of the deep fascia, while other sources

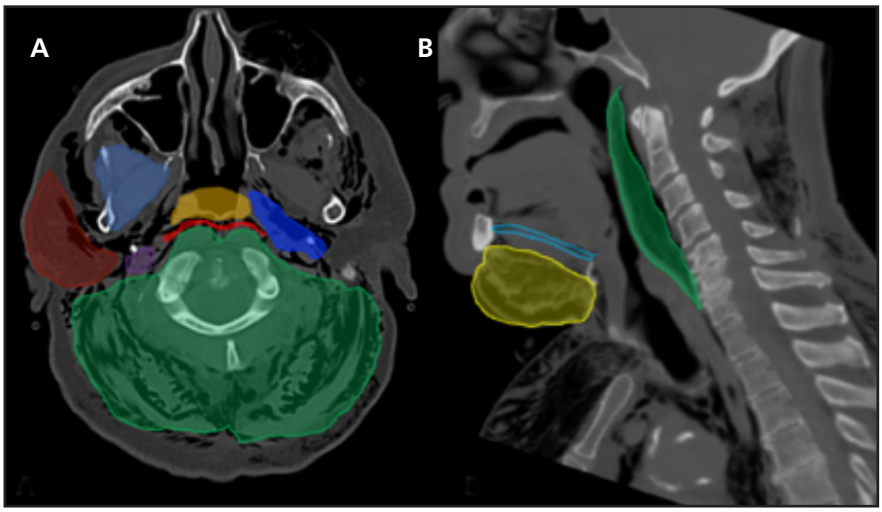

FIGURE 1. *Axial (A) and sagittal (B) CT images in a patient with subcutaneous emphysema delineating the anatomical compartments of the neck. In (A), purple color encircles poststyloid (retrostyloid) parapharyngeal space. Navy blue denotes the parapharyngeal space. Red delineates the retropharyngeal space. Mustard yellow encloses the pharyngeal mucosal space. Light blue outlines the masticator space. Green denotes the posterior cervical compartment, including the prevertebral space. Maroon demonstrates the parotid space. In (B), yellow encircles the submandibular space. Light blue outlines the sublingual space. Green denotes the prevertebral space*

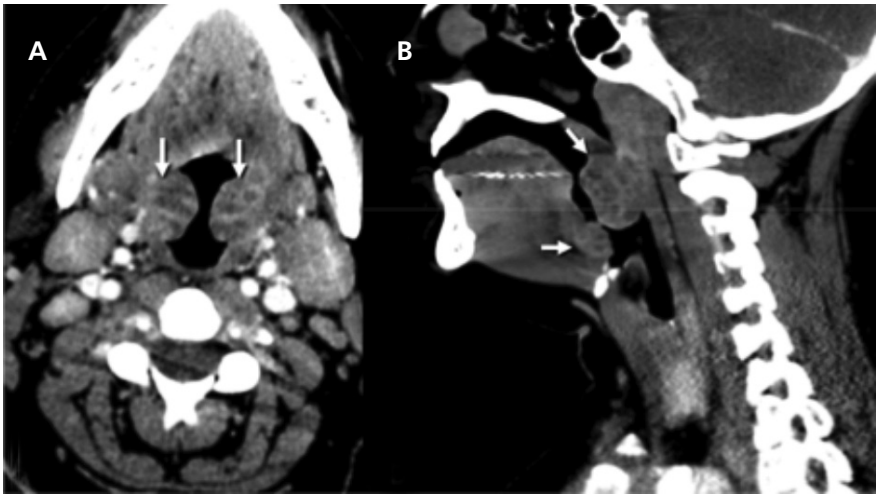

FIGURE 2. *Tonsillitis. Axial (A) and coronal (B) contrast-enhanced CT images of the neck at the level of the oropharynx. Striated-appearing palatine tonsils (arrows in A) and lingual tonsils (arrows in B) are typical of streptococcal infection.*

consider it a separate entity composed of portions of the external, middle, and deep fascial layers.[3,4]

Parapharyngeal Space

The parapharyngeal space (PPS) is a paired region extending from the skull base to the hyoid bone. From its anterior edge at the pterygomandibular raphe, the lateral border demarcated by SLDCF extends dorsally medial to the masticator space and deep portion of the parotid gland. The posterior margins are defined by the deep layer of the deep cervical fascia DLDCF at the dorsal aspect of the carotid sheath. Several fascial layers within the space define up to three compartments with varying degrees of communication. These compartments are grouped by some authors as prestyloid and poststyloid parapharyngeal spaces, which others term the *parapharyngeal space* and *carotid space*, respectively. The former contains fat and minor salivary glands, while the latter contains the internal carotid artery (ICA), internal jugular vein, and cranial nerves IX-XII. In the suprahyoid neck, as opposed to infrahyoid, most authors consider the carotid sheath to be an incomplete structure. At the level of the angle of the mandible and ICA, the carotid space is invested by the same fascial layers as the parapharyngeal space, thus becoming a posterior (retrostyloid) compartment of the latter (**Figure 1**).[5]

Parapharyngeal Infections

PPS is largely constituted by fat; therefore, pathology arising from the space is relatively uncommon. Its importance relies on multiple anatomic relationships. The PPS serves to corroborate where pathology originates. Adjacent lesions will shift the PPS in different directions.[6] PPS infections typically occur via the palatine tonsil or by spreading from odontogenic, paranasal sinuses, and parotid gland infections.[2] The lymphatic drainage of these structures leads to lymph nodes in the retropharyngeal and PPS.[7]

Pharyngeal Mucosal Space and Peritonsillar Space

Pharyngeal mucosal space contains both mucosal and lymphoid tissue. The peritonsillar space is a continuation of the pharyngeal mucosal space, which is divided into nasopharyngeal, oropharyngeal, and hypopharyngeal segments. It is bordered by the deep cervical fascia middle layer along the lateral and posterior margins. It is not, however, a true enclosed fascial space because no fascia is present along the airway surface. The retropharyngeal space is located directly posterior, while the parapharyngeal space lies laterally. The intrinsic contents include pharyngeal mucosa, lymphatic ring (adenoids, palatine tonsils, lingual tonsils), minor salivary glands, torus tubarius (pharyngeal end of the eustachian tube), and pharyngeal musculature (superior and middle constrictor, salpingopharyngeus, levator palatini).[6,8]

Pharyngeal Mucosal Infections

Many aerodigestive tract infections start in the pharyngeal mucosal space. Infections in this space can demonstrate

FIGURE 3. *Peritonsillar abscess. Axial contrast-enhanced CT of the neck shows an ill-defined region of necrosis centered in the left peritonsillar region (arrows). Local mass effect results in narrowing of oropharyngeal airway.*

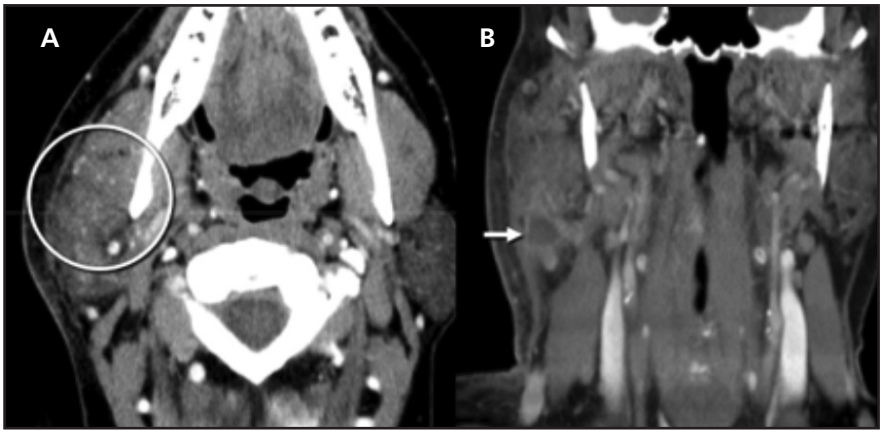

FIGURE 4. *Sialadenitis. Axial image (A) from contrast-enhanced neck CT demonstrates an enlarged enhancing right parotid gland (circle) with surrounding fat stranding and thickening of the platysma. An intraglandular rim-enhancing collection in the lower pole of the superficial lobe (arrow in B) indicates an abscess.*

FIGURE 5. *Calculus sialadenitis. Axial contrast-enhanced CT neck at the level of the right submandibular space demonstrates a sialolith (arrow) in a dilated right submandibular duct. The submandibular gland (arrowhead) is enlarged and enhancing.*

a wide array of signs and symptoms including pharyngitis, tonsillitis, suppuration, and tonsillar abscess.[1] In general, these are polymicrobial infections with diverse aerobic and anaerobic flora. Nonetheless, *Fusobacterium necrophorum* and Streptococcus group A are among the most prevalent pathogens.[9] Tonsillitis is a clinical diagnosis, but as inflammation progresses, suppuration and phlegmon can develop. Imaging findings consist of diffusely enlarged tonsils, abscess formation, and peritonsillar inflammation (**Figure 2**). Tonsillar abscess typically originates between the tonsillar capsule and pillar (**Figure 3**). Distinction between phlegmon and abscess is important as it will dictate clinical management. If an abscess is present, aspiration is the standard of care.[10]

Submandibular/Sublingual Space

The submandibular space corresponds to the compartment at the floor of the mouth (**Figure 1**). Contiguous across the midline ventrally, it is outlined anteriorly by the arch of the mandible and posteriorly by the submandibular glands. Its superior margin, the mucosa of the floor of the mouth, can be appreciated on physical examination. Caudally it is bounded by insertion of the SLDCF into the hyoid bone. The space is subdivided into two compartments by the mylohyoid muscle: the sublingual (superiorly) and submandibular (inferiorly). The sublingual compartment contains the sublingual glands, the duct and deep portion of the submandibular gland, the lingual vessels, and the glossal/hypoglossal nerves. The submaxillary space contains the superficial portion of the submandibular gland. The compartments communicate at the posterior margin of the mylohyoid, which accounts for the "diving" appearance of a ruptured ranula. In 77% of cases, the compartments may communicate through a defect in the mylohyoid muscle (a boutonniere), which may present as a palpable lump of a herniated sublingual gland.[5,11]

Parotid Space

The parotid space (PS) contains the parotid gland, which is bifurcated by the facial nerve into superficial and deep lobes. On routine CT or MRI, a more conspicuous anatomic landmark is the retromandibular vein, which lies just medial to the facial nerve. Another landmark is the external carotid artery, located immediately medial to the retromandibular vein. The SLDCF surrounds the parotid space (**Figure 1**). Craniocaudally, the parotid space extends from the external auditory canal/mastoid tip to the parotid tail, just below the mandibular angle. The parotid tail lies between the platysma and sternocleidomastoid muscles. The poststyloid (retrostyloid) parapharyngeal space is posteromedial to the parotid space, separated by the digastric muscle posterior belly. The parapharyngeal space lies medial to the parotid space. The contents of the parotid space include the parotid gland, facial nerve, retromandibular vein, external carotid artery branches, lymph nodes, and parotid (Stensen) ducts.[8]

A common anatomic variant is the parotid gland accessory third lobe, superficial to the masseter muscle. The parotid duct courses along the margin of the masseter muscle, entering the buccinator

FIGURE 6. Suppurative retropharyngeal lymphadenopathy. Axial contrast-enhanced CT of the neck at the level of the oropharynx demonstrates an enlarged left retropharyngeal lymph node (also known as node of Rouviere), with central necrosis (circle).

muscle at the level of the second maxillary molar. A normal duct is too small for routine identification on imaging. Intraparotid lymph nodes are routinely seen because parotid gland encapsulation occurs after nodal chain development.[6]

Salivary Gland Infections

Acute sialadenitis may be viral, bacterial or calculus induced. Patients are typically ill with acute pain exacerbated by food. Leukocytosis is usually present.[1,2] When dealing with salivary gland infections it is fundamental to consider symptom chronicity and laterality. This approach will help the interpreting radiologist distinguish between isolated and systemic pathologies and will also aid in selecting the imaging modality of choice. For example, a sialolith may be better depicted by CT than MRI. Bacterial infections are more common in adults following recent surgery with intubation and dehydration as predisposing factors (**Figure 4**). *Staphylococcus aureus* is amongst common pathogens in adults, whereas Paramyxovirus (mumps) is the most common culprit in the pediatric population, but other viruses such as adenovirus and parainfluenza are also common pathogens. When multiple lesions are within the parotid gland, HIV infection should also be considered as a possible diagnosis.[12]

Imaging will demonstrate an enlarged gland with periglandular inflammatory change. A dilated duct may be present in cases of calculus sialadenitis (**Figure 5**). Chronic sialadenitis may present with a firm and painless gland with fatty atrophy. Abscess formation constitutes a late complication with the parotid gland being the most common location. Viral sialadenitis is a systemic process, usually bilateral, and may involve more than one group of salivary glands.[2]

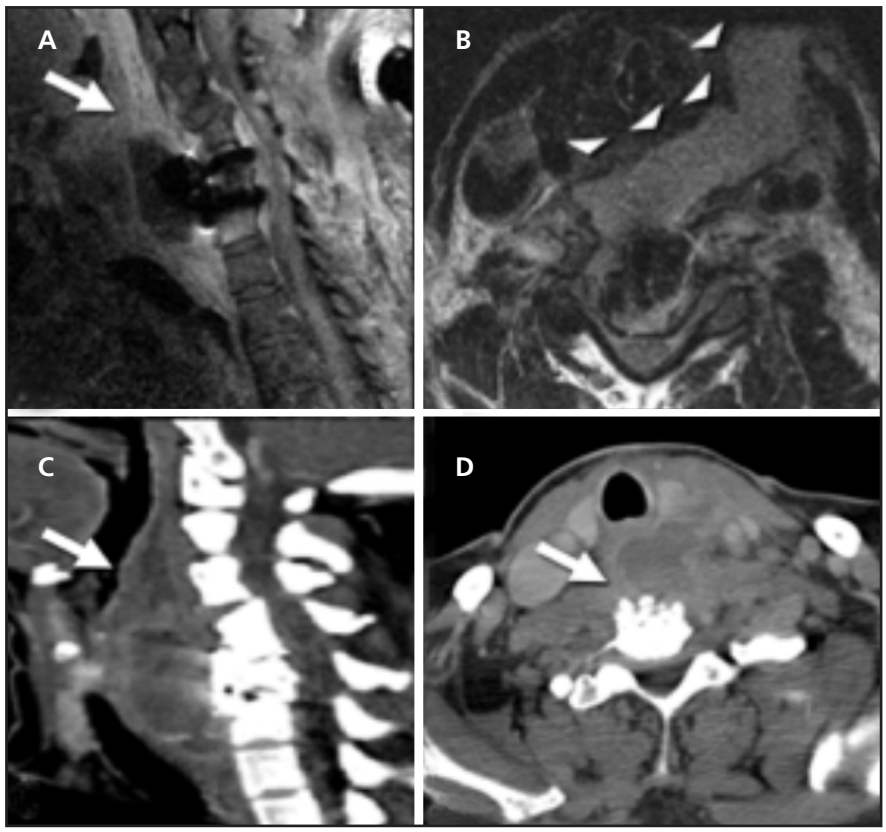

FIGURE 7. Prevertebral abscess. Sagittal T1 postcontrast (A) and axial T2-weighted (B) images of the cervical spine in a patient with anterior corpectomy/discectomy and instrumented fusion demonstrate enhancement of prevertebral soft tissues (arrows in A) and a large abscess in the surgical bed (arrowheads in B). Axial (C) and sagittal (D) CT images in the same patient also demonstrate the abscess (arrows) in the surgical bed.

Retropharyngeal (Retrovisceral) Space

The retropharyngeal or retrovisceral space (RS) spans the suprahyoid and infrahyoid neck as contiguous retropharyngeal and retroesophageal spaces (**Figure 1**). The region extends from the skull base caudally to the mediastinal fusion of the anterior buccopharyngeal and posterior alar fascia (most commonly near the level of the tracheal bifurcation). Laterally, a band of fascia known as the *cloison sagittale* separates it from the parapharyngeal space. The RS and pretracheal spaces communicate around the esophagus between the thyroid cartilage and inferior thyroidal artery.[5,12]

Retropharyngeal Infections

Retropharyngeal infections constitute a deep neck infection allowing for potentially lethal complications. The suprahyoid RS contains lymph nodes and fat, whereas the infrahyoid RS only contains fat. Infections are secondary to direct spread or from direct inoculation in the setting of penetrating trauma. Patients can present with different symptoms depending on where the process arises. Infections usually begin in the pharynx, paranasal sinuses, middle ear, or prevertebral space. Contrast-enhanced CT of the neck is usually the imaging modality of choice. Findings vary from low

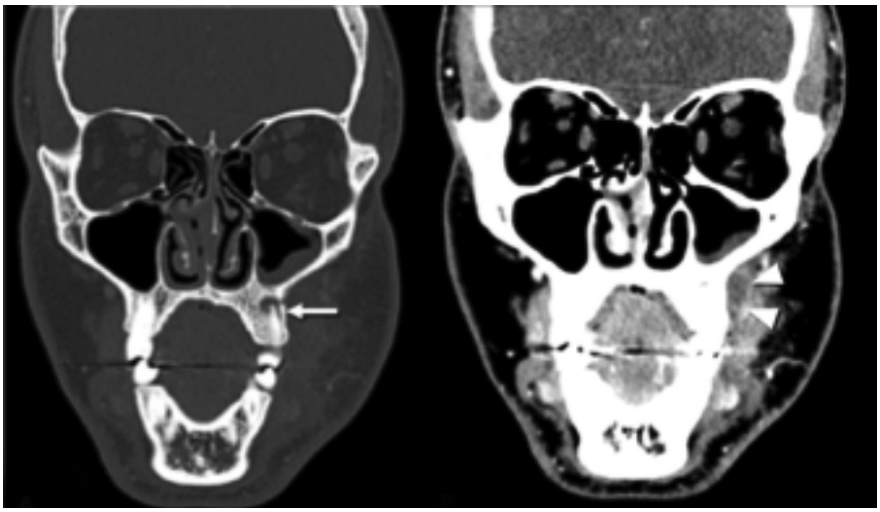

FIGURE 8. *Masticator space abscess. Contrast-enhanced coronal maxillofacial CT images in bone (A) and soft tissue (B) windows demonstrate a periapical lucency (arrow in A) surrounding a left maxillary molar tooth and dehiscence of the maxillary buccal cortex. An adjacent peripherally enhancing collection (arrowheads in B) represents a subperiosteal abscess.*

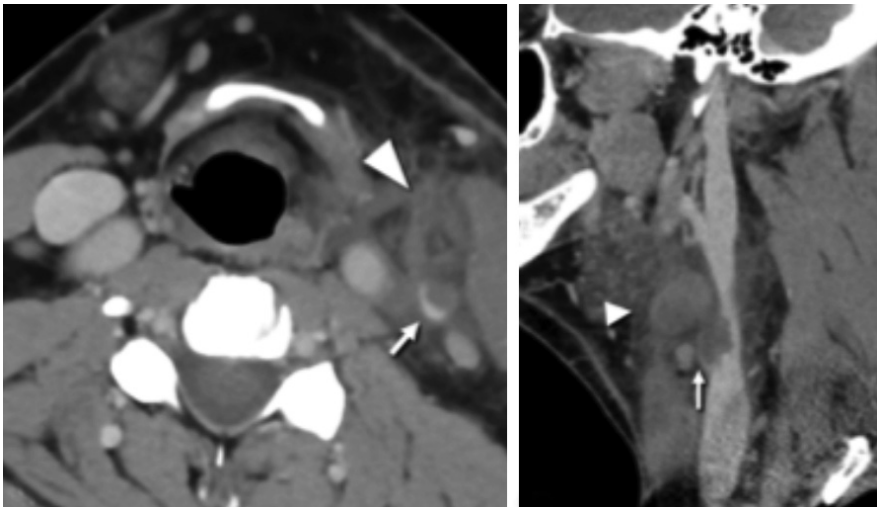

FIGURE 9. *Lemierre syndrome. Axial (A) and sagittal (B) contrast-enhanced CT of the neck demonstrates a nonocclusive filling defect within the left internal jugular vein (arrows) with surrounding fat stranding. Level III cervical lymphadenopathy (arrowhead) is also present anterior to the internal jugular vein.*

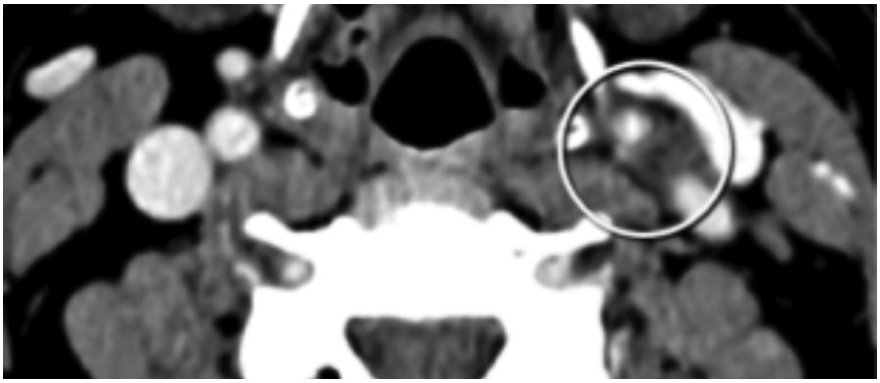

FIGURE 10. *Carotidynia. Axial image from contrast-enhanced CT angiogram of the neck at the carotid bifurcation shows circumferential soft-tissue thickening encasing and narrowing the left carotid bulb (circle).*

attenuation effusion of the RS to phlegmon and abscess formation. Impaired lymphoid drainage or excess lymphoid production will lead to local edema and nodal enlargement. Suppurative nodes and retropharyngeal abscess are at times used interchangeably. However, distinction between the two is important because it will dictate clinical management. Suppurative nodes consist of enlarged nodes with internal necrosis, with pus formation contained within the thick enhancing node capsule (**Figure 6**).[13,14] A retropharyngeal abscess usually manifests as a low attenuation fluid collection that will result in anterior displacement of the of the posterior pharyngeal wall from the prevertebral muscles. Retropharyngeal abscess does not typically exhibit a thick enhancing wall.[15]

Posterior Cervical Space

The posterior cervical space corresponds to the posterior triangle of the neck outlined by the sternocleidomastoid anteriorly and the trapezius posteriorly. The medial fascial boundary is demarcated by the DLDCF as it curves around the paraspinal muscles of the prevertebral space from the spinous processes/nuchal ligaments posteriorly, to the transverse processes of the cervical vertebra anteriorly (**Figure 1**). Although separate from this compartment, the posterior triangle also encompasses a space containing the spinal accessory nerve and its lymph node chain. Lymphadenopathy in this chain will result in a characteristic anterior displacement of the carotid sheath, which lies ventrally.

Pre- and Perivertebral Infections

The bulk of the pre- and perivertebral space (PVS) is comprised of muscles and osseous structures. Infection is common and usually occurs from direct inoculation after trauma or surgery, direct extension, or hematogenous spread. Predisposing risk factors include intravenous drug use and immunocompromised status. Symptoms vary, including neck pain, focal tenderness, and myelopathy if epidural involvement is present. *Staphylococcus aureus* is one

of the most commonly isolated pathogens. Contrast-enhanced CT and MRI are complementary when evaluating the PVS. Imaging findings include pre- or perivertebral fluid, myositis, endplate destruction (discitis/osteomyelitis and presence of hardware construct). Edema in this space will displace the longus capiti muscles, a helpful clue that will differentiate from a process arising in the RS (**Figure 7**). The DLDCF confines the infection so that it preferentially extends into the epidural space.[16,17] Nodal involvement is common.[14]

Masticator Space

The masticator space (MS) consists of paired spaces on each side of the face and is bounded by the SLDCF. The SLDCF splits in two layers at the lower border of the mandible. The superficial layer encloses the masseter muscle extending over the zygomatic arch and attaches to the lateral orbital wall. The deep layer extends medial to the medial pterygoid muscle and attaches to the skull base medial to the foramen ovale. These two layers fuse along the borders of the mandibular ramus.[5,15] The MS comprises masticator muscles (pterygoid, masseter and temporalis) and the posterior mandibular ramus.[19]

Masticator Infections

Clinical evaluation of the masticator space is limited. Patients may complain of trismus mimicking temporomandibular joint disease. Most MS infections are the result of direct spread of advanced odontogenic infections (**Figure 8**). Several pathways of spread had been proposed, which include a cortical break along the buccal aspect of the maxillary bone with propagation along the medial pterygoid muscle fibers. Secondary extension is directed superiorly along interlaced muscle fibers and vertical orientation of the cervical fascia.[20] Imaging findings include edema and muscle stranding with occasionally phlegmon/abscess formation, classically situated adjacent to the mandibular ramus.[2]

Unique Entities

Lemierre Syndrome

Acute oropharyngeal infection can cause septic thrombophlebitis of the internal jugular vein. This process is almost exclusively caused by *Fusobacterium necrophorum*. Infection occurs after lateral spread from the lateral pharyngeal space. Neck swelling and tenderness are the hallmark symptoms (**Figure 9**). Pulmonary nodules are also found as the venous system serves as a route of metastatic spread. Contrast-enhanced CT of the neck is the modality of choice and will demonstrate thrombosis of the internal jugular vein and thrombophlebitis.[2]

Carotidynia or Fay Syndrome

This is a poorly understood syndrome manifested by unilateral neck pain and increased pulsation in the affected side.[21] Imaging findings consist of amorphous soft tissue or stranding replacing the fat surrounding the carotid artery without luminal narrowing. Patients usually complain of neck pain with tenderness to palpation over the carotid bifurcation (**Figure 10**).[22]

Summary

Imaging plays an important role in the evaluation of neck infections and CT and/or MR imaging is commonly obtained in the emergency department. Clinical presentations vary based upon the neck compartment in which each entity arises. Knowledge of the imaging patterns and potential complications of various infectious processes will allow the radiologist to provide an accurate and prompt diagnosis, evaluate for potential complications, and ensure optimal treatment.

References

1. Kubal WS. Face and neck infections: what the emergency radiologist needs to know. Radiol Clin North Am 2015;53(4):827-846. doi:10.1016/j.rcl.2015.02.007
2. Maroldi R, Farina D, Ravanelli M, Lombardi D, Nicolai P. Emergency imaging assessment of deep neck space infections. Semin Ultrasound CT and MRI 2012;33(5):432-442. doi:10.1053/j.sult.2012.06.008
3. King KM. Head and neck imaging. 3rd ed, 2 vols. Radiology 1997;204(1):220-220. doi:10.1148/radiology.204.1.220
4. Sutcliffe P, Lasrado S. Anatomy, head and neck, deep cervical neck facia. In: StatPearls. StatPearls Publishing; 2019. http://www.ncbi.nlm.nih.gov/books/NBK541091/. Accessed December 6, 2019.
5. Guidera AK, Dawes PJD, Fong A, Stringer MD. Head and neck fascia and compartments: no space for spaces. Head Neck 2014;36(7):1058-1068. doi:10.1002/hed.23442
6. Gamss C, Gupta A, Chazen JL, Phillips CD. Imaging evaluation of the suprahyoid neck. Radiol Clin North Am 2015;53(1):133-144. doi:10.1016/j.rcl.2014.09.009
7. Weber AL, Siciliano A. CT and MR imaging evaluation of neck infections with clinical correlations. Radiol Clin North Am 2000;38(5):941-968. doi:10.1016/S0033-8389(05)70214-1
8. Rubin JA, Wesolowski JR. Neck MR imaging anatomy. Magn Reson Imaging Clin N Am 2011;19(3):457-473, vii. doi:10.1016/j.mric.2011.05.003
9. Klug TE, Henriksen J-J, Fuursted K, Ovesen T. Significant pathogens in peritonsillar abscesses. Eur J Clin Microbiol Infect Dis 2011;30(5):619-627. doi:10.1007/s10096-010-1130-9
10. Ludwig BJ, Foster BR, Saito N, Nadgir RN, Castro-Aragon I, Sakai O. Diagnostic imaging in nontraumatic pediatric head and neck emergencies. RadioGraphics 2010;30(3):781-799. doi:10.1148/rg.303095156
11. La'Porte SJ, Juttla JK, Lingam RK. Imaging the floor of the mouth and the sublingual space. RadioGraphics. 2011;31(5):1215-1230. doi:10.1148/rg.315105062
12. Parker GD, Harnsberger HR. Radiologic evaluation of the normal and diseased posterior cervical space. Am J Roentgenol 1991;157(1):161-165. doi:10.2214/ajr.157.1.2048512
13. Shefelbine SE, Mancuso AA, Gajewski BJ, Ojiri H, Stringer S, Sedwick JD. Pediatric retropharyngeal lymphadenitis: differentiation from retropharyngeal abscess and treatment implications. Otolaryngol Head Neck Surg 2007;136(2):182-188. doi:10.1016/j.otohns.2006.03.002
14. Hoang JK, Branstetter BF, Eastwood JD, Glastonbury CM. Multiplanar CT and MRI of collections in the retropharyngeal space: is it an abscess? Am J Roentgenol 2011;196(4):W426-432. doi:10.2214/AJR.10.5116
15. Bou-Assaly W, Mckellop J, Mukherji S. Computed tomography imaging of acute neck inflammatory processes. World J Radiol 2010;2(3):91-96. doi:10.4329/wjr.v2.i3.91
16. Mills MK, Shah LM. Imaging of the perivertebral space. Radiol Clin North Am 2015;53(1):163-180. doi:10.1016/j.rcl.2014.09.008
17. Capps EF, Kinsella JJ, Gupta M, Bhatki AM, Opatowsky MJ. Emergency imaging assessment of acute, nontraumatic conditions of the head and neck. RadioGraphics 2010;30(5):1335-1352. doi:10.1148/rg.305105040
18. Wei Y, Xiao J, Zou L. Masticator space: CT and MRI of secondary tumor spread. Am J Roentgenol 2007;189(2):488-497.
19. Fernandes T, Lobo JC, Castro R, Oliveira MI, Som PM. Anatomy and pathology of the masticator space. Insights Imaging 2013;4(5):605-616. doi:10.1007/s13244-013-0266-4
20. Schuknecht B, Stergiou G, Graetz K. Masticator space abscess derived from odontogenic infection: imaging manifestation and pathways of extension depicted by CT and MR in 30 patients. Eur Radiol 2008;18(9):1972-1979. doi:10.1007/s00330-008-0946-5
21. Santarosa C, Stefanelli S, Sztajzel R, Mundada P, Becker M. Carotidynia: a rare diagnosis for unilateral neck pain revealed by cross-sectional imaging. Case Rep Radiol 2017;2017. doi:10.1155/2017/7086854
22. Lecler A, Obadia M, Savatovsky J, et al. TIPIC Syndrome: beyond the myth of carotidynia, a new distinct unclassified entity. Am J Neuroradiol 2017;38(7):1391-1398. doi:10.3174/ajnr.A5214